

Carvacrol Ameliorates Cisplatin-Induced Cardiotoxicity By Regulating Notch/Hes1 Signaling Pathway, Oxidative Stress and Cell Death In Rat Cardiac Tissue

Nurhan AKARAS^{1*} , Özge KANDEMİR² , Hasan ŞİMŞEK³ 

¹ Aksaray University, Faculty of Medicine, Department of Histology and Embryology, Aksaray, Türkiye

² Aksaray University, Vocational School of Technical Sciences, Department of Food Processing, Aksaray, Türkiye

³ Aksaray University, Faculty of Medicine, Department of Physiology, Aksaray, Türkiye

Nurhan AKARAS ORCID No: 0000-0002-8457-9448

Özge KANDEMİR ORCID No: 0000-0001-8884-4168

Hasan ŞİMŞEK ORCID No: 0000-0001-5573-4923

*Corresponding author: nurhanakaras@aksaray.edu.tr

(Received: 09.10.2024, Accepted: 08.11.2024, Online Publication: 30.12.2024)

Keywords
Cisplatin,
Carvacrol,
Cardiac Tissue,
Oxidative Stress,
Apoptosis,
Rat

Abstract: Cisplatin is one of the most active cytotoxic agents used mainly in the treatment of solid tumors. High doses and long-term use of Cisplatin are known to cause cardiotoxicity. In recent years, the antiapoptotic and antioxidant effects of Carvacrol in cardiovascular diseases have attracted attention. In this study, the effects of Carvacrol on Cisplatin-induced cardiotoxicity in a rat model were investigated using biochemical and histological methods. Twenty-eight rats were divided into 4 groups: 1. Control group, 2. Carvacrol group, 3. Cisplatin group, 4. Cisplatin + Carvacrol group. The expression of antioxidant enzymes, proinflammatory cytokines, apoptotic, and autophagic proteins was examined in heart tissue obtained from rats sacrificed after the last drug administration. Additionally, heart tissue was evaluated histopathologically. Cisplatin has been observed to cause oxidative stress and inflammatory damage in animal heart tissue. Carvacrol administration significantly increased antioxidant enzyme (superoxide dismutase and glutathione peroxidase) activities while suppressing inflammatory markers (NF- κ B, TNF- α , IL-1 β). Additionally, Cisplatin induced apoptotic (caspase-3, Bax, Bcl-2) and autophagic (Beclin-1, LC3A, LC3B) markers. It has been determined that carvacrol can protect heart tissues from the destructive effects of cisplatin by exerting anti-apoptotic and anti-autophagic effects. The expression levels of Notch1 and Hes1, which were decreased by cisplatin administration, were upregulated after administration of Carvacrol. H&E staining results showed that Carvacrol preserved myocardial tissue integrity. In conclusion, Carvacrol showed a cardioprotective effect against cisplatin-induced cardiotoxicity.

Karvakrol Sıçan Kalp Dokusunda Notch/Hes1 Sinyal Yolunu, Oksidatif Stresi ve Hücre Ölümünü Düzenleyerek Sisplatin Kaynaklı Kardiyotoksiteyi İyileştirir

Anahtar Kelimeler
Sisplatin,
Kardiyak Doku,
Oksidatif Stres,
Apoptozis,
Sıçan

Öz: Sisplatin esas olarak katı tümörlerin tedavisinde kullanılan en aktif sitotoksik ajanlardan biridir. Sisplatin'in yüksek doz ve uzun süreli kullanımı kardiyotoksiteye neden olduğu bilinmektedir. Son yıllarda kardiyovasküler hastalıklarda Karvakrol'ün antiapoptotik ve antioksidan etkileri ilgi görmüştür. Bu çalışmada, bir sıçan modelinde Karvakrol'ün Sisplatin kaynaklı kardiyotoksite üzerindeki etkileri biyokimyasal ve histolojik yöntemler kullanılarak araştırılmıştır. Yirmi sekiz sıçan 4 gruba ayrıldı: 1. kontrol grubu, 2. Karvakrol grubu, 3. Sisplatin grubu, 4. Sisplatin + Karvakrol grubu. Son ilaç uygulamasından sonra öldürülen sıçanlardan elde edilen kalp dokusunda antioksidan enzimlerin, proinflamatuvar sitokinlerin, apoptotik ve otofajik proteinlerin ekspresyonu incelenmiştir. Ayrıca kalp dokusu histopatolojik olarak değerlendirilmiştir. Sisplatin'in hayvanların kalp dokusunda oksidatif strese ve inflamatuvar hasara neden olduğu gözlenmiştir. Karvakrol uygulamasının antioksidan enzim (süperoksit dismutaz ve glutatyon peroksidaz) aktivitelerini önemli ölçüde artırırken, inflamatuvar belirteçleri (NF- κ B, TNF- α , IL-1 β) baskıladı. Ayrıca Sisplatin'in apoptotik (caspase-3, Bax, Bcl-2) ve otofajik (Beclin-1, LC3A, LC3B) belirteçleri indükledi. Karvakrol'ün ise anti-apoptotik ve anti-otofajik etki

göstererek kalp dokularını Sisplatin'in yıkıcı etkisinden koruyabildiği belirlenmiştir. Sisplatin uygulaması ile azalmış Notch1 ve Hes1 ekspresyon seviyeleri Karvakrol uygulamasından sonra düzenlenmiştir. H&E boyama sonuçları Karvakrol'ün miyokardiyal doku bütünlüğünü koruduğunu göstermiştir. Sonuç olarak, Karvakrol Sisplatin kaynaklı kardiyotoksisiteye karşı kardiyoprotektif bir etki gösterdi.

1. INTRODUCTION

Cancer, which is expected to increase in the future and poses a major health risk worldwide, is a major cause of disease-related morbidity and mortality. Cancer-related morbidity is not only caused by the disease but also includes the effects of chemotherapy [1-3]. Anti-cancer drugs must be prescribed to treat the disease, and the outcome is hoped to be successful. However, this hope is soon disappointed due to the effects of harmful chemicals that cause multi-organ toxicity and disruption of DNA structure and/or function [4,5]. Cisplatin (CIS, cis-dichlorodiamine platinum II), an anticancer drug, is an inorganic platinum widely used for treating many solid cancers [6,7]. Because CIS cannot distinguish between normal and cancer cells, toxic effects that occur during its use may result in a reduction in the dose or discontinuation of treatment. CIS causes various dose-dependent acute and cumulative side effects, including nephrotoxicity, cardiotoxicity, neurotoxicity, ototoxicity, myelosuppression, and gastrointestinal toxicity [8,9]. There is evidence that CIS can cause acute or chronic cardiotoxicity in the form of electrocardiographic changes and arrhythmias (ventricular arrhythmias, supraventricular tachycardia, atrial fibrillation, atrioventricular block), myocarditis, pericarditis, acute myocardial infarction, hypertension, and coronary vasospasm [8-11]. Recent studies have suggested that oxidative stress plays a significant role in the aforementioned CIS-induced side effects [6,9].

CIS treatment stimulates oxidative stress, apoptosis, and autophagy, and these adverse effects are attributed to its side effects in the body [6,8,9]. Because the oxidant/antioxidant balance is disrupted by excessive production of reactive oxygen species (ROS), increased oxidative stress affects macromolecules, such as membrane lipids, proteins, and DNA, in body cells and thus damages cell integrity [12,13]. Despite this information, the mechanisms involved in cardiotoxicity are still not well characterized. Researchers are constantly searching for ways to prevent the side effects of CIS, increase chemotherapy effects, and reduce costs [7].

Many antioxidants and drugs have been used to completely or partially protect vital organs and cells against CIS damage. However, hope lies in the combination of herbal medicines with targeted drugs. Medicinal plants and their active ingredients are widely used to treat diseases [7,14]. Several medicinal plants have been reported to reduce the toxicity of CIS [7,15-17].

Carvacrol (CRV) is the major monoterpene phenol isomeric with thymol, and it is found in various essential oils in plant species such as *Origanum*, *Thymus*, and

Corydthymus. Essential oils containing high CRV levels have strong antioxidant properties comparable to those of ascorbic acid, butylated hydroxytoluene, and vitamin E [6,18]. CRV possesses various pharmacological properties, including antioxidant, antimicrobial, antibacterial, and antiapoptotic properties, through its inhibition of proapoptotic effects [7,19,20].

Preventing and/or reducing the side effects of cancer drugs are among the main concerns for patients who must take medications for a long time or permanently. This study describes a novel method for achieving success without exposing these treatments to new drug toxicity. Therefore, this study investigated the efficacy of CRV in improving the toxic effects by inhibiting CIS-induced oxidative damage and apoptosis in rat cardiac tissues.

2. MATERIAL AND METHOD

2.1. Chemicals and Reagents

CIS (CDDP, 25 mg/50 mL) was purchased from Koçak Farma (Istanbul, Turkey). CRV (CAS No. 499-75-2, purity: 98%) was obtained from Sigma-Aldrich Co. (St. Louis, MO, USA). Other chemicals (analytical grade) used in this study were purchased from Sigma and Merck.

2.2. Animals and Experimental Design

In this study, 28 *Wistar albino* rats, weighing 200-250 g and aged 10-12 weeks, were used. The animals were kept in cages in a controlled room with a constant temperature of 24-25°C and a twelve (12 h) hour light-dark cycle (07:00-19:00 light; 19:00-07:00 dark). Rats were fed unlimited amounts of water and standard chow. All animal experiments were performed at the KONÜDAM Experimental Medicine Application and Research Center. The procedures were approved by the local Animal Experiments Ethics Committee (Date: 25.09.2024, meeting no: 2024-080). Previous studies were used to determine the drug and active ingredient doses in this study [4,21,22].

Wistar albino rats were randomly divided into 4 groups with 7 rats in each group.

- Control group: Physiological serum was administered intraperitoneally on the first day.
- Carvacrol group: 50 mg/kg CRV was given orally for 4 days.
- Cisplatin group: On day 1, a single 7 mg/kg dose of CIS was administered intraperitoneally.
- Cisplatin + Carvacrol 50: On the first day, 7 mg/kg CIS was administered intraperitoneally as a single dose, and 50 mg/kg CRV was administered orally for 4 days.

24 hours after the last drug administration (day 5), the animals were decapitated under light sevoflurane anesthesia, and heart tissue and blood samples were collected. Blood samples were transferred to vacuum tubes without anticoagulant for biochemical analyses, centrifuged at 3000 rpm at +4 °C for 10 min, and the serum was separated and stored in a deep freezer at -20°C until biochemical analyses were performed.

2.3. Real Time PCR (RT-PCR)

The relative mRNA transcript levels of the gene regions listed in Table 1 were examined in the heart tissues of rats with CIS injury and CRV administration using qRT-PCR

technique. First, total RNA was isolated from tissues using QIAzol Lysis Reagent (79306; Qiagen). Then, cDNA synthesis was performed from these RNA samples using the OneScript Plus cDNA Synthesis Kit (ABM, G236, Richmond, Canada). The prepared cDNAs were mixed with primer sequences and BlasTaq™ 2X qPCR MasterMix (ABM, G891, Richmond, Canada) to form a reaction mixture. The mixture was run on a Rotor-Gene Q (Qiagen) instrument for specified time and temperature cycles according to the manufacturer's instructions. After completion of the cycles, gene expressions were normalized to β -Actin and evaluated using the $2^{-\Delta\Delta CT}$ method [23].

Table 1. Primer sequences

Gene	Sequences (5'-3')	Product length
Cu-Zn SOD	F: AGTCCC GCCCTTCTAAAAC R: CAATGGCCTCTGTAGCCC	387
CAT	F: ATGGCAACTGTCCTGAACT R: AGTGACACTGCCTTCCTGAA	670
GPx	F: CTCGAGTGACAAGCCCGTAG R: ATCTGCTGGTACCACCAGTT	290
NF- κ B	F: AGTCCC GCCCTTCTAAAAC R: CAATGGCCTCTGTAGCCC	106
IL-1 β	F: ATGGCAACTGTCCTGAACT R: AGTGACACTGCCTTCCTGAA	197
TNF- α	F: CTCGAGTGACAAGCCCGTAG R: ATCTGCTGGTACCACCAGTT	139
Caspase-3	F: ACTGGAATGTCAGCTCGCAA R: GCAGTAGTCGCCTCTGAAGA	270
Bax	F: TTTCATCCAGGATCGAGCAG R: AATCATCCTCTGCAGCTCCA	154
Bcl-2	F: GACTTTGCAGAGATGTCCAG R: TCAGGTACTCAGTCATCCAC	214
Beclin-1	F: TCTCGTCAAGGCGTCACTTC R: CCATTCTTTAGCCCCGACG	198
LC3A	F: GACCATGTTAACATGAGCGA R: CCTGTTCCATAGATGTCAGCG	139
LC3B	F: GAGCTTCGAACAAGAGTGG R: CGCTCATATTCACGTGATCA	152
Notch1	F: GTGGGATGGACTGGACTGTG R: GCGCAGGAAGTGGGAAGGAGTT	117
Hes1	F: CGCCGGGCAAGAATAAAATGA R: ATGTCTGCCTTCTCCAGCTT	104
β -Actin	F: CAGCCTTCCTTCTGGGTATG R: AGCTCAGTAACAGTCCGCTT	360

2.4. Histopathological Analysis

Tissue specimens were kept in 10% formalin solution for 48 h for fixative purposes. Fixed tissues were first passed through increasing grades of alcohol (70-100%) and then cleared in xylene. As the last step in the tissue tracking phase, 5 μ m thick sections were prepared from the prepared paraffin blocks using a microtome. The prepared sections were stained with hematoxylin and eosin (H&E) for general histological evaluation. Stained sections of cardiac tissues were examined under a light microscope (Olympus Cx43; Japan) and photographed.

2.5. Statistical Analysis

Statistical analysis of biochemical findings was performed using one-way ANOVA and Tukey HSD test was used to determine the relationship between the groups. Results are presented as Mean \pm Standard Error Mean. The results of histological examination were

analyzed using the nonparametric Kruskal-Wallis test and Mann-Whitney U test for comparison of paired groups. The statistical significance level was set as $p < 0.05$.

3. RESULTS

3.1. Anti-Oxidant Effect of Carvacrol on Cisplatin-Induced Oxidative Stress

The antioxidant effects of CRV on CIS-induced oxidative stress in rat heart tissue are presented in Figure 1. In the CIS alone group, there was a significant decrease in the expression of SOD, CAT, and GPx compared with the control group. In contrast, combined treatment with CIS and CRV triggered an increase in the levels of antioxidants (SOD, GPx) compared with the CIS group. These results demonstrate that CRV partially reduces the CIS effect by decreasing total antioxidant activation in rat cardiac tissue.

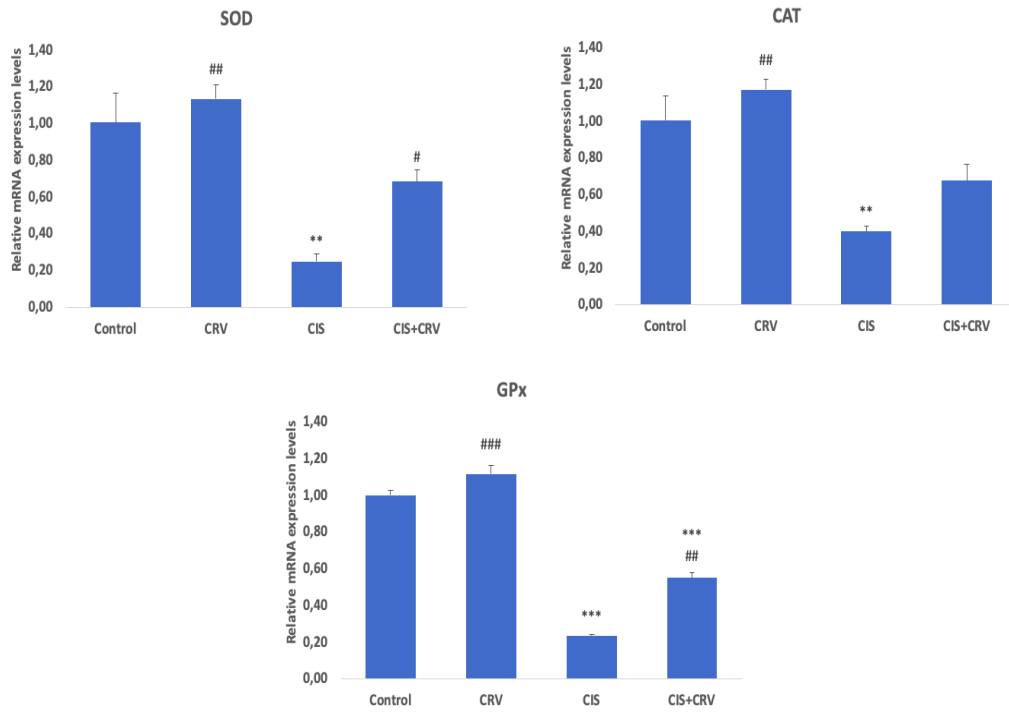


Figure 1. Effect of Carvacrol and Cisplatin treatments on SOD, CAT, GPx mRNA expression levels in heart tissue. Values are given as mean \pm SD. Control vs others: * $p < .05$, ** $p < .01$, *** $p < .001$, CIS vs others: # $p < .05$, ## $p < .01$, ### $p < .001$

3.2. Anti-Inflammatory Effect of Carvacrol on Cisplatin-Induced Inflammation

The expressions of inflammation markers in rat heart tissue are presented in Figure 2. In this study, CIS administration induced a series of inflammatory changes that mediated cardiac tissue damage. The levels of NF-

kB, TNF- α and IL-1 β , which are important markers involved in inflammation, were higher in the CIS group than in the control ($p < 0.001$). Combined treatment with CIS and CRV reduced the levels of these markers by attenuating CIS-induced inflammation. However, there was no significant difference in NF-kB, TNF- α and IL-1 β levels between the control and CRV groups.

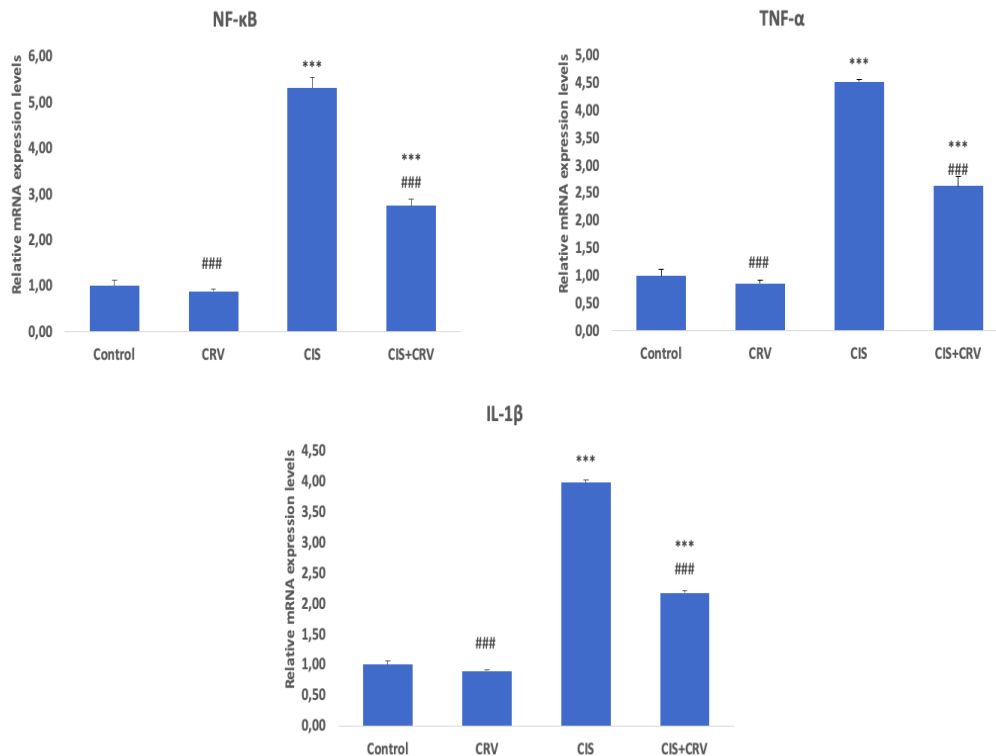


Figure 2. Effect of Carvacrol and Cisplatin treatments on NF- κ B, TNF- α , IL-1 β mRNA expression levels in heart tissue. Values are given as mean \pm SD. Control vs others: * $p < .05$, ** $p < .01$, *** $p < .001$, CIS vs others: # $p < .05$, ## $p < .01$, ### $p < .001$

3.3. Anti-Apoptotic Effect of Carvacrol on Cisplatin-Induced Apoptosis

The anti-apoptotic effect of CRV against CIS-induced apoptosis in rat cardiac tissue is presented in Figure 3. The expression levels of pro-apoptotic Bax, anti-apoptotic Bcl-2, and caspase-3 (Casp-3) proteins were examined,

and no significant differences were found between control and CRV. While there was a decrease in Bcl-2 expression in the CIS group, there was a significant increase in Bax and Casp-3 protein levels. In the CIS+CRV group, there was an increase in Bcl-2 expression and a significant decrease in Bax and Casp-3 protein expressions, unlike the group given only CIS.

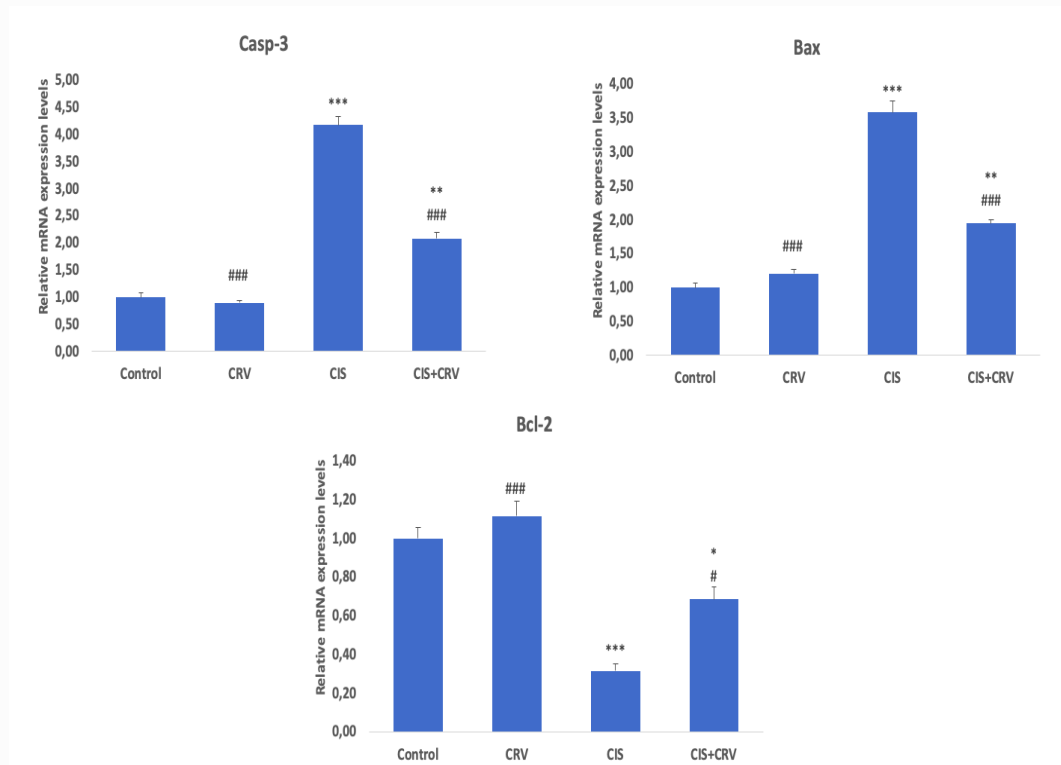


Figure 3. Effect of Carvacrol and Cisplatin treatments on Bax, Bcl-2, Casp-3 mRNA expression levels in heart tissue. Values are given as mean \pm SD. Control vs others: * $p < .05$, ** $p < .01$, *** $p < .001$, CIS vs others: # $p < .05$, ## $p < .01$, ### $p < .001$

3.4. Anti-Autophagic Effect of Carvacrol on Cisplatin-Induced Autophagy

Autophagic protein levels using the PCR method are presented in Figure 4. In the CIS group, Beclin-1, LC3A,

and LC3B expression levels increased significantly compared with the control group ($p < 0.001$). On the contrary, there was a significant decrease in autophagic parameters in the CIS+CRV group.

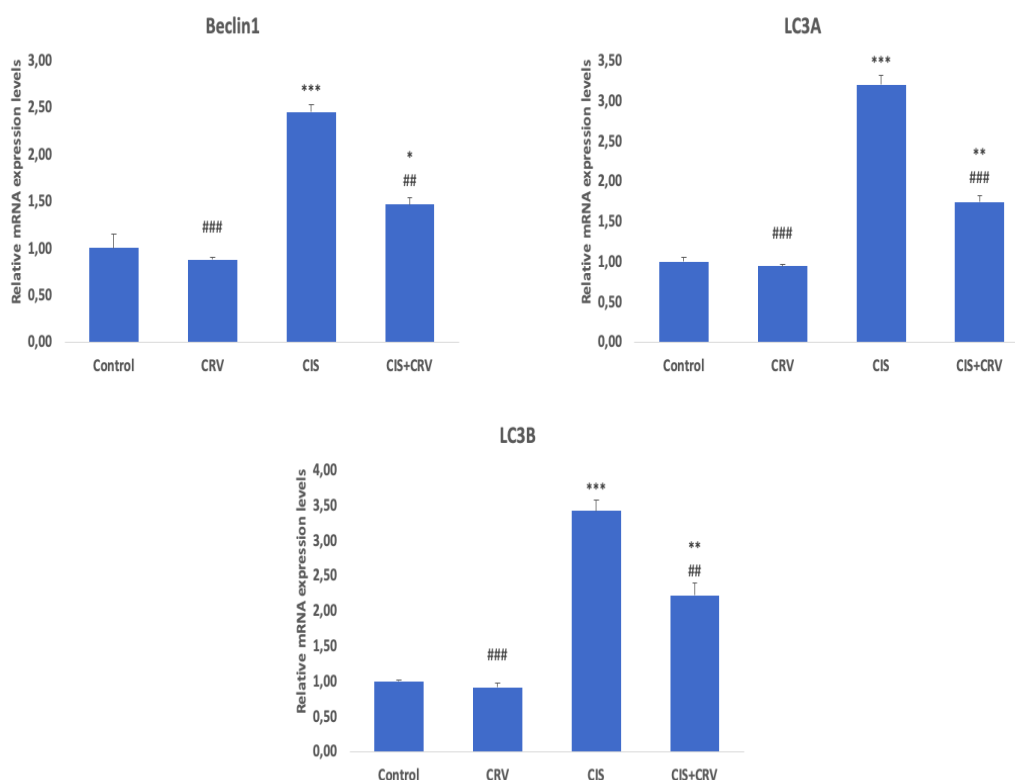


Figure 4. Effect of Carvacrol and Cisplatin treatments on Beclin-1, LC3A, LC3B mRNA expression levels in heart tissue. Values are given as mean \pm SD. Control vs others: * $p < .05$, ** $p < .01$, *** $p < .001$, CIS vs others: # $p < .05$, ## $p < .01$, ### $p < .001$

3.5. Effect of Carvacrol on Cisplatin-Induced Decreased Notch1 and Hes1 Protein Expressions

In this study, the Notch1/Hes1 pathway was examined using RT-PCR, and the results are presented in Figure 5.

The results show that CIS treatment downregulates the Notch1/Hes1 pathway. However, CRV application significantly increased Notch1 and Hes1 levels compared with the CIS group ($p < 0.05$).

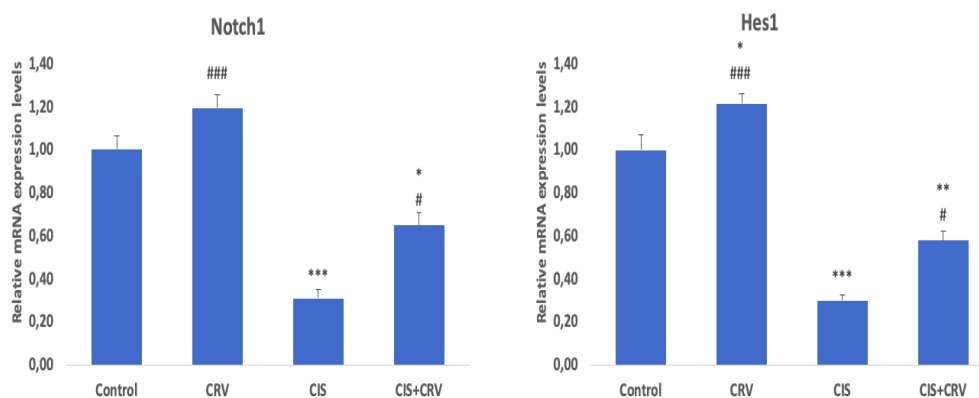


Figure 5. Effect of Carvacrol and Cisplatin treatments on Notch 1, Hes1 mRNA expression levels in heart tissue. Values are given as mean \pm SD. Control vs others: * $p < .05$, ** $p < .01$, *** $p < .001$, CIS vs others: # $p < .05$, ## $p < .01$, ### $p < .001$

3.6. Effect of Carvacrol on Cisplatin-Induced Morphological Changes

To evaluate the effects of CIS and CRV on the heart, histopathological analysis was performed using H&E staining. The results are presented in Figure 6. When the cardiac histological structure of the control group was examined, the myocardial layer was normal. The muscles in this layer were regularly arranged, the cytoplasm was slightly acidophilic, and the nucleus was single, oval, and central. There were vessels in the connective tissue

between the muscles (Figure 6A). No histopathological lesions were observed in the group that received only CRV (Figure 6B). In the CIS administration group, there were degenerative changes in the myocardial layer. Specifically, these events primarily disturbed cardiac myofibril organization and eosinophilic changes in the cytoplasm of cardiocytes. Additionally, pyknotic nuclei and vacuolization in the cytoplasm were observed. When the connective tissue was examined, there was vascular congestion, hemorrhage, and inflammatory cell infiltration consisting of lymphocytes (Figure 6C). The

combination of CIS and CRV caused mild edema in the interstitial area, decreased bleeding, and vascular congestion. Except for mild vacuolar degeneration in a few cardiocytes, almost all cardiocytes exhibited an appearance close to that of the control. The

histopathological findings show that the model was successfully established and that CVR treatment had a protective effect (Figure 6D). Histopathological results are summarized in Table 2.

Table 2. Scoring of histopathological changes

Histopathological changes	Control	CRV	CIS	CIS + CRV
Disruption of cardiac muscle architecture	-	-	+++	+
Vascular congestion	-	-	+++	+
Interstitial hemorrhage	-	-	++	+
Inflammatory cell infiltration	-	-	+++	+
Necrosis	-	-	++	+

The severity of the lesions was graded as follows: score (-) was considered normal, score (+) was considered mild, score (++) was considered moderate, and score (+++) was considered severe.

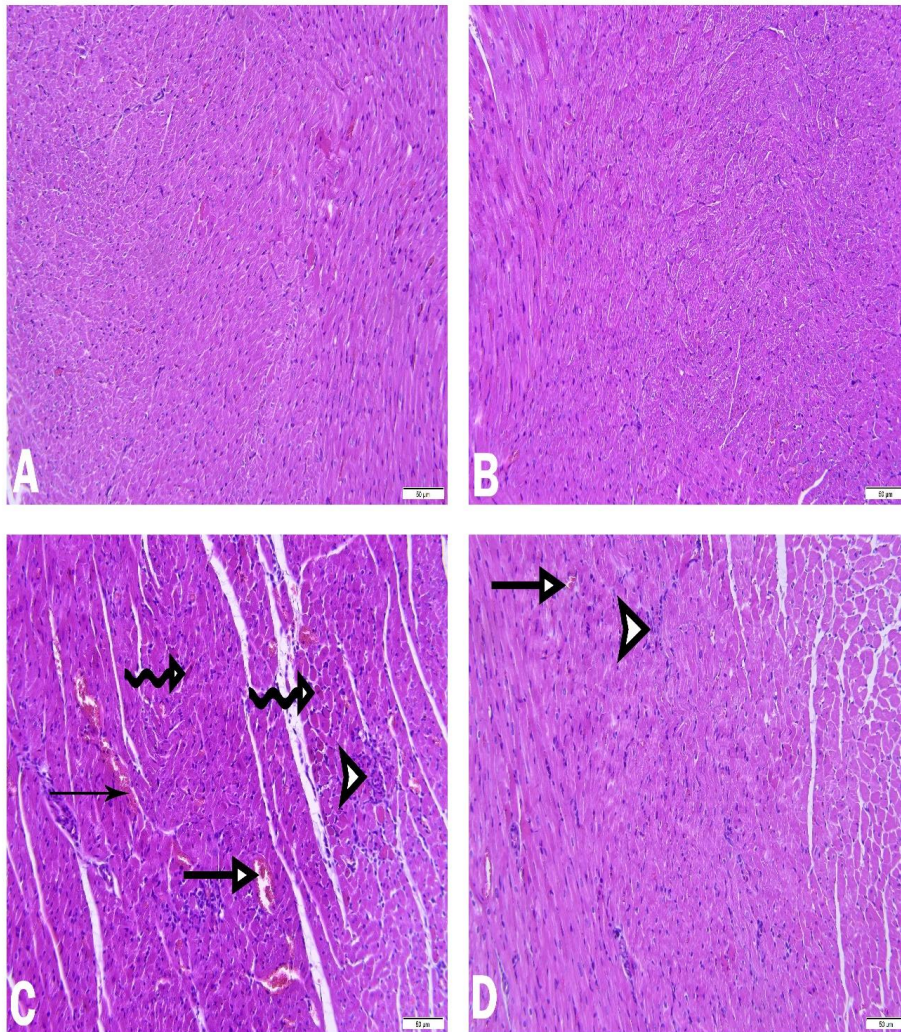


Figure 6. Histopathological evaluation results of rat cardiac tissues treated with Cisplatin (CIS) and Carvacrol (CRV). Heart sections of control (A) and CRV only group (B) show typical histological architecture. CIS only group (C) shows severe histological changes with general loss of normal architecture including disorganized cardiac myofibrils, vascular congestion (thick arrow) and hemorrhage (thin arrow), inflammatory cell infiltration (arrowhead), necrotic cardiomyocytes (curved arrow). CIS+CRV (D) shows mild myocardial degenerative changes such as almost regular cardiac myofibrils, decreased inflammatory cells (arrowhead), rare areas of vascular congestion (thick arrow). Hematoxylin and Eosin (H&E) staining, (Bar: 50 µm)

4. DISCUSSION AND CONCLUSION

Despite its healing effects of CIS, which has a very important place in the fight against cancer, CIS has many side effects. In particular, ventricular dysfunction, impaired cardiomyocyte contractility, and bradycardia due to cisplatin distribution in the sinoatrial node area are of great concern [10, 11]. The first step underlying these hemodynamic abnormalities in the heart is oxidative stress, as presented in this study. Others include effects on inflammation, apoptosis, autophagy, and the Notch signaling pathway [11, 24-26].

Chemotherapeutic drugs generally damage the cell membrane and release intracellular proteins. This may be due to cell membrane lipid peroxidation, which may impair the integrity and function of cardiocytes [14, 27, 28]. Due to these effects, CIS increases reactive molecules in heart tissue and causes depletion of antioxidant molecules [29]. GSH, an antioxidant, plays an important role in maintaining cell security and scavenging ROS. SOD, CAT, and GPx are antioxidant enzymes necessary for improving heart function. While CAT and GPx dissociate H₂O₂, SOD dismutates the superoxide anion [30-36]. The use of antioxidant treatment in chemotherapy is an important area of research because of the potential of antioxidants to mitigate the harmful side effects of chemotherapeutic agents while maintaining or enhancing their efficacy. Chemotherapeutic agents produce excess amounts of reactive oxygen species as part of their mechanism of action against cancer cells. Oxidative damage may also affect the integrity of healthy tissues and has side effects, such as cardiotoxicity, nephrotoxicity, hepatotoxicity, and neurotoxicity. Antioxidants can counteract this damage by neutralizing ROS and reducing tissue damage in healthy cells [37-39]. In this study, it was determined that acute administration of CIS probably induced lipid peroxidation in the heart tissue and thus reduced SOD, CAT, and GPx activities. This result is likely due to inhibition of the breakdown of O₂⁻ into molecular oxygen and water. CRV administration regulated antioxidant levels (SOD, GPx) similar to the control.

Oxidative stress and inflammation are closely related biologically and play common roles in the pathogenesis of organ damage [40-42]. Increased ROS contributes to disease pathogenesis by mediating the expression of the redox-sensitive transcription factor NF- κ B and inducing excessive release of proinflammatory cytokines [43-46]. Previous *in vitro* rat studies have shown that CIS triggers NF- κ B and inflammatory cytokine mRNA expression in different tissues and causes damage to multiple organs [17, 47]. The current study revealed that Cisplatin causes an increase in the expression levels of NF- κ B, TNF- α and IL-1 β and this increase is a strong trigger for the inflammatory cascade. In conclusion, CIS induces inflammatory cell infiltration into cardiac tissue. When cisplatin and CRV combined treatment was compared with CIS treatment alone, a decrease in NF- κ B, TNF- α and IL-1 β expressions was observed. This result was found to be consistent with recent studies showing that CRV has anti-inflammatory properties [6,19].

Another important consequence of CIS-induced ROS increase is the apoptosis process [20]. Bax protein plays an important role in apoptosis and is a proapoptotic factor found in the cytosol that belongs to the Bcl-2 family. When apoptosis is triggered, Bax is transported to the mitochondria, and cytochrome c release is induced [48, 49]. Cytochrome c released into the cytosol also initiates the activation of cysteine proteases. Among cysteine proteases, caspase 3 is the main apoptotic effector, leading to cytoskeletal disassembly, nuclear destruction, and other changes associated with apoptosis [50-53]. All mechanisms involved in inducing caspase-3 activity play a role in CIS-induced apoptosis [54].

In the present study, it was found that the ratio of the proapoptotic Bax gene to the antiapoptotic Bcl-2 gene shifted toward proapoptosis in pathological processes such as ischemic heart disease, dilated cardiomyopathy, and myocardial infarction [16, 17]. In another study, following CIS administration, a significant increase in caspase-3 activity and nuclear DNA fragmentation was observed in heart tissue, which was reported to indicate apoptotic cell death [55]. This study showed that CIS treatment was associated with Bax overexpression and low expression of the antiapoptotic Bcl-2 gene. Therefore, the Bax/Bcl-2 ratio increased; it was shown that it acts as a regulator determining the sensitivity of cells to apoptosis as a proapoptotic index. In addition, CIS has been shown to activate all these apoptotic pathways and trigger caspase 3. These results can be explained by the fact that CIS significantly promotes the release of large amounts of reactive oxygen species, which is considered a direct trigger for the apoptosis process. CRV treatment showed its effect by suppressing the expression of the proapoptotic Bax protein, reducing the expression of the apoptotic mediator Casp-3, and increasing the expression of the antiapoptotic Bcl-2 molecule. In conclusion, CRV's regulation of the mitochondrial pathway may be due to its strong antioxidant properties that potentially prevent apoptosis.

Another consequence of CIS-induced oxidative stress is cardiac cell death, which involves autophagy and apoptosis [56]. Autophagy is an important mechanism for controlling cell homeostasis. It is a critical biological process involved in catabolic processes, such as the elimination of damaged and misfolded proteins [57]. However, excessive autophagy stimulates functional and structural disorders in cells [58, 59]. The autophagy process is regulated by specific genes such as Beclin-1, LC3A, and LC3B [60]. Beclin-1 is an indispensable protein for cell-related processes such as development, immunity, and tumor suppression. LC3 activates autophagosome formation, and LC3A is converted to LC3B form via conjugation with phosphatidylethanolamine. LC3B protein is triggered by oxidative stress and contributes to the formation of autophagosome [42, 61, 62]. In the current study, it was found that CIS increased Beclin-1, LC3A, and LC3B expression in rat heart tissue, whereas CRV treatment decreased autophagy protein expression. In the present study, the increase in autophagy with CIS drug

administration caused cell damage, which can also be explained in histopathological images.

The discovery of new pathways that may play a role in CIS-induced cardiac tissue damage is a promising therapeutic approach. In recent years, the possible role of the notch pathway in CIS-induced organ toxicities has been investigated, and it has been emphasized that this pathway should also be investigated. The notch signaling pathway is conserved throughout evolution and plays a critical role in determining cell fate during development. The notch gene family encodes a single-pass transmembrane receptor that participates in the signaling pathway [26, 63]. Mammals have four notch genes (Notch 1-4). JAG1, JAG2, DLL1, DLL3, and DLL4. Notch1 and Notch2 are widely expressed in mammals and play an important role in embryonic development. One of the best-known notch target genes is the Hairy-Enhancer of Split (HES)1 protein, which acts as a transcriptional repressor [63, 64]. In this study, the mRNA levels of Notch1 and Hes1 were significantly decreased in the CIS group, and CRV treatment significantly increased the decrease in translational levels of the evaluated Notch1 and Hes1 pathway molecules.

Studies have emphasized that oxidative stress, inflammation, and cell death contribute to the pathophysiology of acute CIS-induced cardiotoxicity, with pathological changes being involved in the process [14, 24, 29].

The biochemical and molecular findings in the present study were confirmed by histopathological examination of heart tissues showing fiber degeneration, vascular congestion, hemorrhage, inflammatory cell infiltration, and necrosis in the CIS group. In addition, in the histopathological evaluation performed in the group given CRV together with CIS, CRV protected the myocardial structure. In summary, the antioxidant potential of CRV reduced histopathological changes, supporting our hypothesis that it could protect against CIS-induced cardiotoxicity.

In conclusion, the findings show that CRV has promising cardioprotective effects against CIS-induced cardiotoxicity and improves cardiac damage markers. The healing effect of CRV was achieved by reducing oxidative stress, inflammation, apoptosis, and autophagy. Additionally, the Notch signaling pathway was impaired in CIS but was reversed by CRV. This study revealed a possible role for the Notch pathway in the pathogenesis of cisplatin-induced cardiotoxicity. This strategy also paves the way for further investigation of the Notch pathway and makes it promising to test other Notch inhibitors for their possible cardioprotective properties in future studies.

REFERENCES

- [1] Gur C, Kandemir FM, Caglayan C, Satici, E. Chemopreventive effects of hesperidin against paclitaxel-induced hepatotoxicity and nephrotoxicity via amendment of Nrf2/HO-1 and caspase-3/Bax/Bcl-2 signaling pathways. *Chemico-biological interactions*.2022; 365:110073.
- [2] Aksu EH, Kandemir FM, Yıldırım S, Küçükler S, Dörtbudak MB, Çağlayan C, et al. Palliative effect of curcumin on doxorubicin-induced testicular damage in male rats. *Journal of biochemical and molecular toxicology*. 2019; 33(10):e22384.
- [3] Erkaya N, Parlak SN. Effects of beta-1, 3-D glucan on systemic bortezomib treated rat pancreas *Journal of Experimental and Clinical Medicine*.2022; 39 (3):743-748
- [4] Dehghani MA, Shakiba Maram N, Moghimipour E, Khorsandi L, Atefi Khah M, Mahdavinia M. Protective effect of gallic acid and gallic acid-loaded Eudragit-RS 100 nanoparticles on cisplatin-induced mitochondrial dysfunction and inflammation in rat kidney. *Biochimica et biophysica acta. Molecular basis of disease*, 2020;1866(12):165911.
- [5] Ileriturk M, Ileriturk D, Kandemir O, Akaras N, Simsek H, Erdogan E, et al. Naringin attenuates oxaliplatin-induced nephrotoxicity and hepatotoxicity: A molecular, biochemical, and histopathological approach in a rat model. *Journal of biochemical and molecular toxicology*. 2024;38(1):e23604.
- [6] Dinc K, Ozyurt R, Coban TA, Yazici GN, Suleyman Z, Yavuzer B, et al. The effect of carvacrol on the proinflammatory cytokines, histology, and fertility outcome of cisplatin-related ovarian change in a rat model. *Taiwanese journal of obstetrics & gynecology*. 2023; 62(2):256–263.
- [7] Ragab TIM, Zoheir KMA, Mohamed NA, El Gendy AEG, Abd-ElGawad AM, Abdelhameed MF, et al. Cytoprotective potentialities of carvacrol and its nanoemulsion against cisplatin-induced nephrotoxicity in rats: development of nano-encapsulation form. *Heliyon*. 2022;8(3):e09198.
- [8] Stojic IM, Zivkovic VI, Srejovic IM, Nikolic TR, Jeremic NS, Jeremic JN, et al. Cisplatin and cisplatin analogues perfusion through isolated rat heart: the effects of acute application on oxidative stress biomarkers. *Molecular and cellular biochemistry*. 2028;439(1-2), 19–33.
- [9] Lash LH. Unexpected Enhancement of Cytotoxicity of Cisplatin in a Rat Kidney Proximal Tubular Cell Line Overexpressing Mitochondrial Glutathione Transport Activity. *International journal of molecular sciences*. 2022; 23(4), 1993.
- [10] Rosic G, Srejovic I, Zivkovic V, Selakovic D, Joksimovic J, Jakovljevic V. The effects of N-acetylcysteine on cisplatin-induced cardiotoxicity on isolated rat hearts after short-term global ischemia. *Toxicology reports*. 2015; 2: 996–1006.
- [11] El-Shoura EAM, Hassanein EHM, Taha HH, Shalkami AS, Hassanein MMH, Ali FEM, et al. Edaravone and obeticholic acid protect against cisplatin-induced heart toxicity by suppressing

- oxidative stress and inflammation and modulating Nrf2, TLR4/p38MAPK, and JAK1/STAT3/NF- κ B signals. *Naunyn-Schmiedeberg's archives of pharmacology*. 2024;397(8):5649–
- [12] El-Sawalhi MM, Ahmed LA. Exploring the protective role of apocynin, a specific NADPH oxidase inhibitor, in cisplatin-induced cardiotoxicity in rats. *Chemico-biological interactions*. 2014; 207:58–66.
- [13] Tanyeli A, Eraslan E, Güler M, Kurt N, Akaras N. Gossypin Protects Against Renal Ischemia-Reperfusion Injury in Rats. *Kafkas Univ Vet Fak Derg*. 2010; 26 (1): 89-96.
- [14] Yildirim C, Cangı S, Orkmez M, Yılmaz SG, Bozdayı MA, Yamaner H, et al. Sinapic acid attenuated cisplatin-induced cardiotoxicity by inhibiting oxidative stress and inflammation with GPX4-mediated NF- κ B modulation. *Cardiovascular Toxicology*. 2013; 23(1):10-22.
- [15] Zhao L. Protective effects of trimetazidine and coenzyme Q10 on cisplatin-induced cardiotoxicity by alleviating oxidative stress and mitochondrial dysfunction. *Anatolian journal of cardiology*. 2019; 22(5):232–239.
- [16] Saleh DO, Mansour DF, Mostafa RE. Rosuvastatin and simvastatin attenuate cisplatin-induced cardiotoxicity via disruption of endoplasmic reticulum stress-mediated apoptotic death in rats: targeting ER-Chaperone GRP78 and Calpain-1 pathways. *Toxicology reports*. 2020;7:1178–1186.
- [17] Soliman AF, Anees LM, Ibrahim DM. (2018). Cardioprotective effect of zingerone against oxidative stress, inflammation, and apoptosis induced by cisplatin or gamma radiation in rats. *Naunyn-Schmiedeberg's archives of pharmacology*. 2018; 391(8):819–832.
- [18] El-Sayed EM, Abd-Allah AR, Mansour AM, El-Arabey AA. Thymol and carvacrol prevent cisplatin-induced nephrotoxicity by abrogation of oxidative stress, inflammation, and apoptosis in rats. *Journal of biochemical and molecular toxicology*. 2015; 29(4):165–172.
- [19] Aksu EH, Kandemir FM, Altun S, Küçükler S, Çomaklı S, Ömür AD. Ameliorative Effect of Carvacrol on Cisplatin-Induced Reproductive Damage in Male Rats. *Journal of biochemical and molecular toxicology*. 2016; 30(10):513–520.
- [20] Hassanshahi A, Kaeedi A, Rahmani MR, Hassanshahi J. The Effects of ThymusCaramanicus Jalas Extract and Its Main Constituent Carvacrol Against Cisplatin-Induced Nephrotoxicity in Mice. *Iranian journal of pharmaceutical research IJPR*. 2024;23(1): e140212.
- [21] Gencer S, Gür C, İleritürk M, Küçükler S, Akaras N, Şimşek H, et al. The ameliorative effect of carvacrol on sodium arsenite-induced hepatotoxicity in rats: Possible role of Nrf2/HO-1, RAGE/NLRP3, Bax/Bcl-2/Caspase-3, and Beclin-1 pathways. *Journal of biochemical and molecular toxicology*. 2024; 38(10):e23863.
- [22] Şimşek H, Gür C, Küçükler S, İleritürk M, Akaras N, Oz M, et al. Carvacrol Reduces Mercuric Chloride-Induced Testicular Toxicity by Regulating Oxidative Stress, Inflammation, Apoptosis, Autophagy, and Histopathological Changes. *Biol Trace Elem Res*. 2024;202(10):4605–4617.
- [23] Livak KJ, Schmittgen TD. Analysis of relative gene expression data using real-time quantitative PCR and the 2(-Delta Delta C(T)) Method. *Methods*. 2001; 25 (4):402–408.
- [24] Bukhari IA, Mohamed OY, Alhowikan AM, Lateef R, Hagar H, Assiri RA, et al. Protective Effect of Rutin Trihydrate Against Dose-Dependent, Cisplatin-Induced Cardiac Toxicity in Isolated Perfused Rat's Heart. *Cureus*. 2022;14(1):e21572.
- [25] Coskun R, Turan MI, Turan IS, Gulapoglu M. The protective effect of thiamine pyrophosphate, but not thiamine, against cardiotoxicity induced with cisplatin in rats. *Drug and chemical toxicology*. 2014; 37(3):290–294.
- [26] Abd El-Rhman RH, El-Naga RN, Gad AM, Tadros MG, Hassaneen SK. Dibenzazepine Attenuates Against Cisplatin-Induced Nephrotoxicity in Rats: Involvement of NOTCH Pathway. *Front Pharmacol*. 2020; 11:567852.
- [27] Semis HS, Kandemir FM, Kaynar O, Dogan T, Arikan SM. The protective effects of hesperidin against paclitaxel-induced peripheral neuropathy in rats. *Life sciences*. 2021; 287:120104.
- [28] Ağgül AG, Kuzu M, Kandemir FM, Küçükler S, Çağlayan C. Alterations in Enzyme Activity of Carbonic Anhydrase, 6-phosphogluconate Dehydrogenase and Thioredoxin Reductase in Rats Exposed to Doxorubicin and Morin. *Clinical and Experimental Health Sciences*. 2020;10 (3), 228-234
- [29] Başak Türkmen N, Aşkın Özek D, Taşlıdere A, Çiftçi O, Saral Ö, Gül CC. Protective Role of Diospyros lotus L. in Cisplatin-Induced Cardiotoxicity: Cardiac Damage and Oxidative Stress in Rats. *Turk J Pharm Sci*. 2022;19(2):132-137.
- [30] Keleş O, Can S, Cıgsar G, Colak S, Erol H, Akaras N, et al. Hepatoprotective effects of B-1, 3-(D)-glucan on bortezomib-induced liver damage in rats. *Kafkas Universitesi Veteriner Fakultesi Dergisi*, 2014;20(6):929-38.
- [31] Ekinçi-Akdemir FN, Yildirim S, Kandemir FM, Gülçin İ, Küçükler S, Sağlam YS, et al. The effects of casticin and myricetin on liver damage induced by methotrexate in rats. *Iran J Basic Med Sci*. 2018;21(12):1281-1288.
- [32] FM Kandemir, M Ozkaraca, S Küçükler, C Çağlayan, B Hanedan. Preventive effects of hesperidin on diabetic nephropathy induced by streptozotocin via modulating TGF- β 1 and oxidative DNA damage. *Toxin reviews*. 2018;37 (4):287-293
- [33] Aydın M, Cevik A, Kandemir FM, Yuksel M, Apaydin AM. Evaluation of hormonal change, biochemical parameters, and histopathological status of uterus in rats exposed to 50-Hz electromagnetic field. *Toxicology and industrial health*. 2009;25(3):153–158.
- [34] Semis HS, Gur C, İleritürk M, Kaynar O, Kandemir FM. (2021). Investigation of the anti-inflammatory effects of caffeic acid phenethyl ester in a model of

- λ -Carrageenan-induced paw edema in rats. *Human & experimental toxicology*. 2021; 40: S721–S738.
- [35] Erisir M, Kandemir FM, Yüksel M. The effects of Cesarean section on lipid peroxidation and some antioxidants in the blood of newborn calves. *Veterinarski arhiv*. 2013; 83 (2):153-159
- [36] Akaras N, Toktay E, Celep NA, Yüce N, Şimşek H, Özkan Hİ. Antioxidant Effects of Bromelain on Paracetamol-Induced Renal Injury in Rats. *Arch Basic Clin Res*. 2023; 10: 1-8
- [37] Varışlı B, Caglayan C, Kandemir FM, Gür C, Ayna A, Genç A, et al. Chrysin mitigates diclofenac-induced hepatotoxicity by modulating oxidative stress, apoptosis, autophagy and endoplasmic reticulum stress in rats. *Molecular Biology Reports*. 2023; 50(1): 433-442.
- [38] Ayna A, Özbolat S. N, Darendelioglu E. Quercetin, chrysin, caffeic acid and ferulic acid ameliorate cyclophosphamide-induced toxicities in SH-SY5Y cells. *Molecular Biology Reports*. 2020; 47:8535-8543
- [39] Kızıl HE, Caglayan C, Darendelioglu E, Ayna A, Gür C, Kandemir FM, et al. Morin ameliorates methotrexate-induced hepatotoxicity via targeting Nrf2/HO-1 and Bax/Bcl2/Caspase-3 signaling pathways. *Molecular Biology Reports*. 2023; 50(4):3479-3488.
- [40] Taştan Bal T, Akaras N, Demir Ö, Ugan RA. Protective effect of astaxanthin and metformin in the liver of rats in which the polycystic ovary syndrome model was formed by giving letrozole. *Iran J Basic Med Sci*. 2023;26(6):688-694.
- [41] Şimşek H, Küçükler S, Gür C, Akaras N, Kandemir FM. Protective effects of sinapic acid against lead acetate-induced nephrotoxicity: a multi-biomarker approach. *Environ Sci Pollut Res Int*. 2023;30(45):101208-101222.
- [42] Şimşek H, Küçükler S, Gür C, İleritürk M, Aygörmez S, Kandemir FM. Protective effects of zingerone against sodium arsenite-induced lung toxicity: A multi-biomarker approach. *Iran J Basic Med Sci*. 2023;26(9):1098-1106.
- [43] Akaras N, İleritürk M, Gur C, Kucukler S, Oz M, Kandemir FM. The protective effects of chrysin on cadmium-induced pulmonary toxicity; a multi-biomarker approach. *Environ Sci Pollut Res Int*. 2023;30(38):89479-89494.
- [44] Akaras N, FM Kandemir, H Şimşek, C Gür, S Aygörmez. Antioxidant, Antiinflammatory, and Antiapoptotic Effects of Rutin in Spleen Toxicity Induced by Sodium Valproate in Rats. *Türk Doğa ve Fen Dergisi*. 2023; 12 (2):138-144
- [45] Akaras N, Simsek H, Ordu M. A histological and biochemical study of the protective role of hesperidin in testicular ischemia-reperfusion injury. *Int J Med Biochem* 2023;6(1):21-27
- [46] Akaras N, Gür C, Şimşek H, Tuncer SÇ. Effects of Quercetin on Cypermethrin-Induced Stomach Injury: The Role of Oxidative Stress, Inflammation, and Apoptosis. *Gümüşhane Üniversitesi Sağlık Bilimleri Dergisi*. 2023;12 (2):556-566
- [47] Khadrawy YA, Hosny EN, El-Gizawy MM, Sawie HG, Aboul Ezz HS. The Effect of Curcumin Nanoparticles on Cisplatin-Induced Cardiotoxicity in Male Wistar Albino Rats. *Cardiovasc Toxicol*. 2021;21(6):433-443.
- [48] Akarsu SA, Gür C, İleritürk M, Akaras N, Küçükler S, Kandemir FM. Effect of syringic acid on oxidative stress, autophagy, apoptosis, inflammation pathways against testicular damage induced by lead acetate. *J Trace Elem Med Biol*. 2023;80:127315.
- [49] Akaras N, Kucukler S, Gur C, İleritürk M, Kandemir FM. Sinapic acid protects against lead acetate-induced lung toxicity by reducing oxidative stress, apoptosis, inflammation, and endoplasmic reticulum stress damage. *Environ Toxicol*. 2024;39(7):3820-3832.
- [50] Akaras N, Gür C, Caglayan C, Kandemir FM. Protective effects of naringin against oxaliplatin-induced testicular damage in rats: Involvement of oxidative stress, inflammation, endoplasmic reticulum stress, apoptosis, and histopathology. *Iran J Basic Med Sci*. 2024;27(4):466-474.
- [51] Akarsu SA, İleritürk M, Küçükler S, Akaras N, Gür C, Kandemir FM. Ameliorative effects of sinapic acid against vancomycin-induced testicular oxidative damage, apoptosis, inflammation, testicular histopathologic disorders and decreased epididymal sperm quality. *Reprod Toxicol*. 2024;129:108666.
- [52] Akarsu SA, Gür C, Küçükler S, Akaras N, İleritürk M, Kandemir FM. Protective Effects of Syringic Acid Against Oxidative Damage, Apoptosis, Autophagy, Inflammation, Testicular Histopathologic Disorders, and Impaired Sperm Quality in the Testicular Tissue of Rats Induced by Mercuric Chloride. *Environ Toxicol*. Published online August 3, 2024.
- [53] Yılmaz S, Gur C, Kucukler S, Akaras N, Kandemir FM. Zingerone attenuates sciatic nerve damage caused by sodium arsenite by inhibiting NF- κ B, caspase-3, and ATF-6/CHOP pathways and activating the Akt2/FOXO1 pathway. *Iran J Basic Med Sci*. 2024;27(4):485-491.
- [54] Ekinci Akdemir FN, Yildirim S, Kandemir FM, Aksu EH, Guler MC, Kiziltunc Ozmen H, et al. The antiapoptotic and antioxidant effects of eugenol against cisplatin-induced testicular damage in the experimental model. *Andrologia*. 2019;51(9):e13353.
- [55] Xing JJ, Mi XJ, Hou JG, Cai EB, Zheng SW, Wang SH, et al. (2022). Maltol mitigates cisplatin-evoked cardiotoxicity via inhibiting the PI3K/Akt signaling pathway in rodents in vivo and in vitro. *Phytotherapy research: PTR*. 2022;36(4):1724–1735.
- [56] Ma W, Wei S, Zhang B, Li W. Molecular Mechanisms of Cardiomyocyte Death in Drug-Induced Cardiotoxicity. *Front Cell Dev Biol*. 2020;8:434.
- [57] Semis HS, Gur C, İleritürk M, Kandemir FM, Kaynar O. Evaluation of Therapeutic Effects of Quercetin Against Achilles Tendinopathy in Rats via Oxidative Stress, Inflammation, Apoptosis, Autophagy, and Metalloproteinases. *Am J Sports Med*.

- [58] Kandemir FM, Ileriturk M, Gur C. Rutin protects rat liver and kidney from sodium valproate-induced damage by attenuating oxidative stress, ER stress, inflammation, apoptosis and autophagy. *Mol Biol Rep.* 2022;49(7):6063-6074.
- [59] Çomaklı S, Özdemir S, Küçükler S, Kandemir FM. Beneficial effects of quercetin on vincristine-induced liver injury in rats: Modulating the levels of Nrf2/HO-1, NF-kB/STAT3, and SIRT1/PGC-1 α . *J Biochem Mol Toxicol.* 2023;37(5):e23326.
- [60] Kankılıç NA, Şimşek H, Akaras N, Gür C, Ileritürk M, Küçükler S, et al. Protective effects of naringin on colistin-induced damage in rat testicular tissue: Modulating the levels of Nrf-2/HO-1, AKT-2/FOXO1A, Bax/Bcl2/Caspase-3, and Beclin-1/LC3A/LC3B signaling pathways. *J Biochem Mol Toxicol.* 2024;38(2):e23643.
- [61] Tuncer SÇ, Küçükler S, Gür C, Aygörmez S, Kandemir FM. Effects of chrysin in cadmium-induced testicular toxicity in the rat; role of multi-pathway regulation. *Mol Biol Rep.* 2023;50(10):8305-8318.
- [62] Kankılıç NA, Küçükler S, Gür C, Akarsu SA, Akaras N, Şimşek H, et al. Naringin protects against paclitaxel-induced toxicity in rat testicular tissues by regulating genes in pro-inflammatory cytokines, oxidative stress, apoptosis, and JNK/MAPK signaling pathways. *Journal of biochemical and molecular toxicology.* 2024; 38(7):e23751.
- [63] Zhou B, Lin W, Long Y, Yang Y, Zhang H, Wu K, et al. Notch signaling pathway: architecture, disease, and therapeutics. *Signal Transduct Target Ther.* 2022;7(1):95.
- [64] Luo X, Zhang L, Han GD, Lu P, Zhang Y. MDM2 inhibition improves cisplatin-induced renal injury in mice via inactivation of Notch/hes1 signaling pathway. *Hum Exp Toxicol.* 2021;40(2):369-379.