

Case Report / Olgu Sunumu

Lung Adenocarcinoma: a Rare Metastasis to the Tongue

Akciğer Adenokarsinomunun Nadir Görülen Dil Metastazı

Mehmet GÜVEN, Serpil ÖCAL,¹ Ahmet EYİBİLEN, İbrahim ALADAĞ, Doğan KÖSEOĞLU²

Departments of Otorhinolaryngology, ¹Thoracic Diseases, ²Pathology, Medical Faculty of Gaziosmanpaşa University, Tokat

Submitted / Başvuru tarihi: 17.09.2008 Accepted / Kabul tarihi: 26.10.2008

Metastatic lesions in the tongue are extremely rare. A 60-year-old man with lung adenocarcinoma is presented in this report. He had no metastases except simultaneous tongue and cervical lymph node metastases.

Key words: Tongue metastasis; lung adenocarcinoma.

Metastatik lezyonlar dilde oldukça nadir görülür. Bu yazıda dil metastazı bulunan akciğer adenokarsinomlu 60 yaşında erkek hasta sunuldu. Hastanın dil ve servikal lenf nodu metastazları dışında uzak metastazı saptanmadı.

Anahtar sözcükler: Tongue metastasis; lung adenocarcinoma.

Metastatic neoplasms of the oral region originating from distant sites are rare and consist only 1% of all oral malignant tumors.^[1] They are most often located in the mandible, where a majority occurs in the molar region.^[2] Metastatic tumors of the oral region typically originate from the breast, followed by the lungs, kidney, thyroid gland, intestines, prostate gland, stomach and bladder.^[2,3]

Tumor metastasis to the tongue is extremely rare, with a frequency of 0.1% to 0.2% in autopsy series of patients with disseminated cancer.^[4] Possible routes of metastasis to the tongue include systemic, venous and lymphatic circulations. A case of lung adenocarcinoma with simultaneous tongue and cervical lymph node metastases is presented in this report, which had no additional distant metastases.

CASE REPORT

A 60-year-old man attended to our clinic with persistent painful mass in the right side of the tongue with blood streaked saliva and dysphagia for two months. His medical story included myocardial infarction nine years before. Curative radiotherapy and six cycles of

chemotherapy with docetaxel 120 mg and cysplatin 120 mg for lung adenocarcinoma had been applied in another clinic one year ago. He reported a history of smoking one pack of cigarettes per day for the past 40 years. Physical examination revealed a 3x3x2 cm non-ulcerative, hard, submucosal lumb on the right postero-lateral aspect of the tongue with bilateral multiple cervical lymphadenopathy on the II. and III. levels of the neck. Magnetic resonance imaging (MRI) showed a large infiltrating tumor (3x2 cm in size) on the right postero-lateral side of the tongue (Fig. 1a) and bilateral cervical lymphadenopathy (Fig. 1b). The incisional lingual biopsy demonstrated the pathologic diagnosis of adenocarcinoma metastasis (Fig. 2a). Cytological examination of the specimen obtained by bronchial brushing performed during bronchoscopy indicated adenocarcinoma (Fig. 2b), whose appearance was similar to that of the tongue. Chest X-ray graphy showed a mass on the right upper lobe involving the right middle lobe and pleural effusion (Fig. 3). Abdominal ultrasonography and cranial computerized tomography scans revealed no other distant metastases. Liver function tests, serum lactate dehydrogenises and total serum calcium levels were within normal range. The patient was treated with

Correspondence (İletişim adresi): Dr. Mehmet Güven. Gaziosmanpaşa Üniversitesi Tıp Fakültesi Kulak Burun Boğaz Hastalıkları Anabilim Dalı, 60100 Tokat. Tel: 0264 - 255 21 02 Fax (Faks): 0264 - 255 21 02 e-mail (e-posta): guvenmehmet28@yahoo.com

© Trakya Üniversitesi Tıp Fakültesi Dergisi. Ekin Tıbbi Yayıncılık tarafından basılmıştır. Her hakkı saklıdır.

© Medical Journal of Trakya University. Published by Ekin Medical Publishing. All rights reserved.

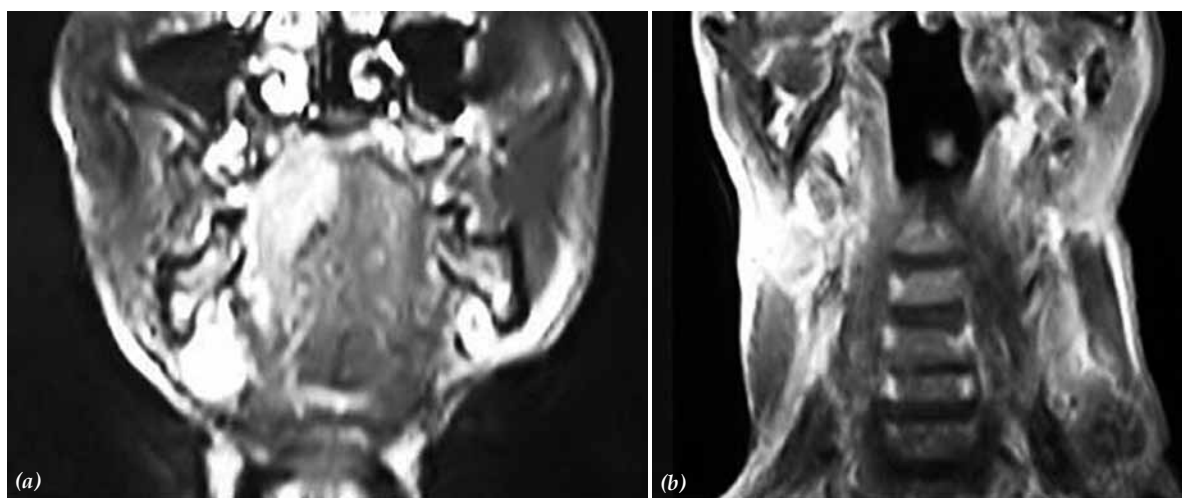


Fig. 1. MRI showing (a) a mass on the left side of the tongue involving the base and the mid-line and (b) bilateral multiple cervical lymph node metastasis.

second line chemotherapy and palliative tongue and neck irradiation therapy, but the treatment was not effective and the patient died two months after the diagnosis of tongue metastasis.

DISCUSSION

Metastatic tumors to the jaws seldom occur and metastases to the oral soft tissues occur even less frequently. The overall frequency of metastasis to both jaws, oral mucosa and gingiva is about 1% and the jaws are involved in 90% of those cases.^[5] The oral soft tissues are the sites of distant metastasis in about 10%.

There is no consensus on site preference for mucosal metastasis of the oral soft tissues. The tongue was the most common location in a study^[5] and the gingiva in another.^[6] Baden et al.^[7] reported that tongue metastasis caused by the lungs 21%, kidneys 21%, and skin 17%, were the most common sites of origin of the primary malignant neoplasms.

In spite of contemporary increase in the incidence of lung cancers, tongue metastasis has remained to be rare with 0.1% to 0.2%. Tongue base is the most commonly affected site of the tongue, because it is relatively immobile and contains many lymphatic and blood vessels. Kim et al.^[8] reviewed some of the literature on the metastasis of the oral cavity, and reported that the base of the tongue was the site most commonly involved, probably because of its rich lymphatic and blood vessels structure. In the present case, the metastatic lingual tumor was located on the postero-lateral side of the tongue.

Tongue metastasis may be the initial presentation of lung cancer, nevertheless, as in our case, it may be an evidence of late metastasis of the carcinoma. It tends to occur most commonly in patients who have general dissemination of a primary malignancy.^[9] In our case, tongue and cervical lymphatic metastasis were found together as the first distant metastatic region of the lung

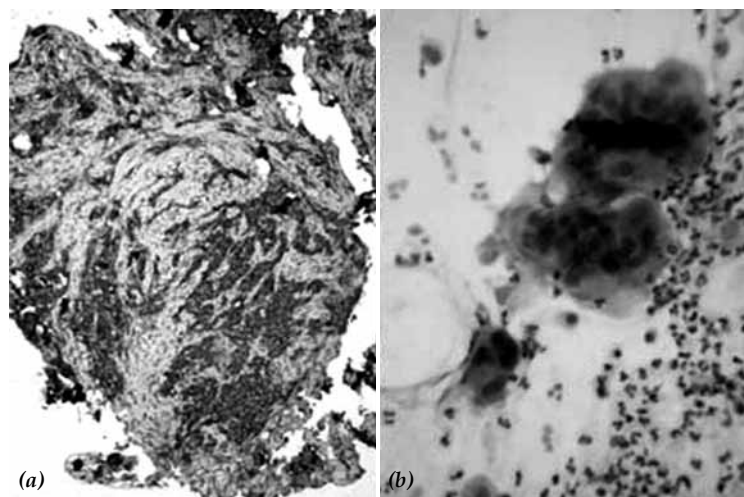


Fig. 2. (a) The extensive and strong CEA immunostaining in strands and islands consisted of atypical epithelial cells in skeletal muscle tissue of the tongue biopsy (AEC x 10) (b) The three dimensional cell clusters formed by atypical epithelial cells with pleomorphic, hyperchromatic nuclei in bronchial lavage smears (H-E x 40).

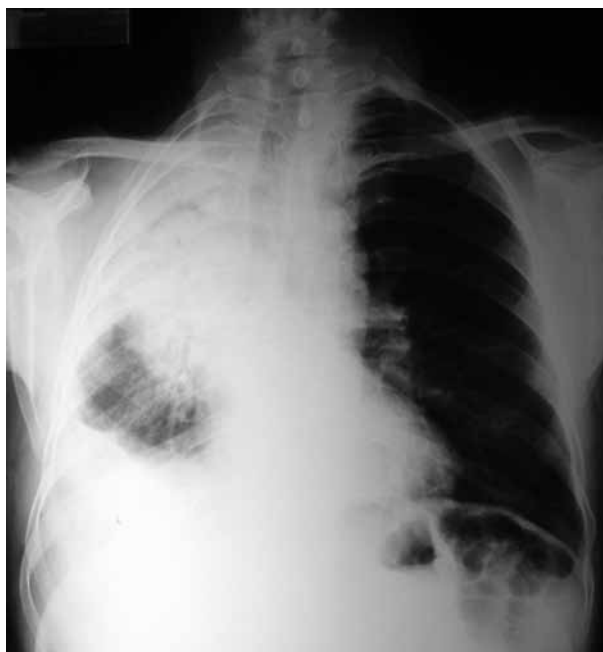

Fig. 3. Chest X-ray graphy showing pleurisy and lack of aeration on the right upper and middle lobes.

adenocarcinoma. No additional distant metastasis was detected.

Primary malignancies can spread by means of three pathways: systemic circulation, venous circulation and lymphatic circulation. Systemic circulation has played a role in the pathogenesis more frequent than the others.^[10] Because most patients who are seen initially for lingual metastasis have widespread metastasis at diagnosis, the systemic circulation seems to be the most common path for tumor cell.^[10] Tumor cell from the lung can enter the left side of the heart and thus the systemic circulation through a pulmonary vein. The vertebral veins of Batson have been thought to be possible venous conduit for tumor cells. At the cervical level, metastasis may reach the tongue via the pennate and peltate venous plexuses. Retrograde lymphatic metastatic spread may also occur, but this is the most unlikely route.^[10] According to our knowledge, there is no simultaneous tongue and cervical lymph node metastasis of lung cancer previously reported. Since our patient had no distant metastasis except for tongue and cervical lymph node, the lymphatic circulation seems to be the possible path for distant metastasis.

The prognosis of the patients with lingual metastasis is poor; most of the reported cases died within six months.^[7] This is probably due to the fact that head and neck metastasis are usually accompanied or preceded by other metastatic lesions in other anatomic sites, indicating widespread disease. Thus, the probability of complete recovery is minimal. Surgical resection can be considered for patients who have isolated lingual metastasis and a resectable primary cancer. Treatment with chemotherapy and irradiation may prove to be effective in the treatment of metastatic disease,^[11] but in our case is not effective.

In this report, a case of lung adenocarcinoma with no distant metastasis except for simultaneous tongue and cervical lymph node is presented.

REFERENCES

1. Zachariades N. Neoplasms metastatic to the mouth, jaws and surrounding tissues. *J Craniomaxillofac Surg* 1989;17:283-90.
2. Yoshii T, Muraoka S, Sano N, Furudoi S, Komori T. Large cell carcinoma of the lung metastatic to the mandibular gingiva. *J Periodontol* 2002;73:571-4.
3. Hirshberg A, Leibovich P, Buchner A. Metastases to the oral mucosa: analysis of 157 cases. *J Oral Pathol Med* 1993;22:385-90.
4. Zegarelli DJ, Tsukada Y, Pickren JW, Greene GW Jr. Metastatic tumor to the tongue. Report of twelve cases. *Oral Surg Oral Med Oral Pathol* 1973;35:202-11.
5. Friedlander AH, Singer R. Renal adenocarcinoma of the kidney with metastasis to the tongue. *J Am Dent Assoc* 1978;97:989-91.
6. Hatziotis JC, Constantinidou H, Papanayotou PH. Metastatic tumors of the oral soft tissues. Review of the literature and report of a case. *Oral Surg Oral Med Oral Pathol* 1973;36:544-50.
7. Baden E, Duvillard P, Micheau C. Metastatic papillary endometrial carcinoma of the tongue. Case report and review of the literature. *Arch Pathol Lab Med* 1992;116:965-8.
8. Kim RY, Perry SR, Levy DS. Metastatic carcinoma to the tongue: a report of two cases and a review of the literature. *Cancer* 1979;43:386-9.
9. Batsakis JG. The pathology of head and neck tumors: the occult primary and metastases to the head and neck, Part 10. *Head Neck Surg* 1981;3:409-23.
10. Mui S, Smith AE. Lingual metastasis as the initial presentation of a large cell lung carcinoma. *Otolaryngol Head Neck Surg* 1999;121:305-6.
11. Terashima T, Matsuzaki T, Kawada I, Nishida J, Tanaka Y, Morishita T, et al. Tongue metastasis as an initial presentation of a lung cancer. *Intern Med* 2004;43:727-30.