

Anatomical Risk Factors of Coronary Heart Disease

Koroner Kalp Hastalığının Anatomik Risk Faktörleri

Nesrin ÇANDIR, Hasan OZAN, Necdet KOCABIYIK, Hürkan KUŞAKLIGİL¹

Departments of Anatomy and ¹Cardiology, Gülhane Military Medical School, Ankara

Submitted / Başvuru tarihi: 27.12.2008 Accepted / Kabul tarihi: 02.04.2009

Objectives: The aim of this study was to explore the possible anatomical risk factors of coronary heart disease (CHD) such as vascular geometry of the left coronary artery and its branches using coronary angiography.

Patients and Methods: The trunk length (T) of the left coronary artery, the curve angle of the left anterior descending artery (LAD) and the bifurcation angle between the LAD and the circumflex artery (Cx) were measured in 77 patients (age range 20-83, mean 58.9±11.68).

Results: The atherosclerotic plaque existence was investigated in LAD and Cx. The mean values of the T length, LAD curve angle and the LAD-Cx bifurcation angle were respectively 12.86 mm, 140.99° and 94.07°. In patients who have atherosclerotic plaques in LAD, the mean value of the T lengths was found 2.5 mm shorter than those of the patients whose LADs are intact (p=0.020). On the other hand a significant negative correlation between the LAD curve angle and the bifurcation angle was found (p<0.001).

Conclusion: In view of our results it can be suggested that geometrical pattern of LAD and its branches may be a congenital risk factor in development of CHD in patients who have no other risk factors.

Key words: Coronary heart disease; coronary angiography; left coronary artery; circumflex artery; atherosclerosis.

Amaç: Çalışmanın amacı koroner anjiyografi kullanarak sol koroner arterin vasküler geometrik özellikleri gibi konjenital kalp hastalıklarının muhtemel anatomik risk faktörlerini açıklamaktır.

Hastalar ve Yöntemler: Sol koroner arterin trunk uzunluğu (T), arteria interventricularis anterior (LAD)'un dönüş açısı, LAD ve arteria circumflexa (Cx) arasındaki bifurkasyon açısı 77 hastada (yaş aralığı 20-83, ort. 58.9±11.68) ölçüldü.

Bulgular: Arteria interventricularis anterior (LAD) ve Cx'de aterosklerotik plak varlığı araştırıldı. Sol koroner arterin trunk uzunluğu, LAD dönüş açısı ve LAD-Cx bifurkasyon açıları değerleri sırasıyla ortalama 12.86 mm, 140.99° ve 94.07° idi. Arteria interventricularis anterior'de aterosklerotik plağı olan hastalarda ortalama T değerleri LAD'leri intakt olan hastalarinkinden 2.5 mm daha kısa bulundu (p=0.020). Diğer taraftan LAD dönüş açısı ile bifurkasyon açısı arasında negatif korelasyon bulundu (p<0.001).

Sonuç: Sonuçlarımıza göre LAD ve dallarının geometrik özellikleri, başka risk faktörü olmayan CHD'li hastaların gelişiminde bir risk faktörü olabilir.

Anahtar sözcükler: Koroner kalp hastalığı; koroner anjiyografi; arteria interventricularis anterior; arteria circumflexa; aterosklerosis.

Presented at the 20th International Symposium on Morphological Sciences, September 12-16, 2008, Timișoara, Romania (20. Uluslararası Morfolojik Bilimler Sempozyumu'nda sunulmuştur, 12-16 Eylül 2008, Timișoara, Romanya).

Correspondence (İletişim adresi): Dr. Necdet Kocabiyik. Gülhane Askeri Tıp Fakültesi Anatomi Ana Bilim Dalı, 06018 Ankara, Türkiye.
Tel: 0312 - 304 35 01 Fax (Faks): 0312 - 304 21 50 e-mail (e-posta): nkocabiyik@gata.edu.tr

© Trakya Üniversitesi Tıp Fakültesi Dergisi. Ekin Tıbbi Yayıncılık tarafından basılmıştır. Her hakkı saklıdır.
© Medical Journal of Trakya University. Published by Ekin Medical Publishing. All rights reserved.

Left coronary artery, which is the main source supply to the left ventricle, the left atrium, minor part of the right ventricle, anterior 2/3 of the interventricular septum and left and right branches of the conducting system, arises from the left posterior aortic sinus behind the pulmonary trunk. Its trunk has a length between 5-20 mm and is thicker than right coronary artery. After this short course it divides into its two terminal branches; LAD (left anterior descending artery / anterior interventricular branch) and Cx (circumflex artery). Considering the fact that it has a big role in blood supply of the heart and serious diseases as atherosclerosis, left coronary artery and its branches have been an important issue for studies.^[1-6]

Although several cardiovascular risk factors, such as hypercholesterolemia, diabetes, hypertension and smoking have been associated with coronary heart disease (CHD), it is a conventional knowledge that these factors can explain only the half of the variability in the occurrence of atherosclerosis or CHD.^[3,6-9]

This means that there are additional risk factors that predispose atherosclerosis and CHD. During the past few decades, it has been shown that the vascular flow pattern has an effect on the development and progression of atherosclerosis.^[8,10-13] Friedman and Ding^[3] proposed that variations in arterial geometry may have a role in some of the unexplained variations in cardiovascular risk. Considering the fact that the most of the atherosclerotic plaques localize particularly at bifurcation sites, most commonly on the ostium of the LAD^[2,7,14] it can be suggested that the angulations of the coronary bifurcations might have an effect on the incidence of atherosclerosis.

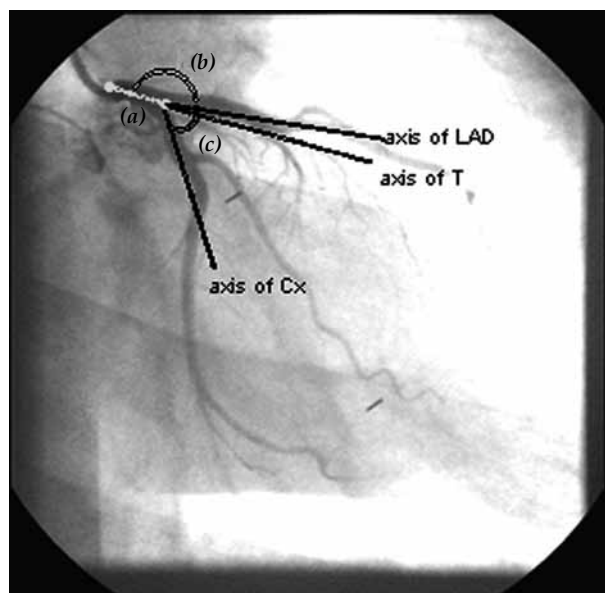


Fig. 1. Measurement points; (a) T length, (b) LAD curve angle, (c) LAD-Cx bifurcation angle. Dotted dash represents the axes of the arteries. The angles were measured between these axes. T: Trunk of the left coronary artery; LAD: Left anterior descending artery; Cx: Circumflex artery.

Another hypothesis is that the length of the main left coronary artery trunk (T) may play a role in development of atherosclerosis.^[11,15] Gazetopoulos et al.^[7] also suggested that a short left coronary artery should be considered as a congenital risk factor in development of CHD. Although these studies mentioned the significant effect of the trunk length of the left coronary artery, subsequent studies^[16] did not confirm this relationship. The MT is generally considered to be between 5–15 mm long.^[5] But there is no commonly agreed upon definition of a short and long MT. In this study we aimed to clarify this confusion.

The objective of this study was to analyze the possible anatomical risk factors of CHD like as vascular geometry of the left coronary artery and its branches using coronary angiography. The trunk length (T) of the left coronary artery, the curve angle of the LAD and the bifurcation angle between the LAD-Cx were measured to demonstrate if there is any relationship between these parameters and atherosclerosis.

PATIENTS AND METHODS

Angiographic images of 77 patients (29 females, 48 males) from the cardiology department of Gülhane Military Medical Academy Faculty of Medicine were studied in this study. The mean age of cases was 58.90 ± 11.68 (ranged between 20–83). Cases were selected randomly from the patient population of cardiology department. Patients with hypercholesterolemia, diabetes, hypertension and smokers were excluded to determine the possible effect of the geometry of the arteries independently from the other risk factors.

The T length, the LAD curve angle and the LAD-Cx bifurcation angle were measured and also a possible correlation between these parameters and atherosclerosis was searched. The angiographic images were determined from the left anterior caudal sight. Ruler and goniometer were used in measurements. The T length was measured between the points where the left coronary artery arises from aorta and where bifurcates into its terminal branches, LAD and Cx. The angles were measured between the axes of the arteries (Fig. 1).

Also the existence of atherosclerotic plaques was investigated in LAD and Cx and statistical analyses were made to evaluate the relationship of these parameters with atherosclerosis.

The information of the cases and the results were analyzed statistically. The mean \pm standard deviation (SD) was calculated for the variables which were determined with measurements. Number, % values were reported and X² test was used for statistical analysis. Mann-Whitney U test was selected for analyzing the relationship of atherosclerotic plaque existence with the T length and the LAD curve angle, and for its relationship with LAD-Cx bifurcation angle Student's t test was used. For all of these statistical analyses SPSS for Win.

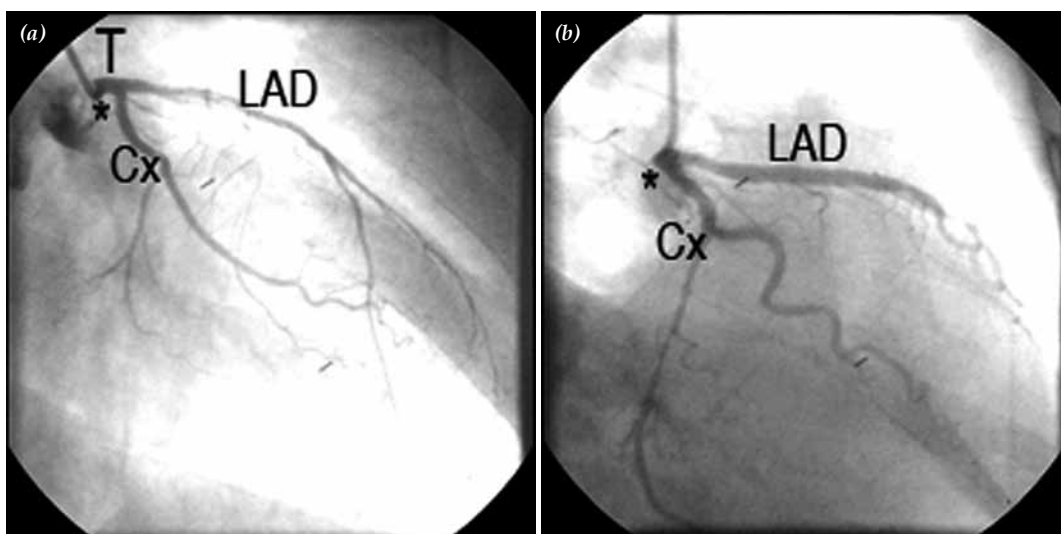


Fig. 2. Short left coronary arteries with atherosclerotic plaques in LAD. (a) T 9 mm atherosclerotic plaque exists in proximal LAD, (b) T 3 mm atherosclerotic plaque exists in mid-segment of LAD. T: trunk of the left coronary artery; LAD: left anterior descending artery.

Ver. 15.00 (Statistical Package for Social Sciences-Basic and Advanced Statistics Inc., Chicago, IL., USA) was used. P values were calculated with significant set at $p \leq 0.05$.

RESULTS

The result of the measurements was summarized in Table 1. The T length was between 3-30 mm (12.86 ± 5.52 mm) in all samples. We classified these measurements into three groups. Group 1 represents the trunks which are between 0 and 5 mm ($n=5$, 6.5%). Group 2 represents the interval 5 to 15 mm ($n=39$, 50.65%). Group 3 represents the trunk lengths greater than 15 mm

Table 1. Statistical results of measurements

	n	min.	max.	mean \pm SD
Age				
General	77	20	83	58.89 \pm 11.68
Female	26	49	83	63.86 \pm 7.88
Male	51	20	80	56.22 \pm 12.55
T Length (mm)				
General	77	3	30	12.86 \pm 5.52
Female	26	3	30	13.07 \pm 5.84
Male	51	4	27	12.74 \pm 4.90
LAD Curve Angle ($^{\circ}$)				
General	77	62	172	140.99 \pm 21.91
Female	26	110	168	141.38 \pm 19.37
Male	51	62	172	140.78 \pm 23.32
LAD-Cx Bifurcation Angle ($^{\circ}$)				
General	77	33	165	94.07 \pm 25.72
Female	26	33	126	84.62 \pm 23.79
Male	51	56	165	99.15 \pm 25.48

T: Trunk of the left coronary artery; LAD: Left anterior descending artery; Cx: Circumflex artery.

($n=33$, 42.85%). Left anterior descending artery of 27 patients was normal, whereas in 50 patients flow pattern abnormalities were observed. These were results of atherosclerotic plaques ($n=46$, 92%), bridges ($n=1$, 2%) or flow pattern slowness ($n=3$, 6%). In patients who have atherosclerotic plaques in LAD, we found that the mean value of T length is 2.5 mm shorter than the mean value of the cases with intact LAD ($p=0.020$) (Fig. 2a, b).

The curve angle of the LAD was ranging between 62° to 172° ($141.00 \pm 21.91^{\circ}$). The number of the cases who have an atherosclerotic plaque in LAD or its bifurcation was 46 (59.70%). Among these 46 cases, 26 (56.52%) have a LAD curve angle lesser than 140° and 20 (43.48%) have an angle greater than 140° . These results demonstrated that there is no statistically meaningful correlation between the LAD curve angle and atherosclerosis.

We also measured the LAD-Cx bifurcation angle to evaluate the effect of this angle to the LAD and atherosclerosis. It was between 33° to 165° ($94.07 \pm 25.72^{\circ}$) in all cases. Twenty five (54.34%) of the patients who have an atherosclerotic plaque in LAD, have an angle lesser than 94° and 21 (45.66%) have an angle greater than 94° . We searched for a statistically significant effect of this angle to the atherosclerosis in LAD but according to our results there was no statistically meaningful correlation.

On the other hand, a negative correlation between the LAD curve angle and the bifurcation angle was determined ($p < 0.001$). It was found that the bigger the bifurcation angle, the smaller the LAD curve angle (Table 2).

Trifurcation of MT was observed in 10 of 88 cases (11.36%) but no statistical relationship between this pattern and atherosclerosis was found (Fig. 3).

Table 2. Correlations of parameters with atherosclerotic plaques

Parameter	Atherosclerotic plaques	n	Mean±SD	p
T Length (mm)				
LAD	+	46	14.09±5.51	0.020
	-	31	11.48±4.13	
Cx	+	36	13.34±4.54	0.562
	-	41	13.02±5.48	
LAD Curve Angle (°)				
LAD	+	46	138.09±23.46	0.199
	-	31	144.16±21.25	
Cx	+	36	136.34±24.96	0.192
	-	41	143.44±20.06	
LAD-Cx Bifurcation Angle (°)				
LAD	+	46	95.30±27.06	0.756
	-	31	93.42±24.26	
Cx	+	36	98.37±24.98	0.334
	-	41	92.78±25.01	

T: Trunk of the left coronary artery; LAD: Left anterior descending artery; Cx: circumflex artery.

DISCUSSION

Left coronary artery is the main source supply to the left heart.^[5] The study by Kalbfleisch and Hort^[17] about the area perfused by each of the coronary arteries using post-mortem angiography showed that the left coronary artery supplies the arterial perfusion of the 68.8% of the cardiac muscle mass (41.5% by LAD and 27.3% by Cx) and 79% of the left ventricular cardiac muscle mass (52.6% by LAD and 26.4% by Cx). By these reasons, obstructive diseases of the left coronary artery may reduce the coronary flow to a large proportion of the ventricular myocardium, and therefore, atherosclerotic diseases of it have more serious complications than those of the right coronary artery. Considering all these facts, left coronary artery and its branches have always been important subjects for studies.

The trunk length of the left coronary artery is generally considered to be between 5–15 mm long in textbooks. The mean length of the left coronary artery was variously reported by different authors. Lewis et al.^[15] reported a length of 12.8 mm, Fox et al.^[11] 9.5 mm, Kronzon et al.^[18] 10.4 mm, and Gazetopoulos et al.^[7,12] found it to be 12.4 mm. Although “short” MT and “long” MT were considered as variants in the length of the left coronary artery,^[19] there is no commonly agreed upon definition of a short and long MT. A short MT was considered to be one with a length of ≤ 5 mm.^[20] Fox et al.^[11] reported that in 73% of their cases the MT was ≤ 6 mm in length. We accepted the length of the short trunk as $T \leq 5$ mm. Only 6.5% of the cases in our study presented a MT length of ≤ 5 mm, and these values were more in agreement with the “short trunk” descriptions of McAlpine,^[21] Leguerrier et al.,^[22] Reig and Petit.^[5] There is also no consensus about the definition of a “long” MT. We consider it to be one that is

over 15 mm in length; Green et al.^[9] found “long trunk” in 26% of their cases, McAlpine^[21] in 14%, and differing from them we found it in 42.85% of the cases. In previous studies we could not find any report about a relationship between a long MT and any type of pathology.

Lewis et al.,^[15] Glagov^[10] and Gazetopoulos et al.^[7,12] also suggested that a short left coronary artery should be considered as a congenital risk factor in development of CHD. Lewis and Gotsman^[11] found a relationship between a short main left coronary artery and complete left bundle-branch block in 11 out of 12 cases. Gazetopoulos et al.^[7,12] studied about the length of the main left coronary artery with selective coronary arteriography in 43 persons. These authors stated that the length of the main left coronary artery was found to be significantly shorter in patients with coronary atherosclerosis than in subjects without angiographic evidence of coronary artery disease. Considering our results are in adjustment with these findings, it can be suggested that a short main left coronary artery should be accepted as a congenital factor predisposing to the development of coronary artery disease. Another report of Gazetopoulos et al.^[7] about the relation between the length of the main left coronary artery and the degree of atherosclerosis in its branches was a postmortem examination in 204 subjects. Their findings suggested that in cases with a short main left coronary artery the atherosclerotic lesions in the anterior descending and circumflex branches appear earlier, progress faster at higher levels of severity, and lead more frequently to myocardial infarction, than in cases with a long left coronary artery trunk.

In previous studies another statement about the T length is that it also has an effect on LAD-Cx bifurcation angle. Gazetopoulos et al.,^[7,12] Reig and Petit^[5] suggest that there is a positive correlation between the length of the trunk and

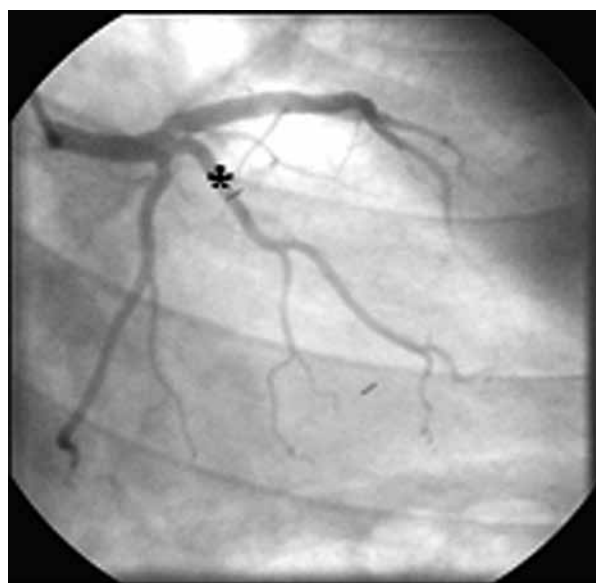

Fig. 3. Trifurcation (*) with an atherosclerotic plaque in proximal LAD.

the bifurcation angle, with the longest trunk has the largest angle. Although our results are similar to those of this study we did not find this relation statistically meaningful.

Some authors described relation between the LAD-Cx bifurcation angle and atherosclerosis.^[3,6] The angiographic study of Rodriguez-Granillo et al.^[6] suggested that the bifurcation angle and the atherosclerotic plaques existence within the bifurcation are closely related. Friedman and Ding^[3] stated that large branch angles may favor eccentric intimal thickening, a phenomenon which may predispose to lipid accumulation and atherosclerosis in their study on 15 human hearts with multi-plane contrast angiograms. Nevertheless in this present study we did not find a statistically meaningful relation between LAD-Cx bifurcation angle and atherosclerosis existence.

Another controversial topic is the division of the MT. Banchi described a termination varying between two or three branches with the most common situation (64%) the bifurcation of the MT into its terminal branches, the LAD and the Cx (cited by Reig et al.^[23]) He also determined the possibility of the MT dividing into three or four branches (31% and 5%, respectively). These complementary branches are termed as median arteries. According to Kalbfleisch and Hort^[18], the most common form of termination of the MT is trifurcation into the LAD, the median artery and the Cx. Other authors report a greater frequency of bifurcation, with the median artery present in between 9–40% of cases.^[7,14,16,22] In our study we found trifurcation of MT in 10 of 77 cases (12.99%) but no statistical relationship between this pattern and atherosclerosis was found.

All our results and previous reports demonstrate that morphological patterns play role in CHD development in patients who have no other risk factors. Considering the fact that the fluid dynamic at the arterial wall is in a close relationship with the vascular geometry and also during the cardiac cycle the vascular angulations can lead to cyclic stresses in the arterial wall which may cause an atherosclerotic response, a through knowledge of these patterns and their relations are very important in clinical diagnosis and management. We hope that further studies will show the other possible effects of these parameters on atherosclerosis.

REFERENCES

1. Fox C, Davies MJ, Webb-Peploe MM. Length of left main coronary artery. *Br Heart J* 1973;35:796-8.
2. Berndt T, Shettigar UR, Lipton MJ, Hultgren HN. Left anterior descending coronary artery obstruction. Clinical, electrocardiographic, and angiographic correlates. *Br Heart J* 1976;38:633-40.
3. Friedman MH, Ding Z. Relation between the structural asymmetry of coronary branch vessels and the angle at their origin. *J Biomech* 1998;31:273-8.
4. Zhu H, Friedman MH. Relationship between the dynamic geometry and wall thickness of a human coronary artery. *Arterioscler Thromb Vasc Biol* 2003;23:2260-5.
5. Reig J, Petit M. Main trunk of the left coronary artery: anatomic study of the parameters of clinical interest. *Clin Anat* 2004;17:6-13.
6. Rodriguez-Granillo GA, Rosales MA, Degrossi E, Durbano I, Rodriguez AE. Multislice CT coronary angiography for the detection of burden, morphology and distribution of atherosclerotic plaques in the left main bifurcation. *Int J Cardiovasc Imaging* 2007;23:389-92.
7. Gazetopoulos N, Ioannidis PJ, Karydis C, Lolas C, Kiriakou K, Tountas C. Short left coronary artery trunk as a risk factor in the development of coronary atherosclerosis. Pathological study. *Br Heart J* 1976;38:1160-5.
8. Frings AM, Mayer B, Böcker W, Hengstenberg C, Willemsen D, Riegger GA, et al. Comparative coronary anatomy in six twin pairs with coronary artery disease. *Heart* 2000;83:47-50.
9. Green GE, Bernstein S, Reppert EH. The length of the left main coronary artery. *Surgery* 1967;62:1021-4.
10. Glagov S. Hemodynamic risk factors: mechanical stress, mural architecture, medial nutrition and the vulnerability of arteries to atherosclerosis. In: Wissler RW, Geer JC, editors. *The Pathogenesis of atherosclerosis*. Baltimore: Williams and Wilkins; 1972. p. 164-99.
11. Lewis BS, Gotsman MS. Relation between coronary artery size and left ventricular wall mass. *Br Heart J* 1973;35:1150-3.
12. Gazetopoulos N, Ioannidis PJ, Marselos A, Kelekis D, Lolas C, Avgoustakis D, et al. Length of main left coronary artery in relation to atherosclerosis of its branches. A coronary arteriographic study. *Br Heart J* 1976;38:180-5.
13. Baroldi G, Scmazzone G. Coronary circulation in the normal heart. In: Baroldi G, Scmazzone G, editors. *Coronary circulation in the normal and the pathologic heart*. Washington: Armed Forces Institute of Pathology, Office of the Surgeon General, Department of the Army. 1965. p. 5-73.
14. Baptista CA, DiDio LJ, Prates JC. Types of division of the left coronary artery and the ramus diagonalis of the human heart. *Jpn Heart J* 1991;32:323-35.
15. Lewis CM, Dagenais GR, Friesinger GC, Ross RS. Coronary arteriographic appearances in patients with left bundle-branch block. *Circulation* 1970;41:299-307.
16. Benthier P, Barra JA, Blanc JJ. Descriptive anatomical study of the major coronary trunks and the principal epicardial collaterals. 125 cases. *Nouv Presse Med* 1976;5:71-5. [Abstract]
17. Kalbfleisch H, Hort W. Quantitative study on the size of coronary artery supplying areas postmortem. *Am Heart J* 1977;94:183-8.
18. Kronzon I, Deutsch P, Glassman E. Length of the left main coronary artery: its relation to the pattern of coronary arterial distribution. *Am J Cardiol* 1974;34:787-9.
19. Angelini P, Villason S, Chan AV Jr, Diez JG. Normal and anomalous coronary arteries in humans. In: Angelini P, editor. *Coronary artery anomalies: a comprehensive approach*. Philadelphia: Lippincott Williams and Wilkins; 1999. p. 27-151.
20. Vlodayer Z, Edwards JE. Editorial: Occlusion of coronary grafts--result of injury? *Ann Thorac Surg* 1975;20:719-20.
21. McAlpine WA, editor. *Heart and coronary arteries: an anatomical atlas for clinical diagnosis, radiological investigation, and surgical treatment*. New York: Springer-Verlag; 1975.
22. Leguerrier A, Calmat A, Honnart F, Cabrol C. Anatomic variations of the common trunk of the left coronary artery (apropos of 80 dissections). *Bull Assoc Anat* 1976;60:733-9. [Abstract]
23. Reig J, Loncán MP, Martín S, Doménech JM. The circumflex branch of the left coronary artery in the human infant. *J Anat* 1987;155:7-10.