

Nosocomial *Leuconostoc Pseudomesenteroides* Meningitis: A Case Report and Review of the Literature

Özlem Taşkapılıoğlu¹, Aslı Bahar¹, Emel Yılmaz², Mustafa Bakar¹

¹Department of Neurology, School of Medicine, Uludağ University, Bursa, Turkey

²Department of Infectious Diseases and Clinical Microbiology, School of Medicine, Uludağ University, Bursa, Turkey

ABSTRACT

Leuconostoc spp, a member of the Streptococci family, was found to cause infection in humans in 1985. These infections have been reported in patients who had received vancomycin to treat their underlying diseases.

Nosocomial meningitis caused by *Leuconostoc* spp. was diagnosed in our patient. An extraventricular drainage system catheter was used due to the presence of a thalamic hematoma with ventricular extension. Central nervous system infections due to *Leuconostoc* spp. are rare. To our knowledge, our case is the sixth case worldwide and the second case reported from Turkey. This case is reported here to draw attention to a rare infectious agent with a high mortality risk.

Key Words: Chloramphenicol, leuconostoc, meningitis, nosocomial

Received: 09.03.2009

Accepted: 07.07.2009

Leuconostoc spp. members of the Streptococcaceae family, are nonmotile, facultative anaerobic gram-positive cocci that are naturally resistant to vancomycin (1). The first case with *Leuconostoc* spp. as a potential cause of human infection was recorded in 1985, after which these organisms were recognized as potential pathogens (2, 3). Infections with *Leuconostoc* spp. bacteria usually affect patients with an underlying disease, with venous catheters, or subjects previously treated with vancomycin (2).

Here, we report a patient with nosocomial meningitis due to *Leuconostoc* spp. An extraventricular drainage system (EVDS) catheter was used because he had a thalamic hematoma with ventricular extension. Central nervous system (CNS) infections due to *Leuconostoc* spp. are rare. Our case is the sixth case worldwide and the second case reported from Turkey. We discuss the case in the context of the literature.

Case Report

A 52-year-old male was admitted to the emergency department with the complaint of altered mental status. He had a Glasgow Coma Scale score of 13 and his neurological examination revealed confusion, disorientation, limited cooperation, and first motor neuron type left hemiparesis involving the face. His cranial computed tomography (CT) demonstrated a 4 cm thalamic hematoma in the right cerebral hemisphere, which had collapsed into both the right lateral ventricle and the 3rd and 4th ventricles (Figure 1A). His medical history revealed hypertension. Neurological parameters were

closely monitored with EVDS in the neurological intensive care unit (Figure 1B). The control cranial CT performed on the 19th day after admission showed resorption of the hemorrhage and the EVDS catheter was removed (Figure 1C). The CSF culture performed on the 16th day after admission (3 days prior to catheter removal) was negative. On the 28th day after admission, he had new onset fever (38.5°C) and headache. He was lethargic, but other system examinations were normal. Laboratory findings revealed a leukocyte count of 8,600/mm³, 215,000 platelets/mm³, aspartate transaminase (AST) of 68 IU/ml, and alanine transaminase (ALT) of 179 IU/ml. Other laboratory findings were unremarkable. A lumbar puncture (LP) was performed to eliminate nosocomial meningitis as a possible fever focus in the patient. Microscopic examination of the CSF revealed 180 leucocytes/mm³ (70% polymorphonuclear leukocytes, 30% lymphocytes) and biochemical tests indicated elevated protein (70 mg/dl) and normal glucose (53 mg/dl; accompanying serum glucose, 118 mg/dl). There was no microorganism on the CSF gram stain. Empirical therapy with intravenous vancomycin (1 g/12 h) and meropenem (2 g/8 h) was started with the putative diagnosis of nosocomial meningitis. The CSF and blood cultures obtained during the fever episode produced *Leuconostoc pseudomesenteroides* with a negative EVDS catheter culture. *Leuconostoc pseudomesenteroides* was confirmed using the Phoenix System™ (NMIC/ID-5 panel, Becton Dickson, Sparks, MD, USA). The isolate was also determined to be sensitive to amoxicillin, levofloxacin, rifampicine, and tetracycline. Antimicrobial susceptibility tests were performed using both the Phoenix

This case was presented at the 43th National Neurology Congress 2007

Address for Correspondence: Dr. Özlem Taşkapılıoğlu, Department of Neurology, School of Medicine, Uludağ University, Bursa, Turkey
Phone: +90 224 295 17 22 E-mail: ozlemhan@uludag.edu.tr

System™ and the Kirby-Bauer disc diffusion method, which was made and set up according to Clinical and Laboratory Standards Institute standard protocol (4). Intravenous vancomycin and meropenem were replaced with intravenous chloramphenicol (1g/ 8h) and ciprofloxacin (400 mg/12h) because of the natural resistance of the bacteria. Repeated LPs were performed on days 5, 15, 18, and 30 of the therapeutic regimen of chloramphenicol and ciprofloxacin. The microscopic examination of the CSF obtained from these LPs revealed no cells and the CSF was negative for culture only in the LPS performed on the 18th and 30th days of the treatment. Intravenous chloramphenicol was stopped on the 19th day of this treatment. The patient was discharged with stable vital signs and motor neuron-type left hemiparesis of 4/5 muscle strength.

Discussion

Bacteremia, meningitis, breast abscess, peritonitis, abdominal and brain abscesses, and odontoid and urinary tract infections with *Leuconostoc* spp. have been reported (2, 5). In the literature, there are six cases, including ours, of CNS infection due to *Leuconostoc* spp. Four of these were diagnosed as meningitis, one was a brain abscess, and the other one was nosocomial ventriculitis. Clinical features of the cases are summarized in Table 1 (3, 6-9).

Leuconostoc spp. usually found on vegetables and food products, are not a member of the usual human flora, but have been isolated from vaginal and stool samples (3). The source of the isolate has been debated in the literature since these

organisms are not considered part of the normal human flora. Some have suggested skin as a possible portal; others have raised the possibility of access to the bloodstream through the gastrointestinal tract (GIT) (1). Nosocomial transmission may be via contaminated hands; urinary catheterization may also play a role in the development of *Leuconostoc* septicemia (2, 10). Three of the reported cases support the nosocomial transmission theory because they developed infection after an invasive intervention involving the CNS; whereas, one of the cases that developed infection after colostomy supports the theory of translocation from the GIT (7-9).

Leuconostoc infections occur more frequently in patients being treated for underlying diseases with vancomycin therapy, although these infections have also been documented in otherwise healthy patients (2, 6). Our patient had not received vancomycin therapy before the detection of *Leuconostoc* spp. as shown by the negative CSF and blood cultures obtained before treatment. Three of the six cases with prior steroid therapy before infection differ greatly from the remaining cases (3, 9). Prior treatment with steroids seems to predispose patients to CNS infections with *Leuconostoc* spp. (3).

Penicillin is an antibiotic commonly used to treat *Leuconostoc* spp. infections. In catheter-associated infections, removal of the catheter is the priority (1). Identification of the bacteria is very important because of its resistance to vancomycin (1). We preferred intravenous chloramphenicol to treat our patient because of its good CNS penetration, its reported success in the treatment of *Leuconostoc* meningitis, and the sensitivity of the bacteria to chloramphenicol (6). Cephalospo-

Table 1. Clinical features of the central nervous system infections due to *Leuconostoc* spp (3, 6-9)

Reported Date	Age	Sex	Symptoms/ Findings	Diagnosis	Invasive Intervention	Prior Steroid Use	Treatment (Duration-Day)	Outcome
1987 ⁶	16 y	F	Altered mental status, headache, vomiting, neck stiffness, Kernig's sign, Brudzinski's sign, leukocytosis	Meningitis	None	No	P(14)+CHL(5)	Recovery
1990 ⁷	1 mo	F	Irritability, increased tonus, brisk reflexes, bulging fontanella, anemia, leukocytosis	Meningitis	Colostomy	No	P(NK)+CFX(NK); P(NK)+CFX(NK)+CHL(NK)+GEN(NK) (IVT)	Death
2003 ⁸	50 y	M	Altered mental status, fever, leukocytosis	Ventriculitis	Ventricular shunt	No	VA(NK)+CFX(NK); CFX(NK)+LIN(NK); MEM(NK); GAT(NK); GAT(14)+P(14)	Recovery
2006 ³	61 y	F	Hemiparesis, headache, anemia	Brain abscess	None	Yes	CFX(NK); P(42)+AMP(42); AMX (42)	Recovery
2008 ⁹	57 y	F	Altered mental status, fever	Meningitis	LP	Yes	CFT(NK)+VA(NK); LIN(14)	Recovery
2009	52 y	M	Altered mental status, fever	Meningitis	EVDS	Yes	VA(7)+MEM(7) CHL(14)+CIP(10)	Recovery

F: Female, M: Male, y: Year, mo: Month, LP: Lumbar puncture, EVDS: Extraventricular drainage system, IVT: Intraventricular, NK: Not known, P: Penicillin, CHL: Chloramphenicol, CFX: Cefotaxime, GEN: Gentamicin, VA: Vancomycin, LIN: Linezolid, MEM: meropenem, GAT: Gatifloxacin, AMP: Ampicillin, AMX: Amoxicillin, CFT: Ceftazidime, CIP: Ciprofloxacin

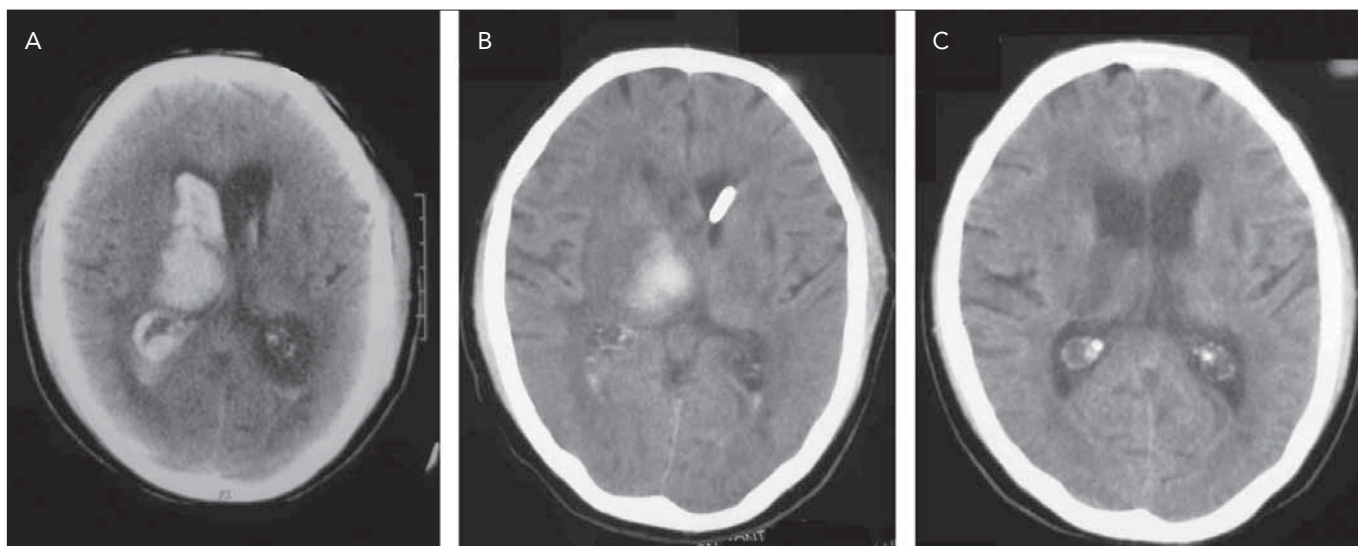


Figure 1. The right thalamic hematoma (A) seen at admission of the patient, and the following cranial computed tomography findings after placement of the EVDS catheter (B) and on the 19th day after admission (C).

rin, gentamicin, gatifloxacin, ampicillin, amoxicillin and linezolid are also options for a successful treatment, as stated in the literature (3, 7-9).

Infections with *Leuconostoc* spp. are rare. We report our case as the sixth case worldwide and the second case from Turkey in order to raise awareness of CNS infection with *Leuconostoc* spp. that may have a high mortality and morbidity risk.

Conflict of Interest

No conflict of interest was declared by the authors.

References

1. Dhodapkar Km, Henry Nk. *Leuconostoc* Bacteremia In An Infant With Short-Gut Syndrome: Case Report And Literature Review. *Mayo Clin Proc* 1996;71:1171-4. [\[CrossRef\]](#)
2. Taneja N, Rani P, Emmanuel R, Khudaier By, Sharma Sk, Tewari R, Sharma M. Nosocomial Urinary Tract Infection Due To *Leuconostoc Mesenteroides* At A Tertiary Care Centre In North India. *Indian J Med Res* 2005;122:178-9. [\[CrossRef\]](#)
3. Albanese A, Spanu T, Sali M, Novegno F, D'inzeo T, Santangelo R, Mangiola A, Anile C, Fadda G. Molecular Identification of *Leuconostoc Mesenteroides* As A Cause Of Brain Abscess In An Immunocompromised Patient. *J Clin Microbiol* 2006;44:3044-5. [\[CrossRef\]](#)
4. CLSI. 2008. Methods For Dilution Antimicrobial Susceptibility Test For Bacteria That Grow Aerobically; Approved Standard, Eighth Ed. M07-A8. Clsi, Wayne, Pa.
5. Wenocur Hs, Smith Ma, Vellozzi Em, Shapiro J, Isenberg Hd. Odontogenic Infection Secondary To *Leuconostoc* Species. *J Clin Microbiol* 1988;26:1893-4.
6. Coovadia Ym, Solwa Z, Van Den Ende J. Meningitis Caused By Vancomycin-Resistant *Leuconostoc* Sp. *J Clin Microbiol* 1987;25:1784-5.
7. Friedland Ir, Snipelisky M, Khoosal M. Meningitis In A Neonate Caused By *Leuconostoc* Sp. *J Clin Microbiol* 1990;28:2125-6.
8. Deye G, Lewis J, Patterson J, Jorgensen J. A Case Of *Leuconostoc* Ventriculitis With Resistance To Carbapenem Antibiotics. *Clin Infect Dis* 2003;37:869-70.
9. Hatipoğlu Ca, Yıldız E, Köktekir E, Ipekkın K, Karakoç Ea, Demiröz Ap. A Case Of Vancomycin Resistant *Leuconostoc* Meningitis. *Mikrobiyol Bul* 2008;42:695-9.
10. Muttaiyah S, Ritchie S, Upton A, Roberts S. Clinical Parameters Do Not Predict Infection In Patients With External Ventricular Drains: A Retrospective Observational Study Of Daily Cerebrospinal Fluid Analysis. *J Clin Microbiol* 2008;57:207-9. [\[CrossRef\]](#)