

Received: 22.11.2024
Accepted: 24.04.2025

Forensic Medical Evaluation of Trauma Cases with Whole-Body Computed Tomography Examination

Tüm Vücut Bilgisayarlı Tomografi Tetkiki Yapılan Travma Olgularının Adli Tıbbi Değerlendirilmesi

 Ufuk Akın¹

¹ Bandırma Onyedi Eylül University, Faculty of Medicine, Department of Forensic Medicine, Balıkesir, Türkiye

Öz

Amaç: Modern acil travma bakımında radyolojik görüntüleme, tanıya götüren yolda oldukça önemli bir basamaktır. Son yıllarda başta tüm vücut bilgisayarlı tomografi (Pan-CT) olmak üzere medikal görüntüleme yöntemlerinin kullanımı oldukça artmıştır. Çalışmamızda travma sonrası Pan-CT çekilen olgularda, sonuçların ne kadarında negatif sonuç (herhangi bir travma bulgusu olmaması), ne kadarında teşhisi, bunun yanında adli rapor ve adli süreci etkileyecek bulgular elde edildiğinin saptanması, literatür verileri ile karşılaştırılması amaçlanmıştır.

Yöntem: Çalışmada 01/01/2023-31/12/2023 tarihleri arasında Bandırma Eğitim ve Araştırma Hastanesi Adli Tıp Polikliniği'ne adli rapor düzenlenmesi amacıyla başvuru ve posttravmatik acil servis sürecinde Pan-CT tetkiki yapılan olgular retrospektif olarak incelenmiştir.

Bulgular: Çalışmaya dahil edilen 261 olgunun %74,3'ü (n=194) erkek, %25,7'si (n=67) kadındı. Olguların yaş ortalaması 37 (±17,54) olarak tespit edildi. Olay türüne baktığımızda motosiklet kazası (n=84, %32,2)'nin ilk sırada olduğu tespit edildi. Pan-CT çekilen olguların sonuçları incelendiğinde, olguların %63,2'sinde (n=165) negatif BT sonucu (normal bulgular), %5,0'inde (n=13) sadece travmatik yumuşak doku bulguları saptandı.

Sonuç: Acil servislerde travma hastalarına çekilen Pan-CT'lerin belirlenmiş endikasyonlarla ve klinik karar verme kılavuzları eşliğinde istenmesi gereksiz görüntüleme tetkiklerinin önüne geçecektir. Bununla birlikte hekimlerin endikasyon gerekçelerini irdelemeleri, klinik verileri değerlendirerek uygun algoritmaları uygulamaları için uygun çalışma ve saha şartlarına sahip olmaları gerekmektedir. Bu şartların sağlanmasıyla elde edilecek tıbbi bulgular ve düzenlenecek tıbbi belgeler, sonraki süreçte yapılacak adli tıbbi değerlendirmeler için de çok daha etkin olacak, adli sürece olumlu katkı sağlayacaktır.

Anahtar Kelimeler: Travma, Tüm vücut bilgisayarlı tomografi, Adli radyoloji, Adli tıp, Pan-BT

Abstract

Objective: Radiological imaging plays a crucial role in diagnosing trauma in modern emergency care. The use of medical imaging techniques, particularly whole-body computed tomography (Pan-CT), has increased significantly in recent years. This study aimed to determine the number of negative Pan-CT results (absence of trauma-related findings) and findings that could influence forensic reports and legal proceedings in trauma cases. The results were also compared with existing literature.

Methods: This retrospective study analyzed cases referred to Bandırma Training and Research Hospital Forensic Medicine Polyclinic for forensic medical assessment between January 1, 2023, and December 31, 2023, who underwent Pan-CT as part of their posttraumatic emergency care.

Results: The study included 261 cases, of whom 74.3% (n = 194) were male and 25.7% (n = 67) were female. The mean age was 37 years (±17.54). Motorcycle accidents were the most common cause of trauma (n = 84, 32.2%). Pan-CT findings showed that 63.2% (n = 165) of cases had negative results (normal findings), while 5.0% (n = 13) exhibited only traumatic soft tissue injuries.

Conclusion: Performing Pan-CT in trauma patients based on established indications and clinical decision-making guidelines can help avoid unnecessary imaging. Physicians should have appropriate conditions to assess indications thoroughly and implement proper evaluation algorithms based on clinical data. Adhering to these principles will enhance the accuracy of medical findings and improve the quality of medical documentation, ultimately strengthening forensic assessments and contributing positively to legal proceedings.

Keywords: Trauma, Whole-body computed tomography, Forensic radiology, Forensic medicine, Pan-CT

How to Cite: Akın U. Forensic Medical Evaluation of Trauma Cases with Whole-Body Computed Tomography Examination. J For Med 2025;39(1):55-62. <https://doi.org/10.61970/adlitip.1589930>

Correspondence: Asisst., Prof., Bandırma Onyedi Eylül University, Faculty of Medicine, Department of Forensic Medicine, Balıkesir, Türkiye
E-mail: ufukakin@bandirma.edu.tr

INTRODUCTION

Trauma, including injuries and violence, causes 4.4 million deaths globally each year, accounting for nearly 8% of all fatalities. It is also responsible for approximately 10% of all years lived with disability and imposes a significant economic burden on nations, costing billions of US dollars annually in healthcare expenses, loss of productivity, and law enforcement costs (1).

Rapid diagnosis and treatment of injuries are essential in modern trauma care. Radiological imaging plays a crucial role in achieving an accurate diagnosis (2). The use of medical imaging techniques, particularly computed tomography (CT), has significantly increased in recent years (2-7). Beyond its role in early diagnosis and treatment, imaging findings obtained are also critical in forensic medicine. Various factors, such as identifying internal organ injuries or internal bleeding, assessing wound depth and trajectory in penetrating injuries, and evaluating bone fractures and their characteristics, are key parameters in forensic medical assessments (8,9).

Despite arguments in favor of selective CT, some studies support whole-body CT (Pan-CT) as a crucial method for reducing mortality (10-12). The Pan-CT approach is characterized by a Pan-CT protocol aimed at minimizing missed injuries and lowering the mortality rate. In a Pan-CT examination, the head, neck, thorax, abdomen, and pelvis are scanned in a single sequence. This includes cervical and cranial CT (without contrast), as well as thoracic, abdominal, and pelvic CT (with intravenous contrast), with oral contrast used when necessary, depending on the case (13,14). Although Pan-CT offers benefits such as reducing missed injuries, significantly shortening hospital stays in emergency settings, and lowering

mortality rates, it also has several drawbacks. These include high radiation exposure, increased overall cost, expensive equipment and maintenance, the risk of contrast-induced nephropathy, limited impact on clinical outcomes, unnecessary additional tests, anxiety from incidental findings, and a lack of consensus on definitive indications (5-7,15-17).

The necessity, effectiveness, and risks of CT examinations have been widely investigated (5-7,18-22). This study aimed to determine the number of negative results (absence of trauma findings) and findings that could influence forensic reports and legal proceedings in posttraumatic Pan-CT cases, comparing the results with existing literature. Additionally, the study sought to examine non-standard factors prompting physicians to request Pan-CT as a medical intervention within the framework of medical law and to propose potential solutions.

MATERIALS AND METHODS

This retrospective study analyzed trauma cases referred to Bandırma Training and Research Hospital Forensic Medicine Polyclinic for judicial reports between January 1, 2023, and December 31, 2023. The study included cases that underwent Pan-CT during posttraumatic emergency care process. Data such as age, sex, type and timing of the incident, judicial report findings, injury location identified in the physical examination, examination findings, and CT report results were obtained from forensic reports and evaluated.

The study included cases referred not only to the Emergency Service but also to the Forensic Medicine Polyclinic to obtain more detailed and verified data. This approach ensured that the study did not solely rely on medical documents issued in the Emergency Service

but also incorporated forensic medicine records. In the Forensic Medicine Polyclinic, anamnesis and posttraumatic medical complaints are recorded more comprehensively compared to the Emergency Service setting. Additionally, external general body examinations are conducted under optimal conditions, allowing for a more thorough assessment and completion of medical documentation. Findings that may have been overlooked, marked as suspicious, clarified, and, when necessary, radiological reports are revised accordingly.

The collected data were analyzed using the Statistical Package for the Social Sciences (SPSS) 30.0 software. Categorical variables were presented as frequency (n) and percentage (%), while numerical variables were reported with mean, standard deviation, median, minimum, and maximum values.

RESULTS

Among the 2,183 cases referred to Bandırma Training and Research Hospital Forensic Medicine Polyclinic for forensic reports between January 1, 2023, and December 31, 2023, who had undergone Pan-CT in the Emergency Service during the posttraumatic period, 261 cases were included in the study. Of these, 74.3% (n = 194) were male, and 25.7% (n = 67) were female. The mean age was 37 years (± 17.54). When classified by age groups, the most common were the third decade (n = 69, 26.4%), followed by the fourth decade (n = 42, 16.1%) and the fifth decade (n = 41, 15.7%) (Table 1).

Traumatic incidents requiring Pan-CT were most frequent in October (n = 34, 13.0%) and November (n = 34, 13.0%), with the highest occurrence between 18:00 and 23:59 (n = 102, 39.1%). The most common causes of trauma were motorcycle accidents (n = 84, 32.2%), in-vehicle traffic accidents (n = 77, 29.5%) and battery (n = 42, 16.1%) (Table 1).

Table 1. Demographic data of the cases and characteristics of the traumatic incidents

Sex	Male	194 (74.3 %)
	Female	67 (25.7 %)
	Total	261 (100 %)
Age	2-82 year (min-max)	36.70 (± 17.54) (Avg. \pm SD)
Age Groups (Decade)	1	9 (3.4 %)
	2	33 (12.6 %)
	3	69 (26.4 %)
	4	42 (16.1 %)
	5	41 (15.7 %)
	6	36 (13.8 %)
	7	19 (7.3 %)
	8	11 (4.2 %)
	9	1 (0.4 %)
	Total	261 (100%)
Trauma Month	1	14 (5.4 %)
	2	11 (4.2 %)
	3	21 (8.0 %)
	4	15 (5.7 %)
	5	30 (11.5 %)
	6	19 (7.3 %)
	7	24 (9.2 %)
	8	23 (8.8 %)
	9	16 (6.1 %)
	10	34 (13.0 %)
	11	34 (13.0 %)
	12	20 (7.7 %)
	Total	261 (100 %)
Trauma Hour	06:00-11:59	42 (16.1 %)
	12:00-17:59	81 (31.0 %)
	18:00-23:59	102 (39.1 %)
	00:00-05:59	36 (13.8 %)
	Total	261 (100 %)
Trauma Cause	Battery	42 (16.1 %)
	Motorcycle Accident	84 (32.2 %)
	In-Vehicle Traffic Accident	77 (29.5 %)
	Non-Vehicle Traffic Accident	27 (10.3 %)
	Firearm Injury	2 (0.8 %)
	Sharp Object Injury	4 (1.5 %)
	Falling from Height	25 (9.6 %)
	Total	261 (100 %)

Based on Pan-CT findings, 63.2% (n = 165) of the cases had negative CT results (normal findings), while 5.0% (n = 13) showed only traumatic soft tissue findings. Additionally, 19.2% (n = 50) had traumatic osseous findings (e.g., fractures, dislocations), 5.7% (n = 15) exhibited internal organ injuries and/or internal bleeding, and 6.9% (n = 18) presented both traumatic osseous findings and internal organ injury and/or internal bleeding (Figure 1).

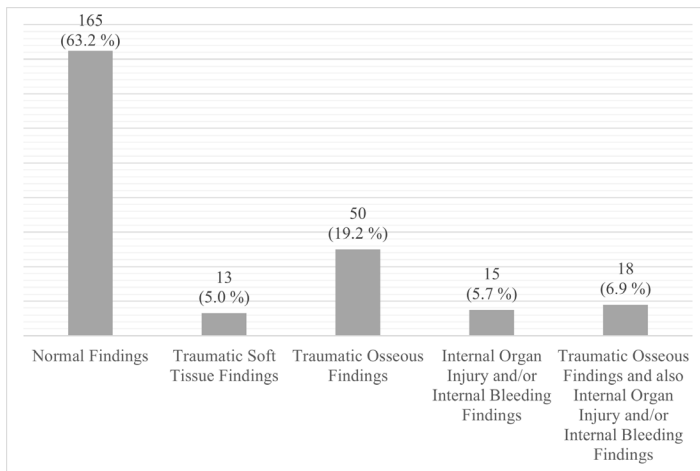


Figure 1. Distribution of Whole-Body Computed Tomography results

The most common trauma site was general body trauma involving two or more regions (n = 146, 55.9%), followed by trauma to the extremities (n = 47, 18.0%) and the head-neck region (n = 46, 17.6%). Regarding physical examination findings, 82.0% (n = 214) of cases had simple lesions such as ecchymosis, abrasion, soft tissue swelling, or lacerations, all treatable with simple medical intervention. Additionally, 16.5% (n = 43) reported only subjective complaints, such as pain, without corresponding physical examination findings. Meanwhile, 1.5% (n = 4) exhibited critical findings,

including altered consciousness, impaired vital signs, or hemodynamic instability (Table 2).

From a forensic medical perspective, 57.9% (n = 151) of the cases had mild injuries that could be treated with simple medical intervention, while 14.9% (n = 39) had injuries classified as life-threatening (Table 2).

Table 2. Characteristics of traumatic findings

Body Region	General Body	146 (55.9 %)
	Head-Neck	46 (17.6 %)
	Thorax	15 (5.7 %)
	Abdomen	7 (2.7 %)
	Extremity	47 (18.0 %)
	Total	261 (100 %)
Examination Findings	Only the Medical Complaints	43 (16.5 %)
	Simple Lesions	214 (82.0 %)
	Critical Findings	4 (1.5 %)
	Total	261 (100 %)
Simple Medical Intervention	Is Present	151 (57.9 %)
	Is not Present	110 (42.1 %)
	Total	261 (100 %)
Life Threatening	Is Present	39 (14.9 %)
	Is not Present	222 (42.1 %)
	Total	261 (100 %)

Among cases with normal Pan-CT findings, motorcycle accidents were the most common cause (n = 57, 34.6%). All cases with normal Pan-CT results (n = 165, 100%) had either no physical examination findings and only reported medical complaints or presented with only simple lesions. Conversely, internal organ injury and/or internal bleeding were identified in one case with only a medical complaint, in 13 cases with only simple lesions, and in 15 cases with both traumatic osseous findings and simple lesions (Table 3).

Table 3. Comparison of Whole-Body Computed Tomography results with trauma cause and examination findings

CT Result						
Trauma Cause / Examination Findings	Normal Findings	Traumatic Soft Tissue Findings	Traumatic Osseous Findings	Internal Organ Injury and/or Internal Bleeding Findings	Traumatic Osseous Findings and also Internal Organ Injury and/or Internal Bleeding Findings	Total
Battery	26 (15.6 %)	1 (7.7 %)	9 (18.0 %)	5 (30.0 %)	1 (5.6 %)	42 (16.1 %)
Motorcycle Accident	57 (34.6 %)	3 (23.1 %)	14 (28.0 %)	3 (18.0 %)	7 (38.8 %)	84 (32.2 %)
In-Vehicle Accident	48 (29.2 %)	2 (15.4 %)	18 (36.0 %)	5 (30.0 %)	4 (22.2 %)	77 (29.5 %)
Non-Vehicle Accident	15 (9.1 %)	4 (30.7 %)	5 (10.0 %)	0 (0.0 %)	3 (16.7 %)	27 (10.3 %)
Firearm Injury	1 (0.6 %)	1 (7.7 %)	0 (0.0 %)	0 (0.0 %)	0 (0.0 %)	2 (0.8 %)
Sharp Object Injury	2 (1.2 %)	0 (0.0 %)	0 (0.0 %)	2 (12.0 %)	0 (0.0 %)	4 (1.5 %)
Falling from Height	16 (9.7 %)	2 (15.4 %)	4 (8.0 %)	0 (0.0 %)	3 (16.7 %)	25 (9.6 %)
Total	165 (100 %)	13 (100 %)	50 (100 %)	15 (100 %)	18 (100 %)	261 (100 %)
Only Medical Complaints	35 (21.2 %)	2 (15.4 %)	5 (10.0 %)	1 (6.7 %)	0 (0.0 %)	43 (16.5 %)
Simple Lesions	130 (78.8 %)	11 (84.6 %)	45 (90.0 %)	13 (86.6 %)	15 (83.3 %)	214 (82.0 %)
Critical Findings	0 (0.0 %)	0 (0.0 %)	0 (0.0 %)	1 (6.7 %)	3 (16.7 %)	4 (1.5 %)
Total	165 (100 %)	13 (100 %)	50 (100 %)	15 (100 %)	18 (100 %)	261 (100 %)

DISCUSSION

Consistent with previous studies, the number of male cases was nearly three times higher than female cases (5,14,23-25). Similarly, young adults were the most affected age group, aligning with findings from other studies (5, 23-25). The higher incidence of traumatic injuries in young males is likely due to their greater involvement in social and professional activities, as well as their higher likelihood of being involved in physical altercations.

A previous study identified 18:00–23:59 as the most common time range for trauma cases undergoing Pan-

CT (23). In our study, most traumas cases requiring Pan-CT occurred between these hours in October and November. This time frame may be associated with peak commuting hours after work, the onset of social activities, and the conclusion of outpatient clinic services. The increased number of cases in October and November may be linked to the influx of newly assigned medical practitioners, including recent medical school graduates, who begin their professional duties in emergency services following the Ministry of Health's large-scale assignments in September. Limited experience, challenges in adaptation, and a defensive approach among these newly appointed practitioners

may contribute to an increased demand for Pan-CT scans.

Studies have shown that posttraumatic Pan-CT is most frequently requested for traffic accident cases (5,14,23-25). Consistent with the literature, over 70% of the cases in this study were involved in traffic accidents, including both in-vehicle and motorcycle accidents, with motorcycle accidents being the most common. Consequently, general body trauma, affecting two or more regions, was observed in more than half of the cases based on injury localization. Traffic accidents, particularly motorcycle crashes, often result in high-energy general body trauma. The inadequate use of protective gear in motorcycle accidents, as well as the limited effectiveness of protective equipment even when used, may lead practitioners to opt for a comprehensive evaluation via Pan-CT. Additionally, it is important to recognize that Pan-CT plays a crucial role in assessing severe trauma cases in the emergency department, particularly when patients are unconscious.

Numerous studies have examined the necessity, effectiveness, and rate of negative results in CT scans performed in emergency settings. One study found that 69% of cranial CT scans in trauma cases had normal results (18). Similarly, in pediatric trauma cases, 98.5% of cranial CT scans showed no abnormalities (5). Another study on infants hospitalized due to falls reported that 83.3% of cranial CT scans revealed no pathology (19). Research on spine and pelvis CT scans following trauma found that 51.2% of cases had negative results (21). Additionally, studies on Pan-CT scans conducted in emergency settings reported normal findings in 52.3% and 49.9% of cases, respectively (24, 25). To reduce unnecessary Pan-CT scans, protocols have been developed to guide patient selection using various assessment methods (26). Similarly, in our study, two-thirds of the cases who underwent Pan-CT did not

have significant findings (63.2% had normal findings, and 5.0% had only traumatic soft tissue findings). The prevalence of Pan-CT use may be influenced by the current defensive medical approach, which prioritizes the principle of “first of all, don’t harm yourself.” This indicates that Pan-CT is often requested without clear indications to avoid missing a diagnosis or to efficiently rule out potential prediagnoses. Factors contributing to this practice include the challenging conditions in emergency departments, patient volumes exceeding capacity, and the pressure on healthcare providers to prioritize patient discharge over extended monitoring. In our study, the identification of life-threatening injuries in cases with only medical complaints or minor physical examination findings suggest that Pan-CT is being used as a compensatory measure under these difficult working conditions to ensure critical injuries are not overlooked. A survey of emergency department practitioners found that 19.7% frequently requested unnecessary CT scans, while 65.2% did so occasionally. Additionally, 77% ordered more CT scans for trauma patients, with medical necessity (86.5%) and fear of missing a diagnosis (79.2%) cited as the most common reasons. Other contributing factors included concerns about legal liability, the convenience of CT compared to other diagnostic methods, limited follow-up time, and insufficient time for thorough examinations (22). In the context of medical law, imaging examinations are considered medical interventions, and in cases of unnecessary medical imaging, the concept of medical intervention without medical indication comes to the fore (27). From a public health perspective, although CT plays a crucial role in medical diagnosis, its potential risks, particularly the increased likelihood of radiation-induced cancer, underscores the importance of careful consideration when requesting these scans (7). It has been noted that polytrauma patients in particular are exposed to significant radiation doses in

diagnostic imaging, resulting in a small but measurable excess cancer risk, and that this small individual risk may become a larger public health concern as more CT scans are performed (28).

A precise and comprehensive definition of posttraumatic pathologies is crucial for forensic medical evaluation (8,9). However, unnecessary imaging examinations can negatively impact the judicial process. Challenges in forensic reporting include distinguishing between acute and chronic or traumatic and nontraumatic findings, discrepancies between patient history and examination results, and the need to clarify ambiguous findings. Access to comparable imaging studies from medical records can help address these issues, but in many cases, additional examinations, reevaluation of reports, and specialist consultations are still necessary. These challenges are particularly significant for forensic medical centers that operate outside hospital settings, such as Forensic Medicine Branch Directorates. As a result, these centers often face requests for report revisions or expert consultations through judicial authorities, further complicating the forensic evaluation process.

CONCLUSION

Unnecessary Pan-CT examinations in trauma patients contribute to both medical and economic challenges. Implementing established indications and clinical decision guidelines can help prevent unwarranted imaging. Physicians must carefully assess the necessity of these examinations, review available clinical data, and ensure that appropriate conditions are met for applying relevant diagnostic protocols. Improving factors such as working conditions, the time allocated for patient evaluation, patient volume, consultation services, and follow-up procedures is essential for optimal evaluation of trauma cases.

Meeting these conditions will enhance the accuracy and relevance of medical findings and documentation, ultimately strengthening forensic medical evaluations and positively impacting the judicial process.

Acknowledgement

Conflict of Interest

The author declare that they have no conflict of interests regarding content of this article.

Financial Support

The Author report no financial support regarding content of this article.

REFERENCES

1. Injuries and violence. Word Health Organization. Available at: <https://www.who.int/news-room/fact-sheets/detail/injuries-and-violence> (cited: 10 October 2024).
2. Patlas MN, DS Katz, Odedra D. Emergency and trauma imaging. In: Patlas MN., DS Katz, Mariano S eds. Atlas of Emergency Imaging from Head-To-Toe. Switzerland: Springer Nature, 2022:3-9.
3. Kocher KE , Meurer WJ, Fazel R, Scott PA, Krumholz HM, Nallamothu BK. National trends in use of computed tomography in the emergency department. Ann Emerg Med 2011;58:452-62.
4. Bellolio MF, Bellew SD, Sangaralingham LR, Campbell RL, Cabrera D, Jeffery MM, Shah ND, Hess EP. Access to primary care and computed tomography use in the emergency department. BMC Health Serv Res 2018;18:154-64.
5. Yıldız OO, Eraybar S, Kaya H, Armagan E. How effective are the computerized tomography imaging prompts in the emergency department? J Contemp Med 2019;9(3):249-54.
6. Sungur C. The Improper Use of Medical Imaging Services and Solution Recommendation. Kahramanmaraş Sutcu Imam University Journal of the Economics and Administrative Sciences 2018;(8)1:67-86.
7. Isik Z, Selcuk H, Albayram S. Computed tomography and radiation. Available at: http://www.tumrad.net/FileUpload/ds58732/File/bt_ve_radyasyon.pdf (cited: 15 October 2024).
8. Yılmaz K, Kaya A, Aktaş EÖ. Forensic Significance of differences between radiology imaging reports based on forensic reports: A retrospective study. Türkiye Klinikleri J Foren Sci Leg Med 2024;21(1):1-9.

9. Seydaogulları Baltacı A, Yılmaz AÖ, Cakmak V, Kurtulus Dereli A, Acar K. Medicolegal evaluation of the effect of radiological examination reports on criminal judgment through a case of hyperostosis frontalis interna. *Turkiye Klinikleri J Foren Sci Leg Med* 2022;19(2):144-8.
10. Salim A, Sangthong B, Martin M, Brown C, Plurad D, Demetriades D. Whole body imaging in blunt multisystem trauma patients without obvious signs of injury: Results of a prospective Study. *Arch Surg* 2006;141(5):468-75.
11. Tillou A, Gupta M, Baraff LJ, Schriger DL, Hoffman JR, Hiatt JR, Cryer HM. Is the use of pan-computed tomography for blunt trauma justified? A prospective evaluation. *The Journal of Trauma, Injury, Infection, and Critical Care* 2009;67(4):779-87.
12. Yasaran I. Evaluation of the requirement of body screening tomography in head trauma patients. (Unpublished Thesis). Mustafa Kemal University Tayfur Ata Sokmen Faculty of Medicine, Department of Emergency Medicine, Hatay, 2017.
13. Aksel G, Antunok I, Corbacioglu SK, Akca HS, Bozan O, Kokulu K, Ozdemir S, Eroglu SE, Ozen C, Islam MM. Evaluation of the role of whole body computed tomography in the management of minor trauma patients. *J Contemp Med* 2021;11(6):883-8.
14. Yazici MM, Altuntas G. Whole-body computed tomography after major blunt trauma: is it necessary? *Fam Pract Palliat Care* 2023;8(2):30-5.
15. Asha S, Curtis KA, Hibe N, Taylor C, Lo S, Smart R, Compagnoni K. Comparison of radiation exposure of traumapatients from diagnostic radiology procedures before and after the introduction of a panscan protocol. *Emergency Medicine Australasia* 2012;24:43-51.
16. Gordic S, Alkadhi H, Hodel S, Simmen HP, Brueesch M, Frauenfelder T, Wanner G, Sprengel K. Whole-body CT-based imaging algorithm for multiple trauma patients: radiation dose and time to diagnosis. *British Journal of Radiology* 2015;88(1047):20140616.
17. Wada, D, Nakamori Y., Yamakawa K, Yoshikawa Y, Kiguchi T, Tasaki O, Ogura H, Kuwagata Y, Shimazu T, Hamasaki T, Fujimi S. Impact on survival of whole-body computed tomography before emergency bleeding control in patients with severe blunt trauma. *Crit Care* 2013;17:R178.
18. Baris MM, Canturk A, Karabay N. Retrospective analysis of head computed tomography investigations ordered by emergency department: Comparison of clinical pre-diagnosis and radiologic results. *J DEU Med* 2020;34(2):103-10.
19. Koksall O, Ozeren G, Yenice H, Cildir E. Is cranial computerized tomography really necessary for infants with minor head trauma? *JAEM* 2011;10:56-9.
20. Karatag O. Is computerized tomography in head injury patients sometimes unnecessary and excessive? (Oral Presentation) 3th International Conference on Awareness, 05-07 December 2019, Canakkale, Turkey.
21. Daglar B, Delialioglu OM, Ceyhan E, Ozdemir G, Tasbas BA, Bayrakci K, Gunel U. Superfluous computed tomography utilization for the evaluation of the pelvis and spinal column in an orthopedic emergency department. *Acta Orthop Traumatol Turc* 2008;42(1):59-63.
22. Durmus E, Guneyusu F. Evaluation of approaches of emergency physicians to computed tomography. *Klinik Tıp Bilimleri Derg* 2020;8(1):1-10.
23. Bingöl O. Retrospective analysis of whole-body multislice computed tomography findings taken in trauma patients. (Unpublished Thesis). Mersin University Faculty of Medicine, Department of Emergency Medicine, Mersin, 2014.
24. Selcuk H. Evaluation of missed radiological pathologies in multiple trauma patients with full-body computed tomography in the emergency department. (Unpublished Thesis). Dokuz Eylul University Faculty of Medicine, Department of Emergency Medicine, Izmir, 2020.
25. Deringoz M. Evaluation and comparison of the efficacy of three clinical decision tools in patients who received full body computed tomography due to trauma in the emergency department. (Unpublished Thesis). Dokuz Eylul University Faculty of Medicine, Department of Emergency Medicine, Izmir, 2020.
26. Reitano E, Granieri S, Sammartano F, Cimbanassi S, Galati M, Gupta S, Vanzulli A, Chiara O. Avoiding immediate whole body trauma CT: a prospective observational study in stable trauma patients. *Updates in Surgery* 2022;74:343-53.
27. Hakeri H. Medical Law Vol I [in Turkish]. Ankara: Seckin Publishing, 2022. p.593-609.
28. Tien HC, Tremblay LN, Rizoli SB, Gelberg J, Spencer F, Caldwell C, Brenneman FD. Radiation exposure from diagnostic imaging in severely injured trauma patients. *Journal of Trauma and Acute Care Surgery* 2007;62(1):151-6.