



# Investigation of Normalized Volume Ratios of Motor and Sensory Cortices on Magnetic Resonance Images in Parkinson's Disease Patients: An Automatic Brain Segmentation Study

Berna Dogan<sup>1</sup>, Mert Nahir<sup>1</sup>, Orhan Sumbul<sup>2</sup>

<sup>1</sup>Tokat Gaziosmanpaşa University, Faculty of Medicine, Department of Anatomy, Tokat, Türkiye

<sup>2</sup>Tokat Gaziosmanpaşa University, Faculty of Medicine, Department of Neurology, Tokat, Türkiye

Content of this journal is licensed under a Creative Commons Attribution-NonCommercial-NonDerivatives 4.0 International License.



## Abstract

**Aim:** This study evaluates structural changes in the normalized volume ratios of the motor and sensory cortices in Parkinson's patients and compares these changes with healthy individuals to assess the disease's impact on brain structure.

**Material and Method:** The study included 55 Parkinson's patients (14 females, 41 males) and 28 control subjects (7 females, 21 males). The volumes of the precentral gyrus, paracentral lobulus, and postcentral gyrus were calculated using the BrainSuite automated segmentation software. Regional gray matter volumes were normalized by dividing them by the intracranial volume, and these normalized values were used for comparisons. Volumetric analyses were conducted on the precentral gyrus, postcentral gyrus, and paracentral lobulus to assess their morphological changes associated with Parkinson's disease.

**Results:** Results: In the left hemisphere, the normalized gray matter volume ratios of the postcentral gyrus were found to be lower in Parkinson's patients ( $0.82\% \pm 0.09$ ) compared to the control group ( $0.88\% \pm 0.09$ ) ( $p < 0.05$ ). According to MANOVA analysis, significant differences were observed in the normalized gray matter volumes of the precentral gyrus (KEK=0.069,  $p=0.001$ ) and postcentral gyrus (KEK=0.300,  $p < 0.001$ ) concerning hemisphere and age variables. Significant differences were found in the precentral gyrus (KEK=0.034,  $p=0.019$ ) and paracentral lobule (KEK=0.026,  $p=0.041$ ) based on gender. In terms of group differences, a significant result was found in the postcentral gyrus (KEK=0.071,  $p=0.001$ ) when comparing Parkinson's disease patients and healthy controls, while no significant differences were observed in the precentral gyrus (KEK=0.011,  $p=0.193$ ) and paracentral lobule (KEK=0.000,  $p=0.792$ ).

**Conclusion:** Significant structural differences were identified in the normalized gray matter volumes of Parkinson's patients, specifically in the left postcentral gyrus, where a reduction in volume was observed compared to the control group. This study highlights the importance of normalization in accurately assessing volumetric differences and provides valuable insights into the structural changes associated with Parkinson's disease, contributing to the existing literature.

**Keywords:** Precentral gyrus, paracentral lobulus, postcentral gyrus, intracranial volume, BrainSuite

## INTRODUCTION

The primary motor cortex is located in the precentral gyrus region of the frontal lobe and plays a role in initiating voluntary movement. The motor cortex is connected to various structures, including the parietal lobe, premotor cortex, supplementary motor areas, basal ganglia, and cerebellum (1,2). It also receives afferent information from somatosensory, premotor and supplementary motor areas. On the other hand, the primary sensory cortex is located in the postcentral gyrus region of the parietal lobe and extends medially toward the paracentral lobule. This area

processes sensory inputs such as touch and pressure and is responsible for interpreting information from muscle spindles and joint position (3-5).

Parkinson's disease (PD) is a neurodegenerative disorder primarily characterized by motor symptoms such as tremors, rigidity, and bradykinesia (6,7). However, non-motor symptoms may also appear in the early stages of the disease. These symptoms include cognitive impairment, autonomic dysfunction, fatigue, and pain (8,9). Given the complex nature of PD, it is hypothesized that it may cause structural and functional changes throughout the

## CITATION

Dogan B, Nahir M, Sumbul O. Investigation of Normalized Volume Ratios of Motor and Sensory Cortices on Magnetic Resonance Images in Parkinson's Disease Patients: An Automatic Brain Segmentation Study. Med Records. 2025;7(1):245-50. DOI:1037990/medr.1594776

Received: 02.12.2024 Accepted: 06.01.2025 Published: 15.01.2025

Corresponding Author: Mert Nahir, Tokat Gaziosmanpaşa University, Faculty of Medicine, Department of Anatomy, Tokat, Türkiye

E-mail: mert.nahir@gmail.com

brain. Within this framework, it is thought that sensory dysfunctions may also be associated with motor function impairments (10). The gait and balance disturbances observed in PD are believed to be due to feedback from proprioceptive sensory systems.

Brain volume values are influenced by gender, head size, and other anatomical variations among individuals (11). Therefore, these values must be evaluated relative to a fixed reference value to enable accurate comparisons of volume values. This process is called normalization, a commonly used method in brain volume analyses (12,13). Specifically, the ratio of gray matter volumes to intracranial cavity volume (ICV) allows for an objective and comparable assessment of group volume differences (14).

The primary aim of this study is to examine the normalized gray matter volume ratios in the precentral gyrus, postcentral gyrus, and paracentral lobule of Parkinson's patients and to contribute to a more consistent and objective evaluation of volumetric data.

## MATERIAL AND METHOD

### Study Participants and Imaging Data

This study was initiated with the approval of the Non-Interventional Clinical Research Ethics Committee of Tokat Gaziosmanpaşa University Faculty of Medicine (approval number: 83116987-327). For the patient group, magnetic resonance (MR) images of patients diagnosed with Parkinson's disease based on neurological examination at the neurology department were used. Patients with a history of head trauma, brain surgery, trauma, or pathological conditions were excluded from the study. The healthy control group consisted of individuals who visited the hospital for various reasons, underwent MR imaging as part of routine examinations, and had no neurological diagnoses. The images were retrospectively reviewed through the faculty's patient follow-up system. Five MR images from the patient group and two MR images from the control group were excluded due to imaging artifacts. A total of 83 MR images, including 55 from the Parkinson's patient group and 28 from the control group, were included in the study.

### Image Processing

MR images were acquired using a Philips Medical Systems 3.0 T Gyroscan NT MRI scanner. The images had the following specifications: voxel size of 1 mm x 1 mm x 1 mm, TR=8.1 ms, TE=3.7 ms, TFE=230 ms, flip angle=8°, matrix size of 224 x 224 pixels, and a field of view (FOV) of 224x224 cm. The acquired image series were selected as three-dimensional sagittal plane slices and transferred to the Horos program (V4.3.1) in Digital Imaging and Communications in Medicine (DICOM) format. Subsequently, the image voxel depth series, width, and height were adjusted to 1 mm using the ImageJ program. With a slice thickness of 1 mm, these image series were rotated 90 degrees to create a new axial image series. The obtained axial image series were saved in Analyze 7.5

format and reprocessed for use in the BrainSuite program. Finally, the automatic segmentation of MR images was performed using the BrainSuite software.

### Automatic Segmentation Method: BrainSuite

In the BrainSuite program, the "cortical surface extraction sequence" was selected under the "cortex" menu for cortical surface area extraction. The "skull stripping" step, the initial and fundamental phase of the analysis, involved separating the cranium and meningeal tissues and defining the boundaries of the cerebrum (Figure 1). For image series where the boundaries of the cerebrum were not fully enclosed, adjustments were made in the diffusion constant, edge constant, and erosion size tabs. After the cerebrum boundaries were defined correctly, the analysis proceeded, and the remaining steps were performed automatically. The mask.nii.gz file, in which the cranium boundaries were determined by excluding other structures, was saved in a separate folder to calculate the ICV. Once the analysis was completed, the total volumes of the brain, hemispheres, cortical and subcortical regions, gray and white matter volumes, cortical surface area, and cortical thickness values were automatically saved as a "roiwise\_stats" file in the BrainSuite program.

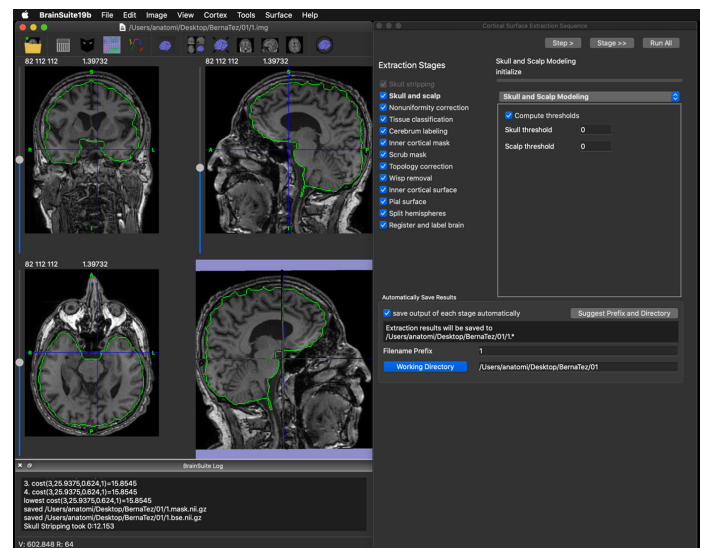


Figure 1. The initial phase of the BrainSuite program

### Measurement of Intracranial Volume Using ImageJ Software and the Cavalieri Principle

ICV was measured using the ImageJ software (version 1.52a) and the "mask.nii.gz" file generated by the BrainSuite program. First, DICOM files were converted into a 16-bit image stack using the "Convert Images to Stack" function under the "Stacks" submenu. Then, a threshold value was applied to convert the images into a binary image that matched the original image.

Next, the ICV was manually defined as the region of interest (ROI) for each boundary using the "Polygon Selection Tool" under the "Analyze > Tools" menu. Each slice of the ROI was added to the ROI manager using the "Add" function, and the area of each ROI was calculated using the "Measure" function in the ROI manager menu.

The wand tool was used to measure the cross-sectional area of the ROI, and the software automatically measured the cross-sectional area. The ICV was calculated using the Cavalieri principle, which multiplies the total cross-sectional surface area by the slice thickness and cortical thickness.

To obtain the ICV, the sum of the areas of all ROIs (mm<sup>2</sup>) was multiplied by the slice thickness (mm), yielding the ICV (mm<sup>3</sup>).

### Statistical Analysis

The statistical analysis of volumetric and demographic data obtained from the study was performed using SPSS (Statistical Package for the Social Sciences, version 25) software. Descriptive statistics of the data were presented with parameters such as numbers (n), means, and standard

deviations (SD). For comparisons between groups, the normality distribution of the data was assessed using the Kolmogorov-Smirnov test. The independent samples t-test was used for data that met the normality assumption, while the Mann-Whitney U test was preferred for data that did not meet the normality assumption. Normalized volume data were analyzed using multivariate analysis of variance (MANOVA) to examine factors such as group, region (right/left), group and region interaction, gender, and age. A p-value of <0.05 was considered statistically significant.

### RESULTS

A total of 83 participants were included in this study, consisting of 55 Parkinson's patients and 28 healthy controls. The age, number of subjects, cerebral and ICV volumes are listed in Table 1.

**Table 1. Demographic characteristics, cerebral volume, and ICV of Parkinson patients and controls**

	Parkinson patients	Controls
Subject number (n)	55	28
Age (years)	61.63±10.07	60.89±10.43
Sex (F/M) (n)	14/41	7/21
Cerebral volume (right/left)	229.18±20.6/227.6±19.1	231.55±21.9/229.00±20.5
ICV (cm <sup>3</sup> )	1520.17±124.8	1485.44±121.1

F/M: female/male, ICV: intracranial volume

The gray matter volume of the precentral gyrus in the right hemisphere of Parkinson's patients was 11.41±1.49 cm<sup>3</sup>, compared to 11.67±1.45 cm<sup>3</sup> in the control group. In the left hemisphere, it was 10.97±1.37 cm<sup>3</sup> for Parkinson's patients and 10.80±1.39 cm<sup>3</sup> for controls. The volumes of the precentral gyrus in both hemispheres showed no significant differences between the Parkinson's patients and the control group (p>0.05). The paracentral lobule volumes in

Parkinson's patients were 3.97±0.61 cm<sup>3</sup> and 3.84±0.56 cm<sup>3</sup>, compared to 3.81±0.55 cm<sup>3</sup> and 3.82±0.62 cm<sup>3</sup> in the control group; these differences were not significant (p>0.05). Similarly, the gray matter volumes of the postcentral gyrus were 10.74±1.73 cm<sup>3</sup> and 12.43±1.65 cm<sup>3</sup> in Parkinson's patients, versus 11.18±1.40 cm<sup>3</sup> and 13.09±1.51 cm<sup>3</sup> in the control group, also showing no significant differences (p>0.05). All results are presented in Table 2.

**Table 2. Comparison of gray matter volumes in motor and sensory cortices between parkinson patients and controls**

Side	Region	Gray matter volume (cm <sup>3</sup> )		P
		Parkinson patients (mean±SD)	Controls (mean±SD)	
Right	<b>Precentral gyrus</b>	11.41±1.49	11.67±1.45	0.45
	<b>Paracentral lobule</b>	3.97±0.61	3.81±0.55	0.44
	<b>Postcentral gyrus</b>	10.74±1.73	11.18±1.40	0.24
Left	<b>Precentral gyrus</b>	10.97±1.37	10.80±1.39	0.60
	<b>Paracentral lobule</b>	3.84±0.56	3.82±0.62	0.87
	<b>Postcentral gyrus</b>	12.43±1.65	13.09±1.51	0.08

SD: standard deviation; the parts determined in bold are statistically significant (p<0.05)

In Parkinson's patients, the normalized gray matter ratios of the precentral gyrus were 0.75%±0.09 in the right hemisphere and 0.72%±0.09 in the left, compared to 0.79%±0.08 and 0.73%±0.08 in the control group, respectively. Statistical analysis showed no significant differences between the groups for these measurements (p>0.05). For the paracentral lobule, the gray matter ratios in both hemispheres of Parkinson's patients were consistently 0.26%±0.03, compared to 0.25%±0.03 in the

right and 0.26%±0.04 in the left hemisphere of the control group, with no significant differences observed (p>0.05). However, in the postcentral gyrus, Parkinson's patients had gray matter ratios of 0.71%±0.11 in the right hemisphere and 0.82%±0.09 in the left, whereas the control group had ratios of 0.75%±0.08 and 0.88%±0.09, respectively. The significant difference was noted only in the left hemisphere, where the gray matter ratio was lower in Parkinson's patients compared to controls (p<0.05). These findings are detailed in Table 3.

**Table 3. Comparison of normalized gray matter volumes in motor and sensory cortices between parkinson's patients and healthy controls**

Side	Region	Gray matter volume/ICV (%)		p
		Parkinson patients (mean±SD)	Controls (mean±SD)	
Right	<b>Precentral gyrus</b>	0.75±0.09	0.79±0.08	0.07
	<b>Paracentral lobule</b>	0.26±0.03	0.25±0.03	0.90
	<b>Postcentral gyrus</b>	0.71±0.11	0.75±0.08	0.05
Left	<b>Precentral gyrus</b>	0.72±0.09	0.73±0.08	0.79
	<b>Paracentral lobule</b>	0.26±0.03	0.26±0.04	0.58
	<b>Postcentral gyrus</b>	0.82±0.09	0.88±0.09	<b>0.003</b>

SD: standard deviation; the parts determined in bold are statistically significant (p<0.05); ICV: intracranial volume

There were no statistically significant differences in the normalized gray matter volumes of the precentral gyrus (p=0.193) and paracentral lobule (p=0.792) between groups. However, significant differences were found in the postcentral gyrus (p=0.001). A significant difference was observed in the hemisphere effect for both the precentral gyrus (p=0.001) and the postcentral gyrus (p<0.001), but not for the paracentral lobule (p=0.663). The interaction between group and hemisphere did not show significant effects on the gray matter volumes across the tested regions (precentral gyrus, p=0.219; paracentral lobule, p=0.663; postcentral gyrus, p=0.513). Significant gender

differences were observed in the gray matter volumes of the precentral gyrus (p=0.019) and the paracentral lobule (p=0.041), but not in the postcentral gyrus (p=0.971). This reveals that gender may influence gray matter volumes in specific brain regions. Age showed significant effects on the gray matter volumes in the precentral and postcentral gyrus (p<0.001 for both), but not in the paracentral lobule (p=0.529). The details of the MANOVA analysis presented in Table 4 explore the normalized gray matter volumes in motor and sensory brain regions, specifically examining factors such as group differences, hemisphere, group-hemisphere interactions, gender, and age.

**Table 4. MANOVA analysis results of normalized gray matter volumes in motor and sensory brain regions**

		Gray matter volume/ICV (%)		
		Precentral gyrus <sup>1</sup>	Paracentral lobule <sup>2</sup>	Postcentral gyrus <sup>3</sup>
Group	p	0.193	0.792	<b>0.001</b>
	KEK	0.011	0.000	0.071
Hemisphere (Right/left)	p	<b>0.001</b>	0.663	<b>&lt;0.001</b>
	KEK	0.069	0.001	0.300
Group hemisphere (Interaction)	p	0.219	0.663	0.513
	KEK	0.009	0.001	0.003
Gender	p	<b>0.019</b>	<b>0.041</b>	0.971
	KEK	0.034	0.026	0.001
Age	p	<b>&lt;0.001</b>	0.529	<b>&lt;0.001</b>
	KEK	0.182	0.002	0.123

The parts determined in bold are statistically significant (p<0.05); ICV: intracranial volume; KEK: Wilks' Lambda; <sup>1</sup>R Squared: .241 (Adjusted R Squared: .217); <sup>2</sup>R Squared: .030 (Adjusted R Squared: .000); <sup>3</sup>R Squared: .411 (Adjusted R Squared: .392)

## DISCUSSION

Our study revealed no significant difference in the gray matter volume of the motor cortex in Parkinson's patients compared to the control group. This finding is consistent with the study by Brenneis et al., which reported no difference in the motor cortex gray matter volume in Parkinson's patients and suggested that the gray matter damage in this region may be attributed to functional impairments rather than structural changes (15). This explanation supports the findings of our study. However, some studies report reduced precentral gyrus volume in Parkinson's patients (16-18). The precentral gyrus serves as the origin of the pyramidal tract. Shao et al. stated that damage in this region could partially contribute to motor

impairments in Parkinson's patients (19). The complex and variable clinical manifestations of Parkinson's disease and differences in clinical data among studies may explain the diversity of such results.

On the other hand, the study by Zhi Yan et al. presents a contrasting finding. When comparing Parkinson's patients with and without dyskinetic syndrome to a healthy control group, they reported that the precentral gyrus gray matter volume was higher in Parkinson's patients. It was suggested that this increase might explain the neurological mechanisms underlying dyskinetic syndromes in Parkinson's patients treated with medication (20). In contrast, studies by Kang and Tian et al. reported reduced gray matter volume in the precentral gyrus of

Parkinson's patients compared to controls using voxel-based morphometric analyses (21,22). We believe these methodological differences could be a significant reason for the discrepancies between our study's findings and those of previous research.

Our findings regarding the sensory cortex, particularly in the postcentral gyrus, demonstrate that the ICV-normalized gray matter volume ratios were reduced compared to the control group. This result is consistent with the study by Xia et al., which reported decreased gray matter volume in the left postcentral gyrus of Parkinson's patients (23). It has been suggested that these reductions in the sensory cortex may impair the functions of the associated brain regions. Other studies indicate that such reductions may result from neuronal loss due to the shrinkage of large neurons or rarefaction of microvascular structures (24,25). However, Piguet et al. proposed that age-related changes in the brain are more pronounced in white matter than in gray matter (26). In light of this information, our study's observed reduction in gray matter volume in the sensory cortex is likely associated with the neurodegenerative effects of Parkinson's disease rather than the aging process.

ICV is a crucial variable influenced by factors such as gender and body size. It shows a rapid increase from birth, particularly during the first five years, and stabilizes between the ages of 16 and 20. It is assumed that ICV remains constant throughout life, even in the presence of brain atrophy (27-29). Due to the challenges posed by factors like age, gender, and body size in comparing brain atrophy among individuals, normalization is emphasized as a crucial step in such studies. Crowley et al. highlighted that volume data should be analyzed independently of age, gender, and ICV variables and argued that neglecting these factors in Parkinson's patients leads to complex results. In volumetric studies conducted on Parkinson's patients, results have shown significant variability when ICV is not controlled (30). Barnes et al. demonstrated that voxel-based morphometric analyses are influenced by age, gender, and head size (31). Studies that accounted for these variables reported reduced differences between groups (32-34), whereas studies that did not control these variables reported large discrepancies (35-37). Some studies have reported that ICV is larger in Parkinson's patients compared to control groups, potentially due to genetic variations (38). Additionally, normalization using ICV has been shown to correct differences arising from individual variations in head size. It allows for a more accurate assessment of clinical changes, such as brain atrophy. It has also been noted that raw volumes positively correlate with ICV, but when volumes are normalized to TIV, this relationship is reversed (30). Therefore, considering TIV is critical for obtaining more accurate and consistent results, especially in neurodegenerative diseases.

The findings of our study provide important insights into the understanding of the sensorimotor relationship between the motor and sensory cortices. The lack of a significant

difference in the motor cortex suggests that structural changes in the sensory cortex may indirectly influence motor functions. Identifying a significant difference in the sensory cortex following the application of normalization methods highlights the critical importance of considering individual biological variability.

This study has certain limitations. The gender imbalance in the sample size may limit the generalizability of the findings. Additionally, the lack of clinical data made directly correlating structural changes in gray matter volume with motor and sensory symptoms difficult. Future studies should include larger sample groups and different stages of the disease to evaluate the clinical implications of gray matter changes. Furthermore, examining white matter changes and functional connectivity may contribute to a better understanding of the interactions between the motor and sensory systems during the disease process.

## CONCLUSION

In conclusion, our study emphasizes the importance of methodological approaches, such as ICV normalization, in evaluating gray matter changes in the motor and sensory cortices in Parkinson's disease. We believe the findings provide valuable contributions to the literature by enhancing the understanding of the structural and functional relationships of the sensorimotor system in Parkinson's disease.

**Financial disclosures:** The authors declared that this study has received no financial support.

**Conflict of interest:** The authors have no conflicts of interest to declare.

**Ethical approval:** The study protocol was approved by Non-Interventional Ethics Committee of Gaziosmanpaşa University, Faculty of Medicine (approval number: 83116987-327).

## REFERENCES

- Shareef S, Ali T, Sahin B, et al. Structural alteration of motor and sensory cortices in Parkinson's disease using magnetic resonance imaging: automatic brain segmentation. *International Journal of Advanced and Applied Sciences*. 2018;5:101-9.
- Yoshida J, Oñate M, Khatami L, et al. Cerebellar contributions to the basal ganglia influence motor coordination, reward processing, and movement vigor. *J Neurosci*. 2022;42:8406-15.
- Darainy M, Manning TF, Ostry DJ. Disruption of somatosensory cortex impairs motor learning and retention. *J Neurophysiol*. 2023;130:1521-8.
- Gale DJ, Flanagan JR, Gallivan JP. Human somatosensory cortex is modulated during motor planning. *J Neurosci*. 2021;41:5909-22.
- Nakajima T, Hosaka R, Mushiake H. Complementary roles of primate dorsal premotor and pre-supplementary motor areas to the control of motor sequences. *J Neurosci*. 2022;42:6946-65.
- Andica C, Kamagata K, Hatano T, et al. Neurocognitive and psychiatric disorders-related axonal degeneration in Parkinson's disease. *J Neurosci Res*. 2020;98:936-49.

7. Kumar S, Goyal L, Singh S. Tremor and rigidity in patients with Parkinson's disease: emphasis on epidemiology, pathophysiology and contributing factors. *CNS Neurol Disord Drug Targets*. 2022;21:596-609.
8. Biundo R, Formento-Dojot P, Facchini S, et al. Brain volume changes in Parkinson's disease and their relationship with cognitive and behavioural abnormalities. *J Neurol Sci*. 2011;310:64-9.
9. Marinova D, Danovska M. The non-motor symptoms—challenge in diagnosis of Parkinson's Disease. *J of IMAB*. 2020;26:3469-74.
10. Permezel F, Alty J, Harding IH, Thyagarajan D. Brain networks involved in sensory perception in Parkinson's disease: a scoping review. *Brain Sci*. 2023;13:1552.
11. Voevodskaya O, Simmons A, Nordenskjöld R, et al. The effects of intracranial volume adjustment approaches on multiple regional MRI volumes in healthy aging and Alzheimer's disease. *Front Aging Neurosci*. 2014;6:264.
12. Borghammer P, Jonsdottir KY, Cumming P, et al. Normalization in PET group comparison studies—the importance of a valid reference region. *Neuroimage*. 2008;40:529-40.
13. Dhamala E, Ooi LQR, Chen J, et al. Proportional intracranial volume correction differentially biases behavioral predictions across neuroanatomical features, sexes, and development. *Neuroimage*. 2022;260:119485.
14. Sanfilippo MP, Benedict RH, Zivadinov R, Bakshi R. Correction for intracranial volume in analysis of whole brain atrophy in multiple sclerosis: the proportion vs. residual method. *Neuroimage*. 2004;22:1732-43.
15. Brenneis C, Seppi K, Schocke MF, et al. Voxel-based morphometry detects cortical atrophy in the Parkinson variant of multiple system atrophy. *Mov Disord*. 2003;18:1132-8.
16. Goldman JG, Stebbins GT, Dinh V, et al. Visuoperceptive region atrophy independent of cognitive status in patients with Parkinson's disease with hallucinations. *Brain*. 2014;137:849-59.
17. González-Redondo R, García-García D, Clavero P, et al. Grey matter hypometabolism and atrophy in Parkinson's disease with cognitive impairment: a two-step process. *Brain*. 2014;137:2356-67.
18. Kostic VS, Agosta F, Pievani M, et al. Pattern of brain tissue loss associated with freezing of gait in Parkinson disease. *Neurology*. 2012;78:409-16.
19. Shao N, Yang J, Li J, Shang HF. Voxelwise meta-analysis of gray matter anomalies in progressive supranuclear palsy and Parkinson's disease using anatomic likelihood estimation. *Front Hum Neurosci*. 2014;8:63.
20. Zhi Y, Wang M, Yuan YS, et al. The increased gray matter volumes of precentral gyri in Parkinson's disease patients with diphasic dyskinesia. *Aging (Albany NY)*. 2019;11:9661-71.
21. Kang D, Chen F, Wang F, et al. Brain gray matter volume changes associated with motor symptoms in patients with Parkinson's disease. *Chin Neurosurg J*. 2015;1:9.
22. Zhai H, Fan W, Xiao Y, et al. Voxel-based morphometry of grey matter structures in Parkinson's Disease with wearing-off. *Brain Imaging Behav*. 2023;17:725-37.
23. Xia J, Wang J, Tian W, et al. Magnetic resonance morphometry of the loss of gray matter volume in Parkinson's disease patients. *Neural Regen Res*. 2013;8:2557-65.
24. Peters A, Morrison JH, Rosene DL, Hyman BT. Feature article: are neurons lost from the primate cerebral cortex during normal aging?. *Cereb Cortex*. 1998;8:295-300.
25. Riddle DR, Sonntag WE, Lichtenwalner RJ. Microvascular plasticity in aging. *Ageing Res Rev*. 2003;2:149-68.
26. Piguet O, Double KL, Kril JJ, et al. White matter loss in healthy ageing: a postmortem analysis. *Neurobiol Aging*. 2009;30:1288-95.
27. Knutson B, Momenan R, Rawlings RR, et al. Negative association of neuroticism with brain volume ratio in healthy humans. *Biol Psychiatry*. 2001;50:685-90.
28. Sgouros S, Goldin JH, Hockley AD, et al. Intracranial volume change in childhood. *J Neurosurg*. 1999;91:610-6.
29. Wolf H, Kruggel F, Hensel A, et al. The relationship between head size and intracranial volume in elderly subjects. *Brain Res*. 2003;973:74-80.
30. Crowley S, Huang H, Tanner J, et al. Considering total intracranial volume and other nuisance variables in brain voxel based morphometry in idiopathic PD. *Brain Imaging and Behavior*. 2018;12:1-12. Erratum in: *Brain Imaging Behav*. 2018;12:613.
31. Barnes J, Ridgway GR, Bartlett J, et al. Head size, age and gender adjustment in MRI studies: a necessary nuisance?. *Neuroimage*. 2010;53:1244-55.
32. Agosta F, Canu E, Stojković T, et al. The topography of brain damage at different stages of Parkinson's disease. *Hum Brain Mapp*. 2013;34:2798-807.
33. Burton EJ, McKeith IG, Burn DJ, et al. Cerebral atrophy in Parkinson's disease with and without dementia: a comparison with Alzheimer's disease, dementia with Lewy bodies and controls. *Brain*. 2004;127:791-800.
34. Planetta PJ, Kurani AS, Shukla P, et al. Distinct functional and macrostructural brain changes in Parkinson's disease and multiple system atrophy. *Hum Brain Mapp*. 2015;36:1165-79.
35. Lee EY, Sen S, Eslinger PJ, et al. Early cortical gray matter loss and cognitive correlates in non-demented Parkinson's patients. *Parkinsonism Relat Disord*. 2013;19:1088-93.
36. Lin CH, Chen CM, Lu MK, et al. VBM reveals brain volume differences between Parkinson's disease and essential tremor patients. *Front Hum Neurosci*. 2013;7:247.
37. Summerfield C, Junqué C, Tolosa E, et al. Structural brain changes in Parkinson disease with dementia: a voxel-based morphometry study. *Arch Neurol*. 2005;62:281-5.
38. Taal HR, Pourcain BS, Thiering E, et al. Common variants at 12q15 and 12q24 are associated with infant head circumference. *Nat Genet*. 2012;44:532-8.