



Özgün Araştırma / Original Article

The efficacy of adalimumab in the treatment of hidradenitis suppurativa

Ali Balevi¹, Pelin Ustuner², Mustafa Özdemir³

1 Pelin Üstüner, Istanbul Medipol University Medical Faculty, Dermatology Department, Istanbul, Turkey ORCID: 0000-0002-7885-0537

2 Ali Balevi, Istanbul Medipol University Medical Faculty, Dermatology Department, Istanbul, Turkey ORCID: 0000-0001-5057-0405

3 Mustafa Özdemir, Istanbul Medipol University Medical Faculty, Dermatology Department, Istanbul, Turkey ORCID: 0000-0002-7022-913X

Received: 10.08.2017; Revised: 15.12.2017; Accepted: 28.12.2017

Abstract

Objectives: Hidradenitis suppurativa is seen as a result of the occlusion, constriction and bacterial infection of the apocrine glands in bilateral axillas, submammary areas, neck, inguinal regions, flexural surfaces of the thighs and anogenital areas. Among the biological agents adalimumab is a recombinant human IgG1 monoclonal antibody; TNF- α antagonist approved to be used in the treatment of hidradenitis suppurativa.

Methods: In this study, 12 patients resistant to conventional treatments with moderate severity, Hurley stage 2 or 3 were started subcutaneous adalimumab treatment. The disease activities upon the hidradenitis suppurativa, clinical severity index and life quality index of the patients were examined both before and 1 year after the treatment.

Results: Twelve patients were recruited. In the examination of the hidradenitis suppurativa clinical severity scores, significant clinical responses were noted in 9 (75%) patients. While the mean value of the life quality index was 14.4 ± 6.9 before the treatment, it was determined to be significantly decreased to 4.3 ± 3.8 after the treatment.

Conclusion: We concluded that adalimumab; the unique biological agent approved to be used in the treatment of treatment-resistant, moderate-severe hidradenitis suppurativa is efficient and safe in similar ratios with the previous clinical studies in the literature.

Keywords: Adalimumab, eccrine glands, hidradenitis

DOI: 10.5798/dicletip.407240

Yazışma Adresi / Correspondence: Pelin Ustuner, Istanbul Medipol University, School of Medicine, Department of Dermatology TEM Avrupa Otoyolu Göztepe Çıkışı No: 1 Bağcılar 34214 İstanbul, Turkey e-mail: pelindogaustuner@gmail.com

Hidradenitissüpürativa tedavisinde adalimumabın etkinliği

Özet

Amaç: Hidradenitis suppurativa; her iki koltuk altı, göğüs altları, boyun, kasıklar, bacakların birbirine sürten yüzünde ve anogenital bölgelerde apokrin bez kanalında tıkanma, daralma ve bakteriyel enfeksiyon sonucu görülmektedir.

Biyolojik ajanlar arasında adalimumab; hidradenitis süpürativa tedavisinde kullanımı onaylanmış TNF- α antagonisti rekombinant insan IgG1 monoklonal antikoruudur.

Yöntemler: Bu çalışmada klasik tedavilere dirençli, orta-şiddetli tutulumlu, Hurley stage 2 veya 3, klasik tedavilere direnç/yetersizlik olan 12 hastaya adalimumab tedavisi uygulandı. Hastaların tedavi öncesi ve 1 yıllık tedavi sonrası hidradenitis süpürativa klinik şiddet indeksine göre hastalık aktiviteleri ve yaşam kalite indeksleri incelendi.

Bulgular: Oniki hasta çalışmaya alındı. 7 hastada Hurley 3, geriye kalan 5 hastada Hurley 2 seviyesinde tutulum mevcuttu. Hidradenitis süpürativa klinik şiddet skorlaması incelendiğinde 9 hastada (%75) anlamlı klinik yanıt tespit edildi. Tedavi öncesi yaşam kalite indeksi ortalamasının 14.4 ± 6.9 iken, tedavi sonrası anlamlı oranda gerileyerek 4.3 ± 3.8 'a düştüğü saptandı.

Sonuç: Tedaviye dirençli orta-şiddetli hidradenitis süpürativa tedavisinde kullanımı onay almış tek biyolojik ajan olan adalimumabın literatürdeki önceki klinik çalışmalarla benzer oranda etkin ve güvenilir olduğu sonucuna vardık.

Anahtar kelimeler: Adalimumab, ektrin ter bezleri, hidradenit

INTRODUCTION

Hidradenitis suppurativa (HS) is a chronic, recurrent, inflammatory disease of the apocrine glands. The prevalence of HS is not known, but according to the epidemiological studies the disease has been reported in 0.05-0.2% of the population. The disease is seen in nearly 4% of the young adult females. Hidradenitis suppurativa is diagnosed according to the clinical signs. In the etiopathogenesis; follicular hyperkeratosis initiates that the disease is followed by the follicular occlusion and apocrine glands participate secondarily¹. Comedones, inflammatory/non-inflammatory nodules, sinus tracts and abscess forming scars are commonly seen. These lesions occur in axillary, inguinal, pubic, gluteal areas and in submammary areas in females. For the definite diagnosis the development of these painful and purulent nodules should be seen at least for 2 times in 6 months. The disease usually starts at the age of twenties after the puberty².

Up to now; lots of different treatments have been recommended for the treatment of HS and no medical cure is present. Different treatment options are planned simultaneously and

combined with surgery. Topical and systemic antibiotics, dapsone, systemic/intralesional corticosteroids, immunosuppressives (azathiopurine, methotrexate, cyclosporine), colchicine, retinoids, hormonal treatment and biologic agents (adalimumab, infliximab, etc) are some of the medical treatment options³.

In the lesional skin areas of patients with HS the increase in the levels of lots of cytokines such as; tumour necrosis factor (TNF- α), interleukin (IL)-12, IL-23, IL-10 and IL-17 has been shown. Up to now, of the biologicals; infliximab and adalimumab have been reported to have efficacy in the treatment of HS. Adalimumab, TNF- α antagonist; recombinant monoclonal IgG1 antibody blocks the TNF 1 and 2 receptors (p55 and p75, respectively) on the cellular surface and avoids the production of cytokines that provides the enhancement of inflammatory cascade⁴. Adalimumab is a systemic agent that has been approved by FDA for the treatment of moderate and severe HS. Significant clinical improvement has been reported with adalimumab in HS lesions. However, variable clinical results exist about the treatment duration, clinical response rates and remission rates of biological agents

including adalimumab. Herein, in this study we aimed to assess the efficacy of adalimumab in HS patients.

METHODS

Our study was performed retrospectively by the investigation of the polyclinic records of the patients treated with adalimumab for HS between 2014 and 2016 in our University Medical Faculty Dermatology Clinic. Whether or not the patients were diagnosed with HS was recorded from the medical records and via mobile questionnaires.

The records of the patients about the age, sex, body mass index, smoking habits, disease duration, family history, previous treatments, comorbidities, localization of the lesions and informations about treatments were examined. The HS clinical stages of the patients were recorded. According to this; stage 1- solitary or multiple abscess formation, and absence of an accompanying scar or sinus tract, stage 2- in the presence of recurrent abscess, the presence of sinus tracts accompanying with solitary or multiple generalized lesions, stage 3- the presence of multiple, interconnected sinus tracts and abscess that accompany with diffuse or generalized involvement areas.

We observed that adalimumab treatment have been started to the patients with moderate, Hurley stage 2 or 3 HS, resistant to conventional treatments. The treatment has been given subcutaneously in 160mg in week 0, 80mg in week 2 and 4 and in 40 mg per week there after. We noted that the treatment was continued for a minimum time of 1 year.

Patients were followed up with the intervals of 2 weeks to 3 months. In the follow up visits; clinical scores, possible adverse effects due to their treatments and laboratory results were recorded. The clinical activities of the patients were assessed according to HS clinical severity index (HISCR) scores. HISCR response was identified as; a 50% decrease in the number of the inflammatory lesions (abscess +

inflammatory nodule) and not showing an increase in the number of the abscess and draining fistules compared to the pre-treatment⁵. According to this, the treatment responses were recorded as HISCR+/- from the patient records. In our study we accepted the treatment response lower than 50% as; “unresponsive to treatment” and the occasion of unresponsiveness to 12 weeks of treatment as; “treatment resistant”. The dermatology quality of life index (DLQI) were also recorded.

Statistical Analysis

In our study for the dual comparison of qualitative data, in circumstances of abnormal distributed variables Mann Whitney U test and in dual comparison of quantitative data Pearson ki-square test was used. $p < 0.01$ and $p < 0.05$ were accepted as statistically significant.

RESULTS

Demographic data

The clinical records of 32-60 years old twelve patients (11 males, 1 female) diagnosed with HS were analysed retrospectively. The initiation of the disease was at the age of 25 ± 11 SD years (range 13-51). The mean disease duration was 5 ± 0.4 SD years (range 1-12). Family history was not noted in any of the patients. Smoking habit was present in seven patients (58.3%). The body mass index (VKI) was $29,5 \pm 5,9$ SD (range 21-38). Upon the comorbite diseases we observed; diabetes mellitus; in 4 patients (33%), psoriasis; in 1 patient, pilonoidal sinus; in 1 patient and metabolic syndrome; in 1 patient (8.3%).

Before adalimumab treatment; we ascertained the fact that all of the patients had been previously treated with topical and systemic antibiotics (doxycycline, trimethoprim/sulfamethoxazol, fusidic acid). In addition to this; we noted that in 8 patients; systemic isotretinoin (for 6 months), in 2 patients; systemic steroid (10-40 mg/day

prednisolone for 2-6 weeks), isotretinoin for 6 months and if needed (for 1-3 months) systemic doxycycline, trimethoprim/sulfamethoxazole, clindamycin, rifampicin and topical clindamycin, rifampicin were used in combination or seperately. We also noted that 8 of the 12 patients (66%) had previously used systemic isotretinoin (Table 1). Of the remaining 4 patients; 3 refused the use of systemic isotretinoin and 1 had been unable to use it due to the presence of metabolic

syndrome. Moreover, one patient was given topical tretinoin.

Of the patients used systemic steroid 2 patients were HISCR- (unresponsive) and of the 8 patients used systemic isotretinoin; 3 patients were HISCR+ in month 3, but had recurrence in month 6. We also recorded that at the end of the sixth month 12 patients were HISCR- (unresponsive) to the medical treatments (Table 1).

Table 1: Clinic and demographic data of 12 patients recruited to study.

Patient number	Gender	Age	Involvement site(s) Axilla:1 Inguinal:2 Chest:3 Perineal:4 Perianal:5 Submammarian:6 Penil: 7	Previous treatments	Previous treatment duration (Month)	Reponse to previous treatments (3. Month)	Reponse to previous treatments (6. Month)	Hurley stage (before adalimumab)	Hurley stage (after adalimumab)	Side effects of Adalimumab treatment
1	M	27	1,2	AB	4	HISCR-	-	3	2	-
2	M	53	1,2	SCS, SIT, AB	6	HISCR-	HISCR-	3	2	Upper respiratory infection
3	M	32	1,2,3	AB, TT	3	HISCR-	-	3	2	-
4	M	27	1,2	AB, SIT	6	HISCR+	HISCR-	2	1	-
5	M	25	1,2	AB, SIT	6	HISCR-	HISCR-	3	2	Upper respiratory infection
6	F	34	1,2,3	AB	6	HISCR-	HISCR-	3	2	-
7	M	26	1,2	AB, SIT	6	HISCR-	HISCR-	2	2	-
8	M	44	1,2	SCS, SIT, AB	6	HISCR-	HISCR-	2	1	Upper respiratory infection
9	M	26	1, 2, 3	AB	3	HISCR-	-	3	2	-
10	M	34	6	AB, SIT	6	HISCR+	HISCR-	3	2	-
11	M	28	4,5	AB, SIT	6	HISCR-	HISCR-	2	2	-
12	M	23	7	AB, SIT	6	HISCR+	HISCR-	2	2	-

AB;Antibiotic, SIT;SystemicIsotretinoin,TT; Topical Tretinoin,SCS; Systemic Corticosteroid

Dermatologic involvement

Before the treatment involvement of Hurley stage 3 were seen in 7 patients, and Hurley stage 2 were observed in remaining 5 patients (Table 1). In all patients at least one or more inflammatory nodules and involvement of 2 or more anatomic areas were observed. The presence of abscess, sinus tracts and atrophic or hypertrophic scars were detected. Axillary and inguinal regions; in 9 patients (75%), chest; in 3 patients (%25), perineal or perianal areas; in 1 patient (8%), submammary area; in 1 patient (8%) and penil area; in 1 patient (8%) were involved (Table 1). The clinical photograph of a patient having an involvement of Hurley stage 3, subcutaneous abscess formation in right axillary area, fistula with two openings and an atrophic scar areas given in Figure 1.

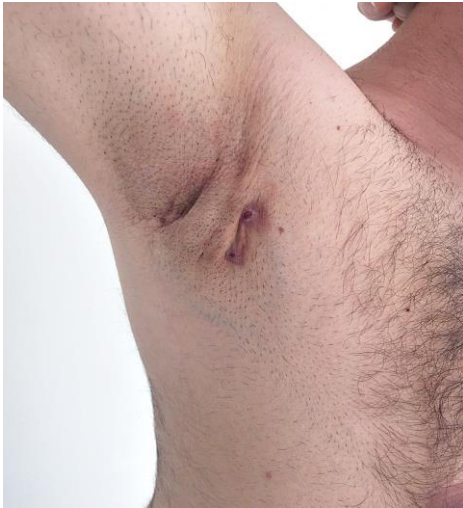

Figure 1. The subcutaneous abscess formation on the right axillary area accompanied with fistula with two openings and atrophic scar tissue before the adalimumab treatment

patient had clinical improvement in abscess lesions in month 3 (Figure 2) and in sinus tracts at the end of month 6 (Figure 3). In addition to this; according to HISCR clinical response was seen in 9 patients (75%) (Figure 4). All of the patients included in this study were called separately and suggested to answer the questions in the Dermatology Life Quality Index (DLQI) questionnaire. All of the patients responded to treatment orally defined that; there has been no newly development or if present; it has occurred as smaller than the previous ones and the lesions disappeared more quickly. Besides, they reported that the exudation has stopped, no abscess has developed as the priors and the bed smell have already decreased or disappeared. In 7 patients; a decrease from Hurley 3 to 2, and in remaining 2 of the 5 patients with Hurley 2; a decrease to Hurley 1 were recorded after adalimumab treatment (Table 1).

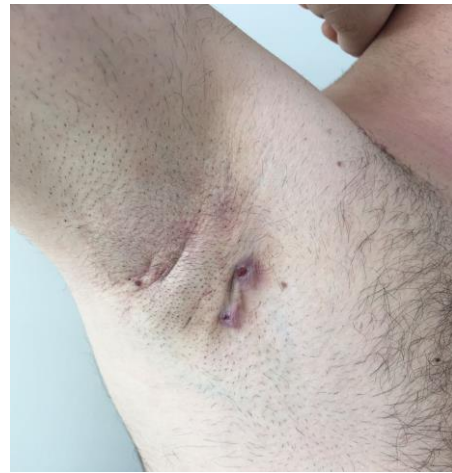

Figure 2. Fistula with two openings and atrophic scars on the right axillary area at 3 months

The clinical response and adverse effects to adalimumab

We determined that adalimumab had been used for minimum one year. We recorded that all patients were satisfied and had a clinical response (Figure 1-3). We observed that one

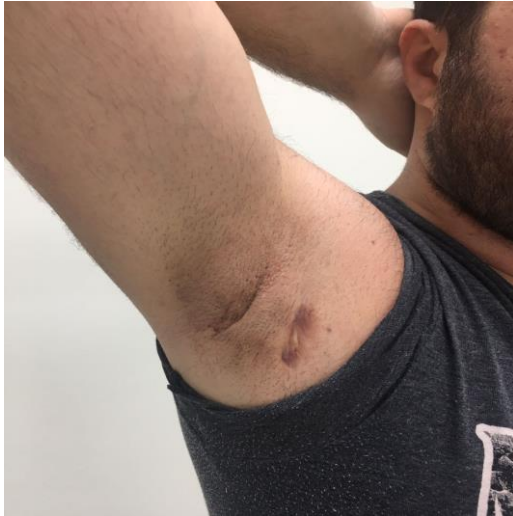

Figure 3. Atrophic scar areas on the right axillary area at 6 months

Before the treatment DLQI score was 14.4 ± 6.9 (range 7-21), but after the treatment DLQI score was found as; 4.3 ± 3.8 (range 1-8) ($p < 0.05$). Besides, before the corticosteroid treatment dermatology life quality index (DLQI) was found as 13.7 ± 5.3 (range 7-21), but it was 11.3 ± 2.1 (range 5-12) after the treatment. Before the systemic antibiotic use, DLQI score was 13.2 ± 3.3 (range 8-21), but after the treatment; it was 10.1 ± 2.4 (range 3-12) and before the retinoid use DLQI was recorded as; 14.7 ± 5.2 (range 8-17) and after treatment as; 9.4 ± 2.3 (range 3-11) ($p > 0.05$). We also ascertained that after the treatment a consultation was made to a nutritionist for all patients and started on either a lower fatty diet or a specialized diet accepted for patients with diabetes mellitus and metabolic syndrome.

In 3 patients; upper respiratory infection was observed (Table 1). In records of 3 patients; the treatment was discontinued and after re-initiation of the treatment; we noted that no sufficient clinical response was seen. Adverse effects were not seen in the other remaining patients.

DISCUSSION

The occlusion of the pilosebaceous unit and perifollicular secondary lymphohistiocytic inflammation is one of the responsible factors of the HS etiopathogenesis⁶. HS is a debilitating disease characterized by scar, sinus tract, exudation, and painful apocrin lesions on the areas where sweat glands are sited such as axillary, anogenital and inguinal areas. The disease may have somehow very severe negative physical (pain, limitation of movement), psychologic (depression, anxiety, social isolation) and economic (being unable to work and unemployment) effects⁷. In a previous study the estimated average recurrences were reported as 13.0% for wide excision, 22% for local incision, and 27.0% for deroofing after surgical management⁸. In patients with HS dyslipidemia, diabetes mellitus and metabolic syndrome have been seen more frequently, so the risk of cardiovascular diseases has also been increased. We believe that the consultation of all of the patients to dietary department is quite important for the reliability of our study after concerning for the factor of diet and obesity in the etiopathogenesis of HS. Another comorbid disease seen in HS is skin cancers although infrequent; located on the HS lesion's involvement areas. Squamous cell carcinoma has been reported to develop in 3.2% of the perineal HS lesions⁹. In a systematic review, 13 patients diagnosed with vulvar, perianal or perineal cancers with a past history of HS have been included and of the all patients in 7; vulvar cancer, and in 6; perineal or perianal cancers were reported.

Although the exact pathogenesis of HS is not known, it has been proven that it is an inflammatory disease according to clinical and experimental studies. In HS lots of medical treatments have been suggested with variable success rates¹⁰⁻¹³. No medical cure is present in HS. Different treatment options are frequently used and also combined with surgical

treatment¹⁴. The first line treatment choice is topical and systemic antibiotics. Antibiotics may achieve a decrease in the inflammatory lesions, but after the discontinuation of the antibiotics HS lesions often relapse. Although vitamin A derivatives such as; isotretinoin, acitretin may be used for long term, due to their risk of teratogenic toxicity, their widespread use is limited in especially women¹⁵⁻¹⁷.

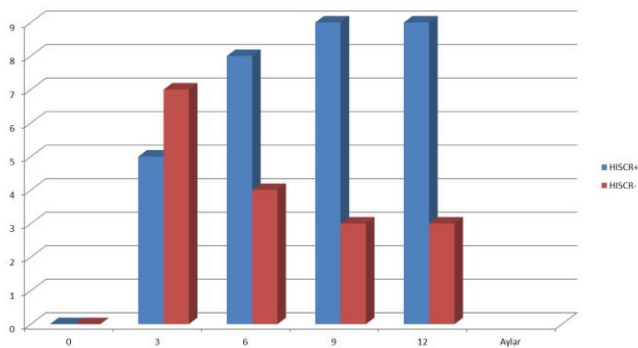


Figure 4. HISCR responses after adalimumab treatment

If the conventional treatments are insufficient, biological agents take place as the latter treatment step¹⁸. Adalimumab, is the only biological agent that have been proven by both EMA (European Medicines Agency, June 2015) and FDA (US Food and Drug Administration, September 2015) for the treatment of moderate to severe HS. The treatment agent that possesses the furthest data about the evidence-based treatment of HS is adalimumab. Upon the facts gathered from the studies; adalimumab stops the inflammatory pathway optimally and so prevents the development of scar tissue¹⁴. Although, biological agents are efficient treatment alternatives in HS, the permanent and complete clinical remission of the disease is rarely afforded¹⁹. Because of the commonly seen flare ups in HS, the combination treatments of systemic antibiotics and retinoids are also frequently used. There is a requirement of surgical treatment in most of the cases to prevent the scar development in chronic and very severe disease¹⁹.

Up to now; 15 clinical trials including 68 patients about the efficacy of adalimumab treatment in HS have been performed and the clinical success rate has been found as 79%¹⁸. In our study; we noticed that of the 12 patients with HS in 9 patients (75%) clinical responses were achieved retrospectively and these results have been found to be similar with the literature. In a clinical trial that investigate the clinical efficacy of biological agents in patients with HS adalimumab treatment was given for 9 months in 9 out of the 19 patients²⁰. In 5 patients long-term, continuous regimen was used and no severe adverse effects were reported. In 66.7% of the patients partial or complete clinical responses were noted. According to the patient's assessment of the clinical efficacy; complete or partial responses were recorded in 77.8% of the patients. After continuous adalimumab use in HS long-term clinical remission is provided, but a quick relaps is frequently seen after the disruption of the treatment have been highlighted. According to European HS S-1 treatment guidelines; in 42 patients diagnosed with HS adalimumab has been started subcutaneous 80 mg at the first week and 40 mg at the second week. In 23 patients (58%) more than 50% clinical response has been reported¹⁹. In the same study in 10 out of the 14 patients (71%) in whom adalimumab treatment has been stopped, clinical relapse or surgical treatment requirement was seen. The most common reported adverse effects of adalimumab are; injection site reactions, infections, myalgia and nausea in the literature. In our retrospective study; we ascertained that upper respiratory tract infection had been seen in 3 patients. No other adverse effects were seen in the remaining patients.

The clinical efficacy and life quality index results of our retrospective adalimumab trial were similar with the previous trials. According to the results of our study; the efficacy of adalimumab for the treatment of patients with

HS has been proven. Nowadays, due to the pathogenesis of the disease clinical studies that examine the efficacy of other biological agents such as; apremilast, anti-IL17 and anti-IL-1 α for the treatment of HS are still going on²¹. However, randomized, placebo controlled, prospective, multi-centered large-scale studies including more patients are necessary to evaluate the clinical responses of patients with HS to adalimumab in our country and determine the real life time data.

Declaration of Conflicting Interests: The authors declare that they have no conflict of interest.

Financial Disclosure: No financial support was received.

REFERENCES

1. Gönül M, Gül Ü. Hidradenitis Süpurativa. *Türk Dermatoloji Dergisi*. 2009; 3:9-12.
2. Ingram JR, Woo PN, Chua SL, Ormerod AD, Desai N, Kai AC, et al. Interventions for hidradenitis suppurativa: a Cochrane systematic review incorporating GRADE assessment of evidence quality. *British Journal of Dermatology*. 2016; 174:970-8.
3. Dominique C, Mekkes JR, Tzello T. Randomized Controlled Trials for the Treatment of Hidradenitis Suppurativa. *Dermatol Clin*. 2016;34:69-80.
4. Zhang J, Reeder VJ, Hamzavi IH. Use of biologics in the treatment of hidradenitis suppurativa: a review of the Henry Ford Hospital experience. *Br J Dermatol*. 2014; 171:1600-2.
5. Kimball AB, Jemec GB, Yang M, Kageleiry A, Signorovitch JE, Okun MM, et al. Assessing the validity, responsiveness and meaningfulness of the Hidradenitis Suppurativa Clinical Response (HiSCR) as the clinical endpoint for Hidradenitis suppurativa treatment. *British Journal of Dermatology*. 2014;171:1434-42.
6. Napolitano M, Megna M, Timoshchuk EA, Patruno C, Balato N, Fabbrocini G, et al. Hidradenitis suppurativa: from pathogenesis to diagnosis and treatment. *Clin Cosmet Investig Dermatol*. 2017; 10:105-15.
7. Balık E, Eren T, Yamaner S, Bulut T, Buğra D, Büyükuncu Y, ve ark. Gluteal Yerleşimli Yaygın Hidradenitis Suppurativa ile İlgili Cerrahi Deneyimlerimiz. *Kolon Rektum Hast Derg*. 2007; 17:27-32.
8. Mehdizadeh A, Hazen PG, Bechara FG, Zwingerman N, Moazen-zadeh M, Bashash M, et al. Recurrence of hidradenitis suppurativa after surgical management: A systematic review and meta-analysis. *J Am Acad Dermatol*. 2015;73:70-7.
9. Makris GM, Poulakaki N, Papanota AM, Kotsifa E, Sergeantanis TN, Psaltopoulou T. Vulvar, Perianal and Perineal Cancer After Hidradenitis Suppurativa: A Systematic Review and Pooled Analysis. *Dermatol Surg*. 2017;43:107-15.
10. Blok JL, Hattem S, Jonkman M.F, Horváth B et al. Systemic therapy with immunosuppressive agents and retinoids in hidradenitis suppurativa: a systematic review. *Br J Dermatol*. 2013;168:243-52.
11. Chinniah N, Cains GD. Moderate to severe hidradenitis suppurativa treated with biological therapies. *Australasian Journal of Dermatology*. 2014; 55:128-31.
12. Deckers IE, Prens EP. An Update on Medical Treatment Options for Hidradenitis Suppurativa. *Drugs*. 2016; 76:215-29.
13. van Rappard DC, Limpens J, Mekkes JR. The off-label treatment of severe hidradenitis suppurativa with TNF- α inhibitors: a systematic review. *Journal of Dermatological Treatment*. 2013; 24:392-404.
14. Fotiadou C, Vakirlis E, Ioannides D. Spotlight on adalimumab in the treatment of active moderate-to-severe hidradenitis suppurativa. *Clinical, Cosmetic and Investigational Dermatology*. 2016; 9:367-72.
15. Alhusayen R, Shear NH. Scientific evidence for the use of current traditional systemic therapies in patients with hidradenitis suppurativa. *J Am Acad Dermatol*. 2015; 73:42-6.
16. Kim ES, Garnock KP, Keam SJ. Adalimumab: A Review in Hidradenitis Suppurativa. *Am J Clin Dermatol*. 2016; 17:545-52.
17. Fimmel S, Zoubouli CC. Comorbidities of hidradenitis suppurativa (acne inversa). *Dermato endocrinol*. 2010; 2:9-16.
18. Chinniah N, Cains GD. Moderate to severe hidradenitis suppurativa treated with biological therapies. *Australasian Journal of Dermatology*. 2014; 55:128-31.

19. Zouboulis CC, Desai N, Emtestam L, Hunger RE, Ioannides D, Juhász I, et al. European S1 guideline for the treatment of hidradenitis suppurativa/acne inversa. *J Eur Acad Dermatol Venereol.* 2015; 29:619-44.
20. Martin-Ezquerro G, Masferrer E, Pujol RM. Use of biological treatments in patients with hidradenitis suppurativa. *G Ital Dermatol Venereol.* 2017; 152:373-78.
21. Weber P, Seyedjafari SM, Yawalkar N, et al Hunger RE. Apremilast in the treatment of moderate to severe hidradenitis suppurativa: A case series of 9 patients. *J Am Acad Dermatol.* 2017; 76:1189-91.