

■ Case Report

A case of foreign body aspiration diagnosed 5 years after the incident

Oluşundan 5 yıl sonra tanı konmuş yabancı cisim aspirasyonu

Serhat YALCINKAYA*

Dumlupınar University Medical School, Department of Thoracic Surgery, Kutahya, Turkey

ABSTRACT

Foreign body aspiration is rare in adult patients. The aspirated materials may be of various kinds and may not be diagnosed for a long period of time. The patients sometimes are even misdiagnosed and may be treated as asthma, pneumonia, and chronic obstructive pulmonary disease patients. A 72-year-old male patient treated as such was discovered to have a foreign body aspiration 5 years after the incident. The clinical presentation, history, and treatment are presented.

Keywords: Aspiration, bronchoscopy, speaking valve.

ÖZ

Erişkinlerde yabancı cisim aspirasyonu nadir olup çeşitli maddelerle gelişebilir. Şikayetlerin azlığı nedeniyle uzun süre fark edilmeyebilir. Hastalar bazen yanlışlıkla astım, pnömoni ve kronik obstrüktif akciğer hastalığı var sanılarak tedavi edilebilir. Benzer şekilde takip ve tedavi edilen 72 yaşında bir erkek hastada gerçekleştikten 5 yıl sonra tespit edilen bir yabancı cisim aspirasyonu olgusunun klinik bulguları, öyküsü ve tedavi sonuçları paylaşılmaktadır.

Anahtar kelimeler: Aspirasyon, konuşma protezi, bronkoskopi.

Corresponding Author*: Serhat Yalcinkaya, Dumlupınar University Medical School, Department of Thoracic Surgery, Kutahya, Turkey

E-Mail: serhat.yalcinkaya@dpu.edu.tr

Received 30.03.2017 accepted: 21.04.2017

Doi: 10.18663/tjcl.302667

Introduction

Foreign body (FB) aspiration is rare in adults [1]. The reported FBs include bone, pins, plant particulates, and speaking valves [2-6]. Usually these patients need urgent medical attention after aspiration. Yet, there are late diagnosed FB cases reported in literature as late as 10 years, indicating FB aspiration in adults may be surprising [2]. These patients may be misdiagnosed and treated as asthma, pneumonia, and or chronic obstructive pulmonary disease (COPD) patients [1, 6]. In this report, we would like to share a patient with a late diagnosed FB aspiration in the light of clinical presentation, history, and treatment of patient in our department.

Case Report

A 72 year-old male patient was referred to our Thoracic Surgery Department with a possible diagnosis of bronchial tumor in the right main stem bronchus. From his medical history a total laryngectomy due to larynx epidermoid carcinoma with tracheostomy 5 years ago was noted. During follow-up controls, he complained of cough and dyspnea for the last year. His physician ordered a chest computed tomography (CT) scan and discovered a mass lesion on the right lung (Figure 1). He was receiving maximum bronchodilator therapy due to COPD diagnosis. Since tracheostomy patients maybe not be suitable for rigid bronchoscopy, the patient was referred to the local pulmonology hospital for fiberoptic bronchoscopy. The intervention revealed an unknown FB in the right main stem bronchus. The patient was referred back to us for a session of rigid bronchoscopy. We performed rigid bronchoscopy using a size 6.5 Storz bronchoscope (KARL STORZ GmbH & Co., Tuttingen, Germany) tube under general anesthesia. During the procedure a FB was seen in the right main stem bronchus with a prominent granulation tissue surrounding it (Figure 2). Using an alligator grasping forceps two pieces of plastic material were removed, later understood to be parts of a speaking valve (Figure 3). The patient was transferred to the ward after the procedure. On the following day while questioning his medical past in detail, the relatives of the patient told that he had a hard time using and declined to use the valve right after the laryngectomy operation. Neither he nor the physicians followed him noticed the device parts were aspirated. His respiratory symptoms recovered right after the procedure, and the patient was discharged on day two without any bronchodilators.

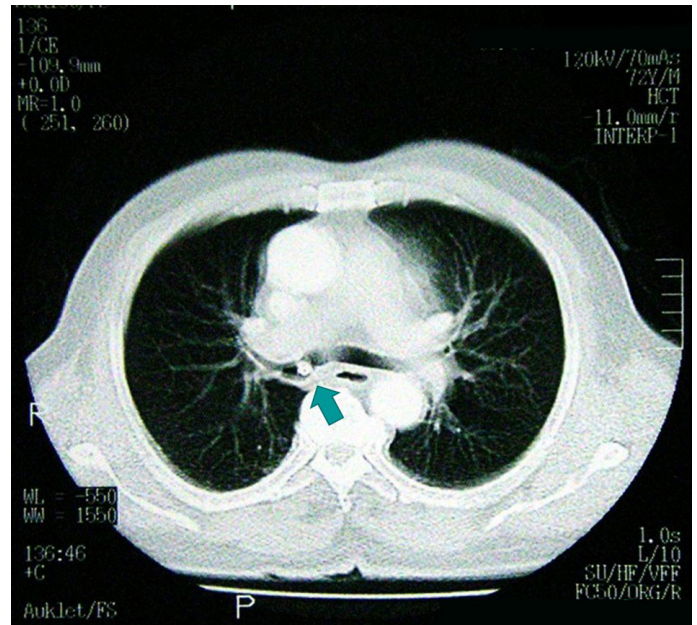


Figure 1. Chest computed tomography scan showing a mass lesion (arrow) in the right main stem bronchus.

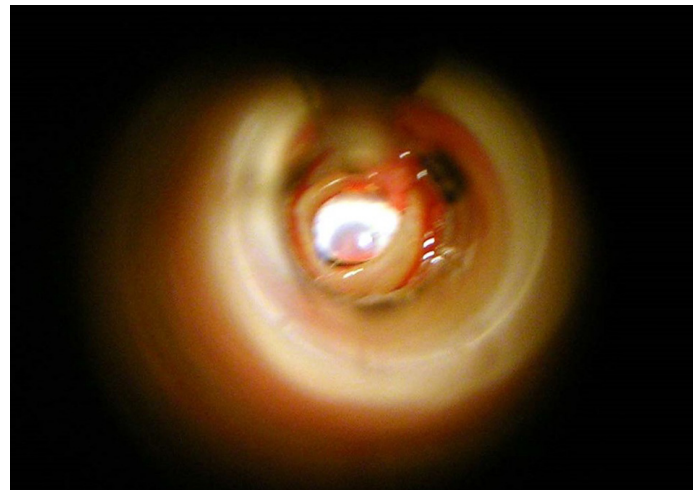


Figure 2. Rigid bronchoscopy revealed a foreign body with surrounding granulation.

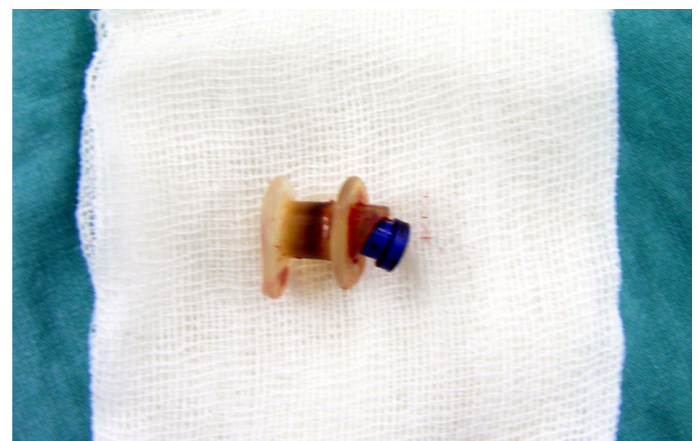


Figure 3. The plastic materials removed were parts of a speaking valve.



Discussion

FB aspiration is common in children, especially under 3 years of age [6]. In the adults, however, it is rare and the patients usually have accompanying physical and mental issues, as well as alcoholism [1, 6]. While the classical triad of cough, dyspnea, and cyanosis is frequent in children, they occur in only few adult patients [1]. This lack of acute symptoms may be due to the larger caliber of airways, leading most FBs placing and obstructing more distal airways [2]. The most common symptoms of a FB aspiration are: cough, choking, dyspnea, fever, and hemoptysis [1, 6]. Our patient had cough and dyspnea.

FBs are placed more frequently in the right bronchial tree [1, 6]. Various materials are reported and may be classified as organic (e.g. bone fragments (especially chicken), fish bones, pieces of vegetables or fruits), and inorganic (e.g. pins, screws, rivets or plastic devices) substances. It may be advisable to name a third group of substances as iatrogenic including pieces of speaking devices, tracheostomy cleaning brushes or dental bridges [1]. Recently some investigators reported on speaking valve aspiration in tracheostomy patients [3-5].

In 2010 Kadam et al reported on a 73-year-old male patient underwent total laryngectomy and received radiotherapy 18 years earlier than the administration to the hospital due to a sudden onset of respiratory distress symptoms including sitting upright, looking pale, having stridor and unable to vocalize [3]. Emergency flexible nasoendoscopic examination unveiled the aspirated speaking valve. They removed the valve using a rigid bronchoscope. Schembri et al reported on a 70-year-old male patient underwent laryngectomy operation some 12 years ago and had dyspnea on minimal exertion and he was also noted to have a chronic cough. Chest CT revealed an opacity in the right main stem bronchus. Although flexible bronchoscopy was preferred, the FB was implanted within the granulation tissue, so the investigators had to use the rigid bronchoscopy to stabilize the flexible bronchoscopy under general anesthesia. They removed the speaking valve probably been there for 12 years [4]. Quinn et al reported on a 75 year-old male patient with treated larynx and lung carcinoma presented with weight loss, general malaise, dyspnea and cough present for 2 months [5]. As he had previous malignancies and weight loss, a chest CT was ordered. The CT revealed a little soft tissue change in the right main stem bronchus taken as related to retained secretions. During rigid bronchoscopy, the speaking valve was seen and removed with success. Our patient was 72 years old and had a history of laryngectomy due to larynx carcinoma 5 years ago. Because of his medical history and complaints, a chest CT was ordered and a lesion then thought to be a malignancy was discovered in the right main stem bronchus.

Age group effects the kind of the bronchoscope preferred in FB removal, as well. In children, rigid bronchoscope is accepted as the safest way, whereas in the adult flexible bronchoscopy is widely used [1]. Yet, in situations like abundant granulation tissue surrounding the FB, large FBs, sharp edged FBs, and unsuccessful attempts with flexible bronchoscopy leads to use of rigid instead of flexible bronchoscope [1]. We preferred to use rigid bronchoscope as the attempts with the flexible bronchoscopy were unsuccessful, due to abundant granulation tissue.

Recovery following removal of the FB is usually complete and fast [2]. The patients reported in literature usually recovered totally and are discharged from the hospital within few days without any complications [3-5]. We discharged our patient without any complications on day two following bronchoscopic removal. On the first day following removal, he didn't need any bronchodilators, as well.

We conclude that FB aspiration in the adults can only be recognized if kept in mind. Reports of cases in the literature suggest this view. In case of suspicion, a chest thorax CT may be preferred over chest x-ray, and rigid bronchoscopy should be the treatment of choice.

Declaration of conflicting interests

The author declared no conflicts of interest with respect to the authorship and/or publication of this article.

Declaration of conflict of interest

The authors received no financial support for the research and/or authorship of this article. There is no conflict of interest.

References

1. Blanco Ramos M, Botana-Rial M, Garcia-Fontan E, Fernandez-Villar A, Gallas Torreira M. Update in the extraction of airway foreign bodies in adults. *J Thorac Dis.* 2016;8(11):3452-6.
2. Wang L, Pudasaini B, Wang XF. Diagnose of occult bronchial foreign body: A rare case report of undetected Chinese medicine aspiration for 10 long years. *Medicine (Baltimore).* 2016;95(31):e4076.
3. Kadam VR, Lambert P, Pant H, O'Reilly M. 'Speaking valve' aspiration in a laryngectomy patient. *Anaesthesia and Intensive Care.* 2010;38(1):197-200.
4. Schembri J, Cortis K, Mallia Azzopardi C, Montefort S. Aspiration of a speaking valve. *BMJ Case Rep.* 2013;2013.
5. Quinn K, Rowan SA, Rendall J. An unusual cause of pneumonia: seen but not heard. *BMJ Case Rep.* 2013;2013.
6. Cobanoglu U, Yalcinkaya I. Tracheobronchial foreign body aspirations. *Turkish Journal of Trauma & Emergency Surgery.* 200;15(5):493-9.