



HISTOPATHOLOGICAL EXAMINATION OF THE LIVERS OF COMPULSORILY SLAUGHTERED HOLSTEIN DAIRY CATTLE

Kemal AKSOY^{1*}, Korkut BOZKURT², Abdülkerim DENİZ³, Mert METİN⁴, Muhammed ÖZER⁵

¹University of Muğla Sıtkı Koçman, Faculty of Veterinary Medicine Milas, Department of Internal Medicine, Muğla, Türkiye

²University of Health Sciences, İzmir Tepecik Training and Research Hospital, Department of Pathology, İzmir, Türkiye

³Independent Researcher in Biochemistry, Nispetiye District, Bakır Street, Beşiktaş, İstanbul, Türkiye

⁴University of Muğla Sıtkı Koçman, Faculty of Veterinary Medicine Milas, Department of Biochemistry, Muğla, Türkiye


⁵University of Muğla Sıtkı Koçman, Faculty of Veterinary Medicine Milas, Milas Veterinary Medicine Program, Muğla, Türkiye


Abstract: In recent years, many dairy cows in Türkiye have been compulsory slaughtered before they have finished their lactation due to liver diseases. This study aimed to examine pre-slaughter clinical examination and post-slaughter liver tissue damage in Holstein breed dairy cows subjected to compulsory slaughter. In the present study, liver tissue from 85 Holsteins (n= 4 primiparous, n= 81 multiparous) aged 3-13 years that were delivered to slaughterhouses for compulsory slaughter was used. Clinical examination of all animals was performed before slaughter. After the obtained tissues were fixed, they were examined for steatosis, inflammation, fibrosis, and necrosis using histopathological methods. Lesions of varying degrees were found in 46% of the liver tissues analyzed. Among the reported findings were three examples of hepatic steatosis - one mild, one moderate and one severe. There were a total of 35 cases (41.2%) of liver inflammation that were found to be significant ($p<0.001$), of which 23 were mild, 6 moderate, and 6 severe. No fibrosis was detected in any of the samples, but only one sample showed mild necrosis. The clinical examination stated that rumen acidosis and dyspepsia led to slaughter in 35.3% of the animals, while 21.2% were sent to slaughter due to anestrus/uterus disease/infertility problems. In conclusion, histopathological findings indicated a significantly high liver inflammation and the majority of compulsorily slaughtered Holsteins had rumen acidosis/indigestion and anestrus/fertility problems.


Keywords: Fatty liver, Fibrosis, Compulsorily slaughtered, Inflammation, Necrosis


*Corresponding author: University of Muğla Sıtkı Koçman, Faculty of Veterinary Medicine Milas, Department of Internal Medicine, Muğla, Türkiye


E mail: kemalaksoy@mu.edu.tr (K. AKSOY)

Kemal AKSOY  <https://orcid.org/0000-0003-0149-6688>

Korkut BOZKURT  <https://orcid.org/0009-0009-7237-7775>

Abdülkerim DENİZ  <https://orcid.org/0000-0002-5242-5671>

Mert METİN  <https://orcid.org/0000-0002-1402-4594>

Muhammed ÖZER  <https://orcid.org/0009-0004-5310-3430>

Received: January 16, 2025

Accepted: February 21, 2025

Published: March 15, 2025

Cite as: Aksoy K, Bozkurt K, Deniz A, Metin M, Özer M. 2025. Histopathological examination of the livers of compulsorily slaughtered Holstein dairy cattle. BSJ Agri, 8(2): xxx-xxx.

1. Introduction

The compulsory slaughter of a large number of breeding cows due to various diseases causes significant losses to the country's economy and farmers. 781947 high-performance dairy cows were compulsorily slaughtered between 2017 and 2019. Many of these slaughtered cows are due to metabolic diseases and infertility problems (Aksoy et al., 2021).

The liver is an important organ that plays the biggest role in metabolic processes in the body of a living organism. The main functions of the liver can be classified as metabolism, secretion, storage, synthesis, and detoxification. (Imren and Şahal, 2002). The liver is essential for giving periparturient dairy cows energy from various (Drackley et al., 2001).

It has been reported that in addition to bacterial, viral, and parasitic agents, many metabolic diseases also cause lesions in the liver (Stalker and Hayes, 2007; Metin, 2011). Hepatitis is the word for inflammation of the liver parenchyma, and it can be either acute or chronic

(Dodurka, 2002; Cullen et al., 2007). The factors causing inflammation in the liver were viral and bacterial agents (Sağlam et al., 2003; Stalker and Hayes, 2007; Tadepelli et al., 2009; Metin, 2011; Buergelt et al., 2017), mycotic and parasitic diseases (*F. hepatica*, *Dicrocoelium dendriticum*), the toxic effects of certain drugs, immunological diseases, chronic diseases of the digestive system, inorganic, organic, and plant toxins, and toxins from diseases characterised by inflammation such as metritis and mastitis (Altun and Sağlam, 2014; Batmaz, 2016). Fibrosis, on the other hand, can develop as a result of chronic liver diseases, and the resulting damage can be irreversible (Friedman, 2000; Brown et al., 2010; Eulenberg and Lidbury, 2018). Hepatocytes may develop necrosis if the causes of liver tissue degeneration are not removed (Cheville, 1988; Milli and Hazıroğlu, 1997; Stalker and Hayes, 2007). Viral diseases cause not only inflammation in the liver but also degenerative and necrotic changes (Sağlam et al., 2003; Stalker and Hayes, 2007; Tadepelli et al., 2009; Metin, 2011).



Liver enzyme elevations are generally the first clinical-pathological changes observed in liver diseases. The damage occurring in the liver responds to a limited number of pathological changes. The occurrence of changes such as multiple necrosis and fibrosis in the final stage of this organ, along with the inflammatory response to dead cells, happens in the advanced stages of liver diseases. New hepatocytes or connective tissue cells (fibrosis) replace the dead cells (Buergelt et al., 2017).

Liver tissue damage is most commonly observed as fatty liver syndrome during the transition period in high-yielding dairy cows. Fatty liver, often known as hepatic lipidosis or fat cow syndrome, affects dairy cows mostly in the first few weeks of lactation but may already be evident just before or after parturition (Grummer, 1993; Bobe et al., 2004; Gross et al., 2013). During the first few months of lactation, between 50% and 60% of all dairy cows have higher hepatic lipid levels, according to a previous study by Jorritsma and colleagues (2000; 2001). Up to 40% of dairy cows with hepatic lipidosis in the first month after calving are estimated to have moderately fatty livers, and up to 10% have severe hepatic infiltration (Bobe et al., 2004). In the early postpartum phase, about 80% of downer cows had moderate to severe hepatic fat infiltration (Kalaitzakis et al., 2010). Additionally, the clinical relevance of hepatic lipidosis can be indirectly assessed by looking at the incidence rates of metabolic disorders that are closely connected, including ketosis (Gross, 2023).

In Türkiye, there has never been a study focussing only on compulsorily slaughtered Holsteins. Among the reasons for the compulsory slaughter of animals, it will be important to observe the occurrence of fatty liver, inflammation, necrosis, and fibrosis in the liver tissue. Without the invasive procedure in live animals, only slaughterhouse material was used in the present study for animal welfare reasons. The present study aimed to investigate pre-slaughter clinical findings and the histopathological changes in the liver tissue of compulsorily slaughtered Holsteins and the relationship between liver damage and the reason for slaughter.

2. Materials and Methods

2.1. Animal material

A total of 85 Holstein dairy cows brought to the slaughterhouse from 35 different villages with various diseases were examined clinically and histopathologically for liver tissue. After slaughter, liver samples were taken from dairy cows brought to the Menteşe and Milas slaughterhouses in the province of Muğla for compulsory slaughter.

The youngest cow was 3 years old, while the oldest was 13 years old, and the average age of the animals included in the study was 7 years. The lowest live weight of the animals sent for slaughter was 316 kg, while the highest live weight was recorded at 1090 kg. The average live weight of all the animals was 565 kg. Four Holsteins were primiparous, and 81 Holsteins were multiparous.

2.2. Clinical Examination

All animals underwent detailed antemortem clinical examinations before slaughter. Samples were taken from animals that were determined to have completed their productive lives and were suitable for slaughter. As a result of the clinical examination, liver samples were taken from 85 animals that were found to have completed their productive lifespan after slaughter.

2.3. Liver Material Collection

Immediately after the slaughter of dairy cows, four (4x10 g) liver tissue samples of 10 grams were excised from the caudal region of their livers and placed in ziplock bags (Gerspach et al., 2017). Earrings number, farm name, breed and age of the slaughtered animal were written on each sample bag. The samples were brought to the laboratory with +4 °C transport containers and the liver tissue was fixed with 10% formalin for histological examination.

2.4. Histopathological Examination of Liver Samples

Liver samples were divided into 8-micrometre thick sections using a frozen microtome and stained with Oil Red O. The same tissues were also routinely examined after being fixed with 10% formaldehyde, and 5-micrometre sections were cut from paraffin blocks. The sections were then stained with hematoxylin-eosin and prepared as two separate preparations for examination under the light microscope. Fat in liver cells histologically stained with red oil were classified as 1 (mild) if less than 33% of the cell (vacuole= $10 \mu\text{m}^2/100 \mu\text{m}^2$), 2 (moderate) if between 33-66% (vacuole= $10-20 \mu\text{m}^2/100 \mu\text{m}^2$), and 3 (severe) if greater than 66% (vacuole= $20 \mu\text{m}^2/100 \mu\text{m}^2$) (Brunt et al., 1999; Atasever et al., 2020). Inflammation, necrosis and fibrosis were graded between 0-3 (absent= 0, mild= 1, moderate= 2, severe= 3) (Sevinç and Aslan, 1998; Atasever et al., 2020).

2.5. Statistical Analysis

The software MedCalc (MedCalc Software Ltd, Belgium) version 2022 was used to perform the statistical analyses. Descriptive statistics were used to indicate the reasons for slaughter the frequency of liver damage percent, and the degree of damage as previously categorized. The chi-square test was used to determine whether the diseases detected in all samples were significant or not. A value of $p \leq 0.05$ is accepted as significant.

3. Results

3.1. Clinical examination

As a result of the clinical examination, diseases such as rumen acidosis, indigestion, and infertility were mostly detected. The clinical examination findings are detailed in table 2. The clinical examination findings were found to be similar to the diseases mentioned in the official health report.

Table 1. Histopathological results of the 85 liver samples of Holsteins compulsorily slaughtered: number of adiposity, inflammation, necrosis and fibrosis in Primiparous (PRP, n= 4 total) and multiparous (MUL, n= 81 total) Holsteins

	Adiposty	Inflammation	Necrosis	Fibrosis
Positive (n, total)	3	35	1	0
Negative (n, total)	82	50	84	85
Positive % (total)	3.5	41.2	1.2	0
P	>0.05	<0.001	>0.05	NA
PRP positive (n)	0	2	0	0
PRP negative (n)	4	2	4	4
PRP positive (%)	0	50	0	0
P	NA	NA	NA	NA
MUL positive (n)	3	33	1	0
MUL negative (n)	78	48	80	81
MUL positive (%)	3.7	40.7	1.2	0
P	>0.05	<0.001	>0.05	NA

NA= not applicable.

3.2. Results of Histopathological Examination of Livers

The results of the histopathological examination of the 85 liver samples, the degree of adiposity, inflammation, necrosis and fibrosis were classified according to their severity and presented in table 1 and figure 1.

While 39 animals (45.9%) were found to have various degrees of different pathological findings, none of the four different pathological findings were found in the 46 liver samples (54.1%) that were assessed as healthy and without lesions. Various degrees of adiposity were found in 3 samples (3.5%). Inflammation was detected at a rate of 41.2% (n= 35). Out of 35 positive inflammation samples, mild inflammation was detected in 23, moderate inflammation in 6, and severe inflammation in 6. In 1 out of 85 samples, mild necrosis was detected, which corresponds to 1.2%. Fibrosis was not detected in any of the samples.

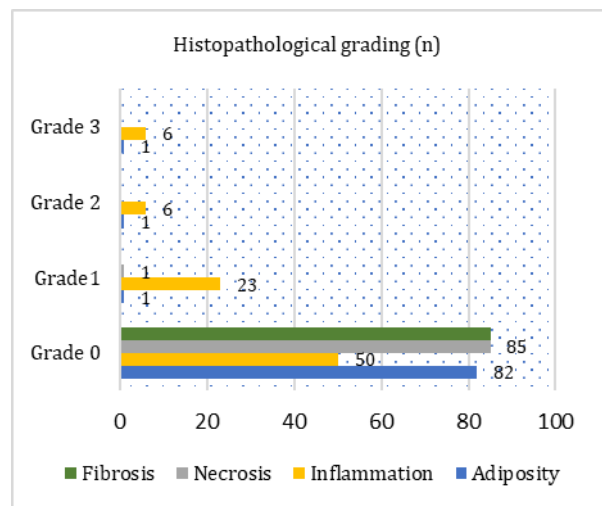


Figure 1. Results of the histopathological examination of the 85 liver samples from compulsorily slaughtered Holsteins: the degree of adiposity, inflammation, necrosis and fibrosis were classified according to their severity.

Table 2. Descriptive statistics on the causes of slaughter and liver inflammation by histopathological examination in 85 compulsorily slaughtered Holsteins

Reason for Compulsory Slaughter	Total compulsorily slaughtered (n= 85)		Liver inflammation (n= 35)	
	n	%	n	%
Chronic mastitis/mammary fibrosis	9	10.6	4	11.4
Omasum constipation	7	8.2	0	0.0
Reticuloperitonitis traumatica	6	7.1	4	11.4
Old age	4	4.7	2	5.7
Paralytic ileus	1	1.2	0	0.0
Indigestion and ruminal acidosis	30	35.3	13	37.1
Ovarian-dysfunction/anesturs/uterus diseases/infertility	18	21.2	8	22.9
Abomasum displacement	3	3.5	1	2.9
Abomasum ulcer	3	3.5	1	2.9
Milk fever	4	4.7	2	5.7

The reasons for the compulsorily slaughtered Holsteins with liver inflammation are shown in table 2. Indigestion/rumen acidosis, ovarian

dysfunction/infertility/uterine problems, RPT and chronic mastitis/mammary fibrosis were the reasons in the majority of Holsteins with liver inflammation. Most

Holsteins were sent to forced slaughter due to indigestion/rumen acidosis (35.3%) and ovarian dysfunction/anestrus/uterus problems (21.2%).

In the histopathological examination of tissue sections prepared from the livers (figures 2, 3 and 4), the widespread distribution of macro and microvesicular fat vacuoles of varying sizes in hepatocytes within the liver parenchyma was noteworthy. Holsteins in this study had mild to severe inflammation, and the inflammatory infiltrates were distributed either periportally or diffusely throughout the liver tissue. Consequently, modest portal inflammatory infiltrates were present in the majority of hepatitis.

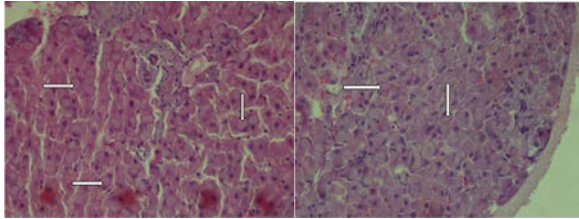


Figure 2. Grade 3 steatosis, stained with hematoxylineosin (white arrows).

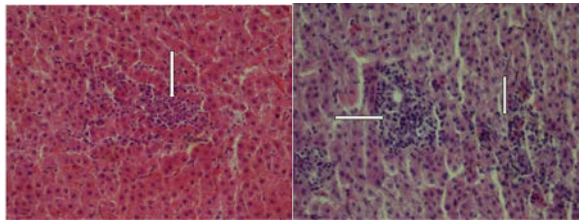


Figure 3. Lobular inflammation/Neutrophil and mononuclear cell infiltrations (white arrows).

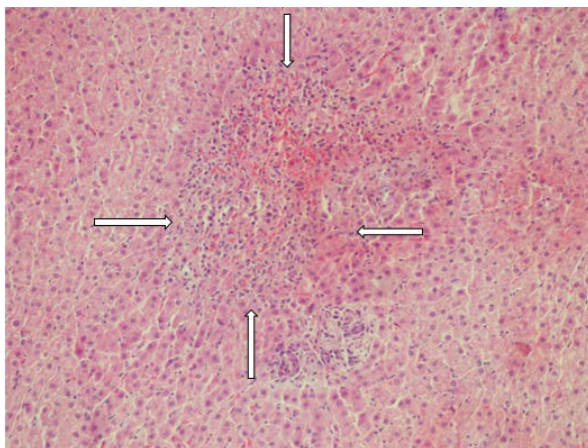


Figure 4. Mixed mononuclear / polymorphonuclear cell infiltration and accumulation in hepatic lobules and necrosis (white arrows).

4. Discussion

In Türkiye, most dairy cows go to slaughter before completing their lactation life. In fact, 781947 dairy cows were compulsorily slaughtered between 2017 and 2019 in Türkiye. Metabolic diseases played a major role in slaughtering dairy cows at an early age. Abomasal

displacement, fatty liver disorders, milk fever, and ketosis were frequent, particularly in Holstein dairy cows (Aksoy et al., 2021). The present study aimed to examine histopathological changes in liver tissues of Holsteins slaughtered compulsorily in slaughterhouses. Instead of the hazardous and laborious method of taking a biopsy from the liver of a live animal, the liver tissues of freshly slaughtered dairy cows were examined.

Fatty liver is a common disease in dairy cows and is associated with many diseases (Wensing et al., 1997; Bobe et al., 2004). Additionally, there are correlations between fatty liver and a higher culling rate and a worse lifespan performance (Gross, 2023). Bacterial, viral, and parasitic agents, the toxic effects of some drugs, immune system diseases, and many diseases characterized by inflammation also cause inflammation in liver tissues (Stalker and Hayes, 2007; TadePELLI et al., 2009; Metin, 2011; Altun and Sağlam, 2014; Batmaz, 2016; Buergelt et al., 2017).

In a study conducted in Türkiye (Altun and Sağlam, 2014), 1381 bovine livers brought to the slaughterhouse were examined, and histopathological examination was performed on 100 liver tissues where lesions were detected during macroscopic examination. As a result of the examination, abscess formation was detected in 11% of the lesioned samples, connective tissue proliferation and cirrhosis in 21%, necrosis of varying sizes and locations in 38%, fat degeneration in 4%, hydropic degeneration and cloudy swelling in 56%, hyperemia and congestion in 17%, and pigmentation in 9%. The cattle breeds used in this study were unspecified and healthy animals were slaughtered, which differed from the present study. While fat degeneration was found to be 4%, which was close to our study, necrosis formation was found to be very high at 38% compared to the present study. In a study conducted in the Netherlands on the prevalence of liver steatosis in 218 live animals selected from 9 different farms, the prevalence of liver steatosis was found to be 54%. In this study, liver steatosis was investigated by measuring serum NEFA values and liver triacylglycerol levels in liver biopsies taken from the animals between 6-17 days postpartum (Jorritsma et al., 2001). A fatty liver can cause ketosis or subclinical ketosis in the postpartum period (Herdt, 1988; Gross, 2023). Subclinical ketosis leading to metabolic and reproductive diseases in high-producing cows has been observed in an average of 22-24% of dairy cows worldwide (Suthar et al., 2013; Brunner et al., 2019), while clinical ketosis has been observed in an average of 7.2% (Venjakob et al., 2017). Here too, fatty liver leads to a predisposition to postpartum disease due to reduced reproductive performance, lower milk yield and weakened immunity (Breukink and Wensing, 1997; Sevinç and Aslan, 1998; Geelen and Wensing, 2006; Gross, 2023.). In another study conducted in Türkiye in 1996, a relationship between fatty liver and hypocalcemia was found. In 20 dairy cows diagnosed with hypocalcemia, liver samples taken through biopsy

procedures revealed varying degrees of fatty liver, approximately 70% (Sevinç and Aslan, 1998). In another study, 1400 bovine livers randomly selected from slaughtered animals were examined macroscopically, and a large number of parameters were investigated histopathologically in 100 of them that had lesions. Hyperaemia (17%), haemorrhage (4%), hydropic degeneration and fuzzy swelling (87%), lipidosis (13%), necrosis (26%), hepatitis (47%), kuppfer cell proliferation (56%), bile duct hyperplasia (13%), biliary fibrosis (17%), parenchymal fibrosis (3%), and melanosis (2%) were all found during the histopathological examination. Hyperaemia (1.21%), hemorrhage (0.29%), hydropic degeneration and fuzzy swelling (6.21%), lipidosis (0.93%), necrosis (1.86%), hepatitis (3.36%), kuppfer cell proliferation (4%), bile duct hyperplasia (0.93%), biliary fibrosis (1.21%), parenchymal fibrosis (0.21%), and melanosis (%0.14) were the rates, taking into account all of the cattle that were slaughtered (Oruç, 2009). The breeds of the animals included in this study, whether they are dairy cattle or beef cattle, were not reported, and they were stated to be healthy during the antemortem examination. In this study, the results obtained from the lesioned samples showed that the value for hepatitis was close to our study, while the values for fibrosis, necrosis, and lipidosis were numerically higher than those in our study. The fact that the animals used in the study were healthy upon antemortem examination, belonged to different breeds and were either beef or dairy cattle are important factors affecting the research results. In another study conducted in the province of Erzurum, Türkiye, the rate of steatosis was found to be 4%. In the same study, it was reported that necrotic areas were detected in 38% of the cases. In our study, necrotic areas were found in only 1 case. In this study, fibrosis was found in 21% of the cases with lesions, but in our study, no samples showed fibrosis. In this study, healthy male and female animals were used in the antemortem examination (Altun ve sağlam, 2014). Fibrosis mostly occurs as a result of chronic liver diseases and the damage it causes is irreversible. It can be said that there was no such serious liver damage in the animals included in our study. It can be speculated that the high level of inflammation observed in our study can suggest the presence of one or more of the factors such as viral, bacterial, mycotic, parasitic, and toxic agents that cause inflammation in the liver of compulsorily slaughtered cows in the present study.

There have been studies on the prevalence of parasitic diseases of the bovine liver (Celep et al., 1990; Gargılı et al., 1999; Şimşek et al., 2005; Balkaya and Şimşek, 2010a) and pathological changes have been observed in the liver in Türkiye (Gözün ve Kiran, 1999; Durgut et al., 2003; Oruç, 2009; Balkaya et al., 2010b; Altun and Sağlam, 2014). Celep et al. (1990) reported, the prevalence of species were as follows : Trematods; *D.dendriticum* (74.6%), *C.daubneyi* (39.4%), *F.hepatica* (25.3%), *P.cervi* (0.7%), Nematodes; *Ostertagia spp.* (65.5%), *Cooperia spp*

(45.8%), *Oesophagostomum spp.* (32.4%), *T. axei* (31.0%). In another study, following the slaughter, the liver and lungs, as well as other internal organs, were inspected for hydatid cysts and for Fasciola species in the liver bile ducts. 717 (34.3%) of the 2088 animals tested positive for hydatid cysts. Of these cattle with the infection, 520 (72.5%) had hydatid cysts in their lungs, 83 (11.6%) had just liver cysts, and 109 (15.2%) had both liver and lung cysts (Balkaya and Şimşek, 2010a). However, in these studies, there was no detailed information about dairy cattle or beef cattle. In our study, only liver samples from Holsteins brought to the slaughterhouse for compulsory slaughter were used.

Sending dairy cows to slaughter before completing their lactation period causes significant economic losses in animal husbandry (Aksoy et al., 2021). According to the Tigem 2024 report, one lactating Holstein dairy cow costs around €3803. Aksoy et al. (2021) reported that 260000 dairy cows are sent for forced slaughter every year. This represents an average annual economic loss of 989 million euros in Türkiye. Replacing forced slaughtered Holsteins in the dairy industry will take time and also incur additional costs.

5. Conclusion

In summary, the histopathological findings indicated a significantly high level of liver inflammation in compulsorily slaughtered Holsteins and that rumen acidosis/indigestion and anestrus/fertility problems were the cause of slaughter in the majority of cows. This study has once again highlighted the urgent need to implement liver-protective protocols in herd management, particularly on family farms, to address this deficiency. It could be helpful for producers to establish a monitoring system in dairy farming.

Author Contributions

The percentages of the authors' contributions are presented below. All authors reviewed and approved the final version of the manuscript.

	K.A.	K.B.	A.D.	M.M.	M.Ö.
C	30	10	30	10	20
D	60		20		20
S			100		
DCP	10	40			50
DAI	50		50		100
L	20	20	20	20	20
W	70	10	20		
CR	20	20	20	20	20
SR	100				
PM	40	30			30
FA	50				50

C= concept, D= design, S= supervision, DCP= data collection and/or processing, DAI= data analysis and/or interpretation, L= literature search, W= writing, CR= critical review, SR= submission and revision, PM= project management, FA= funding acquisition.

Conflict of Interest

The authors declared that there is no conflict of interest.

Ethical Consideration

The present study was approved by the Animal Experiments Local Ethics Committee of Muğla Sıtkı Koçman University (approval date: Septeber 23, 2021, protpcele code: 33/21).

Acknowledgments

This research was supported financially by TÜBİTAK (2209-A University Students Research Projects Support Program, Application number 1919B012101249).

References

- Aksoy K, Deniz A, Metin M. 2021. Retrospective study about the transformation of dairy cattle population in Turkey (1991-2019) and possible metabolic and reproductive problems. *BSJ Health Sci*, 4(2): 77-84.
- Altun S, Sağlam YS. 2014. Pathological examinations of lesions seen in liver of the cows slaughtered in Erzurum province. *Atatürk Üniv Vet Bil Derg*, 9(1): 7-15.
- Atasever A, Sayar E, Ekebaş G, Şentürk M, Eren M. 2020. The effects of pumpkin seed oil on chronic liver damage induced Carbon Tetrachloride in rats and determination of hepatic apoptosis and caspase activity. *Dicle Üniv Vet Fak Derg*, 13(1): 24-32.
- Balkaya İ, Şimşek S. 2010a. Erzurum'da kesilen sığırlarda hidatidosis ve fascioliasis'in yaygınlığı ve ekonomik önemi. *Kafkas Üniv Vet Fak Derg*, 16: 793-797.
- Balkaya İ, Terim Kapakin KA, Atasever İ. 2010b. Fasciola hepatica ile doğal enfekte sığır karaciğerlerinin morfolojik ve histopatolojik olarak incelenmesi. *Atatürk Üniv Vet Bil Derg*, 5: 07-11.
- Batmaz H. 2016. Sığırların iç hastalıkları semptomdan tanıya tanıdan sağaltıma. *Özsan Mat San, Bursa, Türkiye*, 3rd ed., pp: 160.
- Bobe G, Young JW, Beitz DC. 2004. Invited review: pathology, etiology, prevention, and treatment of fatty liver in dairy cows. *J Dairy Sci*, 87(10): 3105-24.
- Breukink HJ, Wensing T. 1997. Pathophysiology of the liver in high yielding dairy cows and its consequences for health and production. *Isr J Vet Med*, 52: 66-72.
- Brown DL, Winkle TV, Cecere T, Rushton S, Brachelente C, Cullen JM. 2010. Congenital hepatic fibrosis in 5 Dogs. *Vet Pathol*, 47: 102-107.
- Brunner N, Groeger S, Raposo JC, Bruckmaier RM, and Gross JJ. 2019. Prevalence of subclinical ketosis and production diseases in dairy cows in Central and South America, Africa, Asia, Australia, New Zealand, and Eastern Europe. *Transl Anim Sci*, 3(1): 84-92.
- Brunt EM, Janney CG, Di Bisceglie AM, Neuschwander-Tetri BA, Bacon BR. 1999. Nonalcoholic steatohepatitis: a proposal for grading and staging the histological lesions. *Am J Gastroenterol*, 94: 2467-2474.
- Buergelt CD, Edward GC, Fabio DP. 2017. Bovine pathology, a text and color atlas. In: Buergelt CD, Clark EG, Del Piero F, editors. *Bovine pathology, a text and color atlas: Hepatobiliary system and pancreatic diseases*. CAB International (CABI), Oxfordshire, UK, 1st ed., pp: 161-169.
- Celep A, Açıcı M, Çetindağ M, Coşkun SZ, Gürsoy S. 1990. Helminthological studies on cattle from the Samsun region. *Etlik Vet Mikrobiol Derg*, 6: 117-130.
- Cheville NF. 1988. *Veterinary pathology*. Iowa State University Press, Ames-Iowa, USA, 3th ed., pp: 84-197.
- Cullen J. 2007. Hepatotoxic agents: Liver, biliary system, and exocrine pancreas. In: McGavin M, Zachary J, editors. *Pathologic basis of veterinary disease*. Mosby Elsevier, Missouri, USA, 4th ed., pp: 393-461.
- Dodurka T. 2002. Geviş getiren hayvanların iç hastalıkları. In: Gül Y, editor. *Sindirim sistemi hastalıkları*. Medipress Matbaacılık, Malatya, Türkiye, 1st ed., pp: 165-166.
- Drackley JK, Overton TR, Douglas GN. 2001. Adaptations of glucose and long-chain fatty acid metabolism in liver of dairy cows during the periparturient period. *J Dairy Sci*, 84(E. Suppl.): E100-E112.
- Durgut R, Ergün Y, Yaman M. 2003. Sığır akciğer, karaciğer ve üreme organ lezyonları üzerine bir mezbaha çalışması. *Vet Cer Derg*, 9: 27-30.
- Eulenberg VM, Lidbury JA. 2018. Hepatic fibrosis in dogs. *J Vet Intern Med*, 32: 26-41.
- Friedman S L. 2000. Molecular regulation of hepatic fibrosis, an integrated cellular response to tissue injury. *J Biol Chem*, 275(4): 2247-2250.
- Gargılı A, Tüzer E, Gülanber A, Toparlak M, Efil İ, Keleş V, Ulutaş M. 1999. Trakya'da kesilen koyun ve sığırlarda karaciğer trematod enfeksiyonlarının yaygınlığı. *Turkish J Vet Anim Sci*, 23: 115-116.
- Geelen MJ, Wensing T. 2006. Studies on hepatic lipidosis and coinciding health and fertility problems of high-producing dairy cows using the "Utrecht fatty liver model of dairy cows". A review. *Vet Q*, 28(3): 90-104.
- Gerspach C, Imhasly S, Klingler R, Hilbe M, Hartnack S, Ruetten M. 2017. Variation in fat content between liver lobes and comparison with histopathological scores in dairy cows with fatty liver. *BMC Vet Res*, 13: 98.
- Gözün H, Kıran MM. 1999. Konya mezbahalarında kesime alınan koyunların karaciğerinde patolojik incelemeler. *Veterinarium*, 10: 1-19.
- Gross JJ, Schwarz FJ, Eder K, et al. 2013. Liver fat content and lipid metabolism in dairy cows during early lactation and during a mid-lactation feed restriction. *J Dairy Sci*, 96(8): 5008-5017.
- Gross JJ. 2023. Hepatic lipidosis in ruminants. *Vet Clin Food Anim*, 39: 371-383.
- Grummer RR. 1993. Etiology of lipid-related metabolic disorders in periparturient dairy cows. *J Dairy Sci*, 76(12): 3882-96.
- Herdt TH. 1988. Fatty liver in dairy cows. *Vet Clin North Am, Food Anim Pract*, 4: 269-287.
- Imren HY, Şahal M. 2002. Sığır hastalıkları. In: Alaçam E, Şahal M, editors. *Sığır hastalıkları: Sindirim sistemi hastalıkları*. Medisan Yayınevi, Ankara, Türkiye, 2nd ed., pp: 85-89.
- Jorritsma R, Jorritsma H, Schukken YH, et al. 2000. Relationships between fatty liver and fertility and some periparturient diseases in commercial Dutch dairy herds. *Theriogenology*, 54(7): 1065-74.
- Jorritsma R, Jorritsma H, Schukken YH, et al. 2001. Prevalence and indicators of postpartum fatty infiltration of the liver in nine commercial dairy herds in the Netherlands. *Livest Prod Sci*, 68: 53-60.
- Kalaitzakis E, Panousis N, Roubies N, et al. 2010. Clinicopathological evaluation of downer dairy cows with fatty liver. *Can Vet J*, 51(6): 615-22.
- Metin N. 2011. *Veteriner patoloji*. Tuna Matbaacılık, Aydın, Türkiye, 1st ed., pp: 82-112.
- Milli ÜH, Hazıroğlu R. 1997. *Veteriner patoloji*. Tamer Matbaacılık, Ankara, Türkiye, 1st ed., pp: 143-204.
- Oruç E. 2009. Mezbahada kesilen sığırlarda karaciğer lezyonları

- üzerine histopatolojik bir çalışma. Atatürk Üniv Vet Bil Derg, 4: 97-104.
- Sağlam YS, Temur A, Aslan A. 2003. Detection of leptospiral antigens in kidney and liver of cattle. Dtsch Tierarztl Wochenschr, 110: 75-77.
- Sevinç M, Aslan V. 1998. Sütçü ineklerde doğum felcinin karaciğer yağlanması ile ilgisi. Turk J Vet Anim Sci, 22: 23-28.
- Stalker MJ, Hayes MA. 2007. Liver and biliary system, In "Jubb Kennedy and Palmer's pathology of domestic animals", In: Maxie MG, editor. Saunders/Elsevier, Philadelphia, USA, 5th ed., pp: 297-388.
- Suthar VS, Canelas-raposo J, Deniz A, Heuwiese W. 2013. Prevalence of subclinical ketosis and relationships with postpartum diseases in European dairy cows. J Dairy Sci, 96(5): 2925-2938.
- Şimşek S, Köroğlu E, Dumanlı N, Aktaş M, Şaki CE. 2005. Seroprevalence of cattle hydatidosis in some districts in the East Anatolian Region of Turkey. Turkish J Vet Anim Sci, 29: 1305-1310.
- Tadepalli S, Narayanan SK, Stewart GC, Chengappa MM, Nagaraja TG. 2009. Fusobacterium necrophorum: A ruminal bacterium that invades liver to cause abscesses in cattle. Anaerobe, 15: 34-36.
- Tigem, 2024. Damızlık büyükbaş (sığır) satış fiyatları. URL: <https://www.tigem.gov.tr/Folder/GosterimDetayDosyasi/a22043a5-1f68-43c9-a35b-e943783442ea.pdf>. (accessed date: January 15, 2025).
- Venjakob PL, Borchardt S, Heuwieser W. 2017. Hypocalcemia-Cow-level prevalence and preventive strategies in German dairy herds. J Dairy Sci, 100(11): 9258-9266.
- Wensing T, Kruij T, Geelen MJH, et al. 1997. Postpartum fatty liver in high-producing dairy cows in practice and in animal studies. The connection with health, production and reproduction problems. Comp Haematol Int, 7: 167-71.