

Treatment of Distal Radius Fractures by Intramedullar Nailing with Micronail®

Murat Çalbiyık¹

¹Hitit University Medicine Faculty Department of Orthopaedic and Traumatology Çorum, Turkey

Received: 25 December 2017, Accepted 26 March 2018, Published online: 20 April 2018
© Ordu University Institute of Health Sciences, Turkey, 2018

Abstract

Objective: Distal radius fractures are common fractures in the adult population. For treatment, intramedullary nailing has the advantage of providing effective internal fixation with minimum soft tissue damage. We aimed to present our experience with the use of intramedullary nailing device Micronail® (Wright Medical Technologies, Arlington, TN, USA) in the treatment of unstable extra-articular and simple intra-articular distal radius fractures.

Methods: Forty-three patients (mean age 54.7±10.8 years; 54.7% women) with unstable extra-articular and simple intra-articular distal radius fractures suitable for closed reduction (A21, A2.2, A23, A3, C2.1) were included in this retrospective study. Intramedullary distal radius fixation procedures were performed using Micronail® intramedullary nails in our clinic between February 2011 and January 2017. Clinical outcome measures were range of motion (ROM); visual analog scale (VAS); patient-reported Disabilities of the Arm, Shoulder and Hand [DASH] score; clinician-based Gartland–Werley score; radiographic Stewart score; radiographic parameters (radial inclination, volar tilt, radial height, radio-ulnar variance), and complications.

Results: The surgery lasted an average of 32.5±2.42 min. The mean postoperative follow-up duration was 31.4±5.8 weeks. Complete fracture union was obtained at 5.24±0.7 weeks. The postoperative VAS pain score was 2.4±1.2, which was remarkably low. The DASH score was 20±3.7, the Gartland–Werley score was 5.2±4.53, and the Stewart score was 1.7±1.4 on postoperative evaluation. ROM values were over 70° for all motions. Compared with the healthy side, the median loss in ROM was less than 17° for flexion, extension, pronation, and supination. In the postoperative radiological evaluations, there were significant increases in radial inclination ($p=0.005$), volar tilt ($p<0.001$), and radial height ($p<0.001$), and a decrease in radio-ulnar variance ($p=0.001$) compared to the preoperative values. Thirty patients (69.8%) had no postoperative complications, remaining 13 patients experienced minor complications that were treated effectively.

Conclusion: Intramedullary nailing with Micronail® is a minimally invasive technique, which provides effective and safe fixation of unstable extra-articular and simple intra-articular distal radius fractures.

Key words: Distal radius fractures, Intramedullary nail, Minimally invasive

Address for correspondence/reprints:

Murat Çalbiyık

Telephone number: +90 (532)769 89 62

E-mail: drmuratcalbiyik@hotmail.com

DOI: 10.19127/mbsjohs.370968

Introduction

Distal radius fractures are common fractures in the adult population (Liporace, 2009). Depending on the severity of the fracture and the needs of the patient, several operative and nonoperative treatment options have been used for the management of distal radius fractures. Operative management methods include closed reduction, external fixation, and open reduction with internal fixation, (Liporace et al., 2009, Bales and Stern, 2012). Intramedullary nailing has recently gained popularity in the treatment of extra-articular or

simple intra-articular distal radial fractures (Nishiwaki et al., 2011). This technique has the advantage of providing effective internal fixation with minimum soft tissue damage.

Micronail® (Wright Medical Technologies, Arlington, TN, USA) is a minimally invasive titanium locking screw fixation for two-part dislocated extra-articular fractures and average displaced intra-articular distal radius fractures. Since its introduction to the market in 2006, clinical studies have shown that use of Micronail® reduces soft tissue complications and provides fixed-angle support (Ilyas and Thoder, 2008; Geerts et al., 2011, van Vugt et al., 2010). However, these studies have been mostly preliminary reports with limited sample sizes. Therefore, a greater number of experiences should be published in order to reach a more precise consensus on the advantages and disadvantages of the Micronail® in the treatment of distal radius fractures.

In this study, we aimed to present our experience with the use of Micronail® in the treatment of unstable extra-articular and simple intra-articular distal radius fractures in a series of 43 patients.

Methods

Twenty-nine patients with unstable extra-articular and simple intra-articular distal radius fractures suitable for closed reduction (AO/OTA classification A21, A2.2, A23, A3, C2.1) were included in this retrospective study. Following closed reduction and circular casting, cases with volar tilt $>20^\circ$, articular incongruity >2 mm, radial inclination $>15^\circ$, and radial shortening >5 mm on radiographs were treated surgically. Intramedullary distal radius fixation procedures were performed using Micronail® intramedullary nails in our clinic between February 2011 and January 2017. The exclusion criteria were open or contaminated wounds; open physes; displaced intra-articular fragments; irreducible articular or extra-articular fractures; partial articular fractures involving the volar or dorsal rim (AO type 23); small and comminuted articular fragments that could not be reduced adequately by closed or percutaneous means; and fractures that extended proximally into the metaphyseal-diaphyseal bone.

The study was conducted in compliance with the Helsinki Declaration. The informed consent requirement was waived due to the retrospective design of the study.

Study parameters

The following data were retrieved from patients' files and recorded: demographics (age, gender), handedness, type of injury, type of distal radius fracture, concomitant fractures, duration of follow-up, length of hospital stay, total surgery and scopy time, and time to fracture healing. Clinical outcome measures were range of motion (ROM); visual analog scale (VAS); patient-reported Disabilities of the Arm, Shoulder and Hand [DASH] score; clinician-based Gartland–Werley score (Graham 1997); radiographic Stewart score (Stewart et al. 1984); radiographic parameters (radial inclination, volar tilt, radial height, radio-ulnar variance), and complications. The radiographic criteria of acceptable healing defined by Graham (Gartland and Werley 1951) were used for evaluation.

Operative techniques and postoperative follow-up

Micronail®-based intramedullary nailing was performed under local or general anesthesia with fluoroscopic control, with the patient in the supine position. First, closed reduction and temporary fixation were performed using a K-wire introduced from the ulnar side of the radius. Then, a 2-cm incision was made over the radial styloid process to create a cortical window between the first and second compartments, through which an appropriately sized implant was placed following the scraping process. Fixation was performed via three distal subchondral (locking) screws. A new incision 2 cm in length was made dorsally for proximal locking and fixated via two screws under fluoroscopy. The incision sites were then sutured.

Finger motion began immediately after surgery. Postoperative treatment consisted of a wrist splint for five days. Approximately one week after surgery, the splint was removed, and radiographs were taken. As long as there were no complications, load-carrying physical therapy was initiated. Clinical results were evaluated during a six-month follow-up consisting of four visits: three weeks, six weeks, 12 weeks, and six months after surgery.

Statistical analysis

Statistical analysis was performed using IBM SPSS Statistics for Windows, version 22.0 (IBM Corp., Armonk, NY, USA). Data were evaluated using the Shapiro–Wilk test for normality of distribution. A Chi-square or Fisher's exact test was used for comparing categorical data, while Student's

t test or the Mann–Whitney U test was used to compare continuous data according to the normality of the data. To compare preoperative and postoperative continuous variables, a paired t test or the Wilcoxon signed rank test was used according to the normality of the difference in variables. Data were expressed as mean±standard deviation and frequency (%) where appropriate. The statistical level of significance was set at $p < 0.05$.

Results

The mean age of the patients was 54.7 ± 10.8 years, and 54.7% were women. In most of the patients, the distal radius fracture was caused by a fall (65.5%). There was no concomitant fracture in 74.4% of the patients.

The surgery lasted an average of 32.5 ± 2.42 min. The mean postoperative follow-up duration was 31.4 ± 5.8 weeks. Complete fracture union was obtained at 5.24 ± 0.7 weeks (Table 1).

Table 1. Operational characteristics and outcome measures

	Study population (n=43)
Total surgery time (min)	32.5±2.42
Scopy time (min)	22.2±3.9
Duration of follow-up (week)	30.9±5.7
Length of hospital stay (day)	3.7±0.6
Time to fracture union (week)	5.24±0.7
VAS pain score	2.4±1.2
DASH score	20±3.7
Gartland–Werley score	5.2±5.3
Stewart score	1.7±1.4
ROM (°)	
Flexion	75.2±15.2
Extension	70.1±4.45
Pronation	78.7±15.1
Supination	80.3±5.2
Compliance to the radiographic healing criteria of Graham (1997)	
Radial inclination $< 15^\circ$	37 (86.04)
Volar tilt $< 20^\circ$	39 (90.7)
Articular incongruity (< 5 mm)	43 (100.0)

Data are given as mean±SD.

VAS, visual analog scale; DASH, Disabilities of the Arm, Shoulder and Hand

The postoperative VAS pain score was 2.4 ± 1.2 , which was remarkably low. The DASH score was 20 ± 3.7 , the Gartland–Werley score was 5.2 ± 4.53 , and the Stewart score was 1.7 ± 1.4 on postoperative evaluation (Table 1).

ROM values were over 70° for all motions (Table 1). Compared with the healthy side, the median loss in ROM was less than 17° for flexion, extension, pronation, and supination (Figure 1).

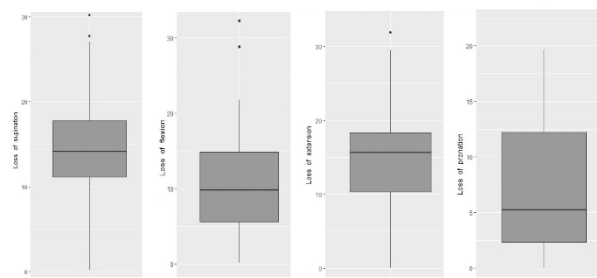


Figure 1. Loss of range of motion (ROM) compared to the healthy side for flexion, extension, pronation, and supination. The horizontal line within the box indicates the median; the boundaries of the box indicate the 25th and 75th percentile; and the whiskers indicate the highest and lowest values of the results. The mild outliers are indicated by dots.

In the postoperative radiological evaluations, there were significant increases in radial inclination ($p = 0.005$), volar tilt ($p < 0.001$), and radial height ($p < 0.001$), and a decrease in radio-ulnar variance ($p = 0.001$) compared to the preoperative values (Table 2).

Table 2. Radiographic outcome (n=29)

	Preoperative	Postoperative	p value
Radial inclination (°)	16.5±3.9	19.6±5.75	0.005
Volar tilt (°)	-12.1±11.3	6.7±6.1	<0.001
Radial height (mm)	3.1±2.8	9.6±1.7	<0.001
Radio-ulnar variance (mm)	2.7±1.8	1.08±0.86	0.001

The compliance rate to the radiographic criteria of Graham (1997) was over 80% for radial inclination, volar tilt, and articular incongruity (Table 1).

Thirty patients (69.8%) had no postoperative complications. Three patients experienced radial nerve paresthesia, and three other patients had infections. Tendon rupture and tenosynovitis were recorded in two patients, and Sudeck’s atrophy was observed in one patient. All postoperative complications were treated effectively.

Discussion

Distal radius fractures are common upper extremity fractures of adulthood with increasing prevalence, particularly in pediatric and elderly populations (Nellans et al. 2012). In most cases, distal radius fractures can be treated conservatively by non-operative methods such as closed reduction, splint, and circular casting. However, in conservative treatment by using non-operative methods, time to fracture union is long, and the risk of non-alignment and fracture displacement is high (Miller et al. 2005). For patients treated with non-

operative methods, full load-carrying capacity can be obtained very late. There are no well-defined criteria for the decision between operative and non-operative treatment, it depends on various factors such as severity and type of fracture, patient's needs, experience of surgeon, and surgical facilities of the clinic (Laino and Tejwani 2012, Obert et al. 2013). Currently, many surgical fixation methods, each achieving stable reduction with advantages and disadvantages, are present, but there is not enough evidence recommending one type of fixation over other (Obert et al. 2013, Diaz-Garcia and Chung 2012).

The surgical treatment options for distal radius fractures include open reduction and internal fixation with plates, and percutaneous or external fixation techniques (Obert et al. 2013, Diaz-Garcia and Chung 2012, Othman 2009). Among these options, the Micronail® is an intramedullary titanium pin used for internal fixation of unstable extra-articular and simple intra-articular distal radius fractures. It has the advantages of providing support by locking screws and minimally invasive intramedullary surgical technique sparing surrounding soft tissues (Geerts et al. 2011). Although the Micronail® is advantageous, studies documenting the results of this technique are limited. In our clinic, we have been applying intramedullary fixation with the Micronail® since 2011. We usually treat distal radius fractures conservatively by closed reduction and circular casting. However, we apply surgical treatment for cases that show high volar tilt, articular incongruity, radial inclination, and radial shortening on radiographs following conservative treatment. In these cases, if the distal radius fracture is unstable extra-articular or simple intra-articular, we perform open reduction and intramedullary fixation with the Micronail®. In this article, we presented our experience with the Micronail® in a retrospective series of 29 patients.

Fixation of distal radius fractures by intramedullary nailing has been introduced in the last decade (Ilyas and Thoder 2008). Initial reports indicated good functional and radiological outcome, but high rate of postoperative complications (Ilyas and Thoder 2008, Dremstrup et al. 2013). The improved technology of Micronail® allowed minimally invasive surgery, and decreased soft tissue injury and related complications. The limited number of previous studies evaluated the efficacy and safety of internal fixation of distal radius fractures with the Micronail® (Geerts et al. 2011, van

Vugt et al. 2010, Tajima et al. 2012). In a series of 18 patients with 20 two-part dislocated extra-articular and average displaced intra-articular distal radius fractures, van Vugt et al. (van Vugt et al. 2010) showed that all fractures healed without major loss of alignment without major complication. Geerts et al. (Geerts et al. 2011) applied the Micronail® in 10 patients with A2 or A3 distal radius fractures, and obtained union in all patients without loss of alignment. Short immobilization period of 5 days was reported to be sufficient, after which full load-carrying exercises should be initiated (Geerts et al. 2011). The Micronail® allows early mobilization and return to daily life. Dremstrup et al., (Dremstrup et al. 2013) performed fixation of 60 A2 and A3 distal radius fractures by using the Micronail®, and reported that all fractures healed, with an average radial volar tilt of 2°, radial length of 11 mm, and a radial inclination of 22. They concluded that the Micronail® provides a stable fixation of selected distal radius fractures, and good functional and radiological outcome with minimum complications. In a randomized study, Schønnemann et al. (Schønnemann et al. 2011) compared the clinical and radiological outcomes of external fixation with Hoffmann II compact non-bridging in 30 patients and internal fixation with the Micronail® in 31 patients. They found that the Micronail® provided significantly better grip strength, but longer operation time compared to external fixation. Radiological outcome was similar between two fixation methods (Schønnemann et al. 2011). Nishiwaki et al. (Nishiwaki et al. 2011) also applied the Micronail® in 31 patients with dorsally displaced unstable distal radial fracture, and reported that on the radiographs obtained at one year after the surgery, radial inclination was 25°, volar tilt 11°, radial length 10 mm, and ulnar variance 1 mm. They concluded that this technique is an effective treatment for extra-articular or simple intra-articular distal radial fracture causing minimal complications. Similar to previous reports, in the present study, our patient population consisted of unstable extra-articular and simple intra-articular distal radius fractures suitable for closed reduction. The operation duration was 32.5±2.42 min on average, which is shorter than around 1 hour reported in literature (van Vugt et al. 2010). We followed patients for 30.9±5.7 weeks after the surgery, and obtained complete fracture union in all patients at 5.24±0.7 weeks. The postoperative VAS pain score was 2.4±1.2, which was remarkably low. In the study by Geerts et al. (Geerts et al. 2011), the postoperative pain was also

reported to be low with a VAS score of 1.3. The DASH, Gartland-Werley, and Stewart scores indicated that the Micronail® provided good clinical and radiological outcome as reported in literature. In comparison to healthy side, the median loss in ROM was less than 17° in all directions, which was slightly higher than the previously reported 10° difference between two wrists (Geerts et al. 2011, van Vugt et al. 2010). Similar to the previous studies, we obtained good radiological outcome on radiographs obtained in the last assessment. Accordingly, radial inclination was 19.6°, volar tilt was 6.7°, radial height was 9.6 mm, and ulnar variance was 1.08 mm. In our series, most patients did not experience any postoperative complications, while the remaining patients had minor and treatable complications. Our results supported the present knowledge that intramedullary nailing with the Micronail® provides safe and effective fixation of selected distal radius fractures with the advantage of minimum soft tissue damage.

The main limitation of our study was its non-comparative retrospective design and small sample size. Nevertheless, given the limited number of studies in literature on the Micronail®, we think that our present experience on this device would contribute to the literature and clinical management of distal radius fractures.

Conclusion

In conclusion, arthroscopic reduction and internal in conclusion, intramedullary nailing with Micronail® is a minimally invasive technique, which provides effective and safe fixation of unstable extra-articular and simple intra-articular distal radius fractures.

Ethics Committee Approval: The requirement for the ethics committee approval was waived for the retrospective design and valid legal regulations at the time of the study.

Peer-review: Externally peer-reviewed.

Author Contributions: Idea- M.Ç.; Design M.Ç.; Supervision- M.Ç.; Funding- M.Ç.; Materials- M.Ç.; Data Collection/Data Process- M.Ç.; Analyze or Comment- M.Ç.; Literature Scanning- M.Ç., T.D.; Writer of Paper- M.Ç.; Critical Review- M.Ç.

Conflict of Interest: No conflict of interest was declared by the author.

Financial Disclosure: The authors declared that this study has received no financial support.

References

- Bales JG, Stern PJ. Treatment strategies of distal radius fractures. *Hand Clin* 2012; 28: 177-84.
- Diaz-Garcia RJ, Chung KC. Common myths and evidence in the management of distal radius fractures. *Hand Clin* 2012; 28: 127-33.
- Dremstrup L, Skjærbæk MS, Olesen S, Høgh A, Hansen TB. Good radiological and functional results after intramedullary nailing of distal radius fractures. *J Plast Surg Hand Surg* 2013; 47: 286-8.
- Gartland JJ Jr, Werley CW. Evaluation of healed Colles' fractures. *J Bone Joint Surg Am* 1951; 33: 895-907.
- Geerts RW, Toonen HG, van Unen JM, van Vugt R, Werre AJ. A new technique in the treatment of distal radius fractures: The Micronail®. *Acta Orthop Traumatol Turc* 2011; 45: 85-93.
- Graham TJ. Surgical correction of malunited fractures of the distal radius. *J Am Acad Orthop Surg* 1997; 5: 270-81.
- Ilyas AM, Thoder JJ. Intramedullary fixation of displaced distal radius fractures: a preliminary report. *J Hand Surg Am* 2008; 33: 1706-15.
- Laino DK, Tejwani N. Indications for operative fixation of distal radius fractures: a review of the evidence. *Bull NYU Hosp Jt Dis* 2012; 70: 35-40.
- Liporace FA, Adams MR, Capo JT, Koval KJ. Distal radius fractures. *J Orthop Trauma* 2009; 23: 739-48.
- Miller BS, Taylor B, Widmann RF, Bae DS, Snyder BD, Waters PM. Cast immobilization versus percutaneous pin fixation of displaced distal radius fractures in children: a prospective, randomized study. *J Pediatr Orthop* 2005; 25: 490-4
- Nellans KW, Kowalski E, Chung KC. The epidemiology of distal radius fractures. *Hand Clin* 2012; 28: 113-25.
- Nishiwaki M, Tazaki K, Shimizu H, Ilyas AM. Prospective study of distal radial fractures treated with an intramedullary nail. *J Bone Joint Surg Am* 2011; 93: 1436-41.
- Obert L, Rey PB, Uhring J, Gasse N, Rochet S, Lepage D, et al. Fixation of distal radius fractures in adults: a review. *Orthop Traumatol Surg Res* 2013; 99: 216-34.
- Othman AY. Fixation of dorsally displaced distal radius fractures with volar plate. *J Trauma* 2009; 66: 1416-20.

- Schønnemann JO, Hansen TB, Søballe K. Randomised study of non-bridging external fixation compared with intramedullary fixation of unstable distal radial fractures. *J Plast Surg Hand Surg* 2011; 45: 232-7.
- Stewart HD, Innes AR, Burke FD. Functional cast bracing for Colles' fractures. A comparison between cast bracing and conventional plaster casts. *J Bone Joint Surg (Br)* 1984; 66: 749-53.
- Tajima K, Koba T, Takao E. A simple reduction technique in intramedullary nailing (MICRONAIL) of distal radius fracture--intrafocal elastic-spring pinning method. *Hand Surg* 2012; 17: 279-85.
- van Vugt R, Geerts RW, Werre AJ. Osteosynthesis of distal radius fractures with the Micronail. *Eur J Trauma Emerg Surg* 2010; 36: 471-6.