



## Intrarenal Segmentation of the Renal Arteries in the Konya Merino

Hülya BALKAYA<sup>1</sup>, Derviş ÖZDEMİR<sup>1</sup>, Zekeriya ÖZÜDOĞRU<sup>1</sup>✉, Yohannes Ayalew  
HAILEMICAEL<sup>1</sup>

1. Ataturk University, Faculty of Veterinary Medicine, Department of Anatomy, Erzurum, TURKEY.

Geliş Tarihi/Received	Kabul Tarihi/Accepted	Yayın Tarihi/Published
15.06.2017	02.08.2017	25.04.2018

**Bu makaleye atıfta bulunmak için/To cite this article:**  
**Balkaya H, Özdemir D, Özudođru Z, HAILEMICAEL YA:** Intrarenal Segmentation of the Renal Arteries in the Konya Merino. *Atatürk Üniversitesi Vet. Bil. Derg.*, 13 (1): 6-12, 2018. DOI: 10.17094/ataunivbd.321550

**Abstract:** Arterial distribution of Konya merino's kidneys were investigated using dissection and corrosion cast techniques. Eight kidneys were used in the study. It was observed that the kidneys were vascularized by a. renalis, which separated as a single branch from aorta abdominalis. The origin of the a. renalis dextra was determined in cranial from the a. renalis sinistra. A. renalis sinistra was found longer and thicker structure than a. renalis sinistra. The renal artery was divided into two main branch (dorsal and ventral) after entering the hilum renis. However, half of the material had a third branch of the left artery. These branches, in both kidney was separated 2-4 pieces aa. interlobares. Dorsal and ventral branches did not show anastomosis between segments.

**Keywords:** Intrarenal segmentation, Konya Merino, Ren.

## Konya Merinosunda Aa. Renales'in Intrarenal Segmentasyonu

**Öz:** Konya merinosu koyun ırkı böbreklerinin arter dağılımı, diseksiyon ve korozyon kast teknikleri kullanılarak araştırıldı. Çalışmada 8 adet böbrek kullanıldı. Böbreklerin aorta abdominalis'den tek bir dal olarak ayrılan a. renalis'ler tarafından vaskularize edildiği gözlemlendi. A. renalis dextra'nın a. renalis sinistra'dan daha cranial'den orijin aldığı belirlendi. A. renalis sinistra'nın, a. renalis dextra'dan daha uzun ve daha kalın bir yapıda olduğu görüldü. Böbrek arteri hilus renalis'e girdikten sonra iki ana dala (dorsal ve ventral) ayrılmaktaydı. Ancak, materyallerin yarısında sol arterden üçüncü bir dal çıkmaktaydı. Bu dalların her iki böbrekte 2-5 adet a. interlobares'e ayrıldığı saptandı. Dorsal ve ventral dallar ile segmentleri arasında anastomoz görülmedi.

**Anahtar Kelimeler:** Intrarenal segmentasyon, Konya merinosu, Ren.

## INTRODUCTION

Many mammalian species, experimental urology and organ transplantations have been used as experimental animals in the study of variable diagnostic or surgical techniques. Studies on rat (1-2), rabbit (3-6), guinea pig (7), dog (8-11), sheep (12-14), human (15-16), pig (17-18), wild animals (19-20) kidneys were performed. For this reason, the aim of this study is to investigate the variations of renal arteries as the first experimental study to raise awareness among surgeons during kidney removal or transplantation in the Konya Merino sheep. In addition to these, will also contribute to the work to be done in this area.


## MATERIALS and METHODS

Eight adult Konya merino sheep was used in this study. Kidneys were taken with kidney arteries, then 20% powdered monomethyl-methacrylate and 80% liquid polymethyl-methacrylate were prepared by injection of the prepared takilon. The method of casting corrosion (21-22) was applied to kidneys. For polymerization, the materials were kept at room temperature for 24 hours. They were exposed to corrosion in 30% KOH at 60° C for 24 hours and 48 hours. After dissolution of the soft tissues, the remainder was removed from the corrosion casts in flowing water. Then the corrosion casts was dried at room temperature. These materials were photographed. An electronic calibrator was used for the measurements. The study was conducted in accordance with the ethical principles for animal experiments.

## RESULTS


In the Konya merino sheep, each kidney has only a single renal artery arising from the ventral walls of the aorta abdominalis and entered it via its hilum. It was determined that arteria renalis sinistra was longer and thicker than arteria renalis dextra. It was observed that the origin of arteria renalis dextra was located cranially to the origin of arteria renalis sinistra. The average diameter of aorta abdominalis was 15.05 mm. The mean length of the distance

between the right and left renal arteries was 12.22 mm. (Figure 1-2).



**Figure 1:** Dorsal view of the renal arteries.

**Şekil 1:** Renal arterlerin dorsal'den görünümü. A-abdominal aorta, R-right renal artery, L-left renal artery.

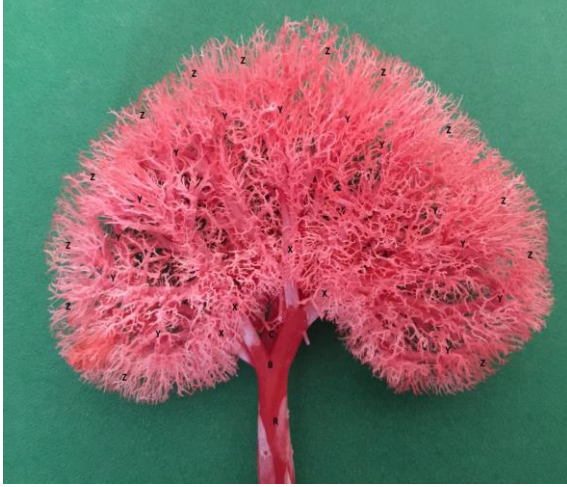

**Figure 2:** Ventral view of the renal arteries.

**Şekil 2:** Renal arterlerin ventral'den görünümü.

Arteria renalis dextra was 43.2-46.9 mm in the hilum of the kidney and 47.4-50.1 mm in the arteria renalis sinistra, giving dorsal and ventral branches. The average diameter of arteria renalis dextrawas

9.97 mm and the average diameter of arteria renalis sinistra 9.67 mm (Figure 3-4).



**Figure 3:** Dorsal view of the right renal artery.

**Şekil 3:** Sağ renal arterin dorsal'den görünümü.

R-right renal artery, B-right dorsal branch, C-right ventral branch, X-interlobar artery, Y-arcuate artery, Z- interlobular artery.



**Figure 4:** Ventral view of the right renal artery.

**Şekil 4:** Sağ renal arterin ventral'den görünümü.

R-right renal artery, B-right dorsal branch, C-right ventral branch, X-interlobar artery, Y-arcuate artery, Z- interlobular artery.

The right dorsal branches were about 8.32 to 9.41 mm in diameter and 16.85 to 19.65 mm in length. These vessels were giving three or five right arteriae interlobares (Figure 3). The left dorsal branches were about 9.12 to 9.22 mm in diameter and 17.24 to 17.44 mm in length. These arteries were giving four or five left arteriae interlobares (Figure 4).

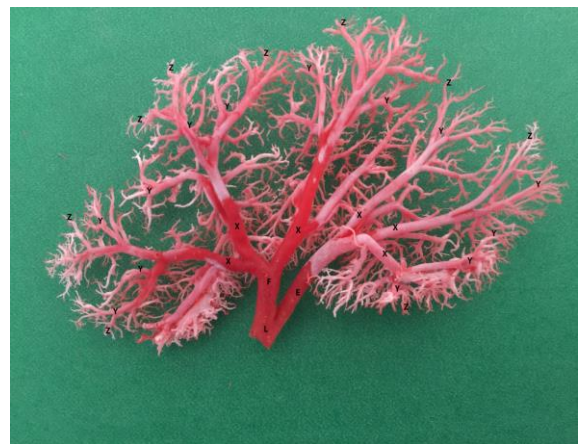The right ventral branch was about 8.31 to 9.72 mm in diameter and 14.57 to 15.01 mm in length and ramified as three–four right arteriae interlobares (Figure 5). The left ventral branch was about 8.79 to 8.82 mm in diameter and 13.05 to 13.6 mm length and ramified as four–five left arteriae interlobares (Figure 6). In the left kidneys, half of the material had a third branch (intermediary branch) emerged from the junction of the dorsal and ventral branches. This branch was separated 2-4 pieces aa. interlobares (Figure 7-8).



**Figure 5:** Dorsal view of the left renal artery.

**Şekil 5:** Sol renal arterin dorsal'den görünümü.

L-left renal artery, E-left dorsal branch, F-left ventral branch, X-interlobar artery, Y-arcuate artery, Z- interlobular artery.

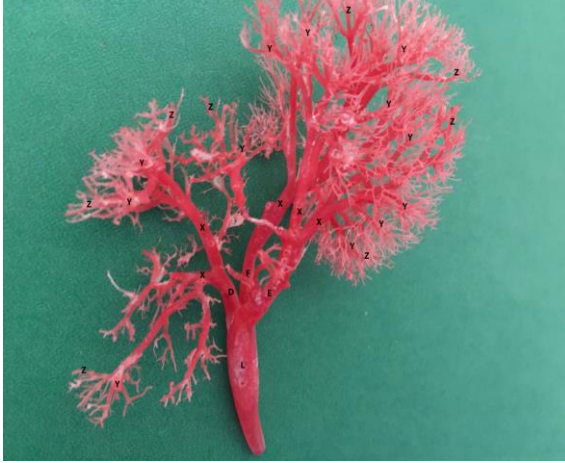

**Figure 6:** Ventral view of the left renal artery.

**Şekil 6:** Sol renal arterin ventral'den görünümü.

L-left renal artery, E-left dorsal branch, F-left ventral branch, X-interlobar artery, Y-arcuate artery, Z- interlobular artery.

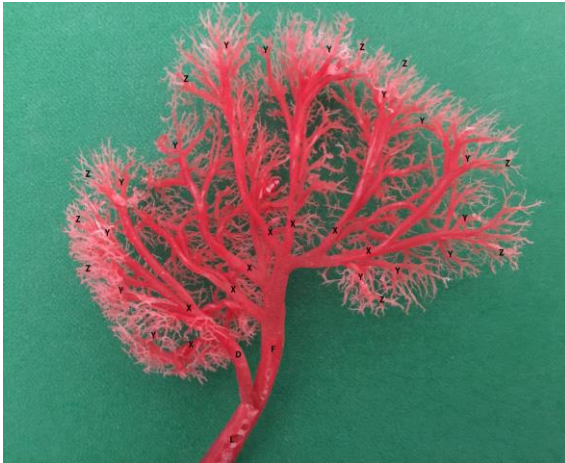



**Figure 7:** Dorsal view of the left intermediary renal artery.

**Şekil 7:** Sol intermedier renal arterin dorsal'den görünümü.

L-left renal artery, E-left dorsal branch, F-left ventral branch, D-left intermediary branch, X-interlobar artery, Y-arcuate artery, Z- interlobular artery.



**Figure 8:** Ventral view of the left renal artery.

**Şekil 8:** Sol renal arterin ventral'den görünümü.

L-left renal artery, F-left ventral branch, D-left intermediary branch, X-interlobar artery, Y-arcuate artery, Z- interlobular artery.

Arteriae interlobares gave off arteriae arcuate that arch over the base of the medullary pyramids at medulla-cortex junction. The arteriae interlobular originating from the arteria arcuate feed the entire surface of the kidney. None of the materials had anastomosis.

## DISCUSSION and CONCLUSION

In the present study, we observed that the arteriae renales originate from the ventral surface of the aorta abdominalis, this finding which was in agreement with that described by Ghoshal (23). However, in some literature (1,13,24-25) observed that arteriae renales originate from both sides of the aorta abdominalis.

It was determined that the arteria renalis sinistra was longer than the arteria renalis dextra in the examined materials, confirming observations of Nickel et al (26) in cattle, Aksoy and Ozudogru (27) in Van cat, Ozudogru and Ozdemir (28) in wolf, Mohamed (25) in Baladi rabbit. However, it was reported that in Kangal dog (11), in one humped camel (29), in Tuj sheep (13) and in horse (26), the arteria renalis dextra was longer than the arteria renalis sinistra.

In some studies, it was determined that double arteriae renales were in the Baladi rabbits and they were only on the left side (30-31) has also reported that similar findings, While Christensen (32), Shively (10) and Wiland and Indykiewicz (33) observed that double arteriae renales on the both sides. Kurtul et al. (8) in a cadaver of the German shepherd dogs and Wiland and Indykiewicz (33) in 20.0% of dogs stated that arteria renalis dextra is doubled. Loukas et al. (34) stated that there are three arteriae renales on the right side and one accessory arteria renalis originated as a common trunk with the inferior mesenteric artery on the right side. In the present study, there were one arteria renalis for the right and left kidney originating from the aorta abdominalis.

In this study, the primary divisions of arteriae renales were a dorsal and a ventral branch, as also reported in Kangal dog (11), wolf (28), Tuj sheep (13), mole rats (2). Later, the dorsal and ventral branches of the arteriae renales gave more than one arteria renalis. Mazensky and Flesarova (7) have also reported that the bilateral a. renalis was terminally divided into two, three or four branches in different ratio according to the side.

We observed that interlobar arteries give arteriae arcuate at medulla-cortex junction, as reported for sheep (12-13), wolf (28), dog (11, 35-36) and cat (27).

The right dorsal branch is divided into three five interlobular sub-branches, the right ventral is divided into three four interlobar sub-branches. On the other hand, the left dorsal branch is divided into four to five and the left ventral branch is divided into four to five sub branches. The arteria renalis sinistra was giving a third branch besides the dorsal and ventral branch. This branch also gave a dorsal and ventral sub branch. Aksoy et al. (13) reported that the right dorsal branch separated into three interlobar sub-branches, the right ventral branch divided into four interlobar branches, the left dorsal branch divided into three sub-branches, and the left ventral branch gave three or four arteriae interlobares. In the one Morkaraman sheep and one goat kidneys, dorsal branch gave two arteriae interlobares for the ventral surface and the ventral branch delivered one arteria interlobaris for the dorsal surface kidney (12). In the kidneys of Tuj sheep, in a right kidney, there is a third branch that feeds the dorsal surface of the kidney and at the junction of the dorsal and ventral branches. In the left kidney, an arteria interlobaris arising from the dorsal branch, feeding the end portion of the ventral surface (13).

Number of studies (11, 13, 27-28, 37-39) on the distribution of arteriae renales, it was stated that no anastomosis was observed between the arteries, although in the Morkaraman sheep kidneys, it was mentioned that an anastomosis between a dorsal and ventral branches and two arteriae interlobares originating directly from the arteria renalis (12). In one kidney of Wistar rat, an anastomosis between the dorsal and ventral branches (40). No anastomosis between the kidney arteries was observed in this study.

Considering that the best anatomic region for kidney implantation depends on the anatomical characteristics of the kidneys (the length of the blood vessels and the number of blood vessels as well as

the urinary ring), we believe that such studies will contribute to this area.

#### REFERENCES

1. Yoldas A, Dayan MO., 2014. Morphological characteristics of renal artery and kidney in rats. *Sci World J*, doi: 10.1155/2014/468982.
2. Yoldas A., Aydin A., Ilgun R., 2014. Macroscopic distribution of the renal artery and intrarenal arteries in mole rats (*Spalax leucodon*). *Vet Med*, 59, 382-387.
3. Mazensky D., Purzyc H., Danko J., 2012. Variation in the vascular anatomy of the rabbit kidney and its experimental significance. *Acta Sci Pol Med Vet*, 11, 25-34.
4. Shalgum A., Marques-Sampaio BPS., Dafalla A., Pereira-Sampaio MA., 2011. Anatomical relationship between the collecting system and the intrarenal arteries in the rabbit: contribution as an experimental model. *Anat Histol Embryol*, 41, 130-138.
5. Sindel M., Ucar Y., Ozkan O., 1990. Renal arterial system of the domestic rabbits (*Oryctolagus cuniculus*): Corrosion cast study. *Journal of the Anatomical Society of India*, 39, 31-40.
6. Supuka P., Mazensky D., Danko J., Supukova A., Petrovova E., 2014. Anatomical description of the renal arteries and veins in the European rabbit. *Biologia*, 69, 1059-1064.
7. Mazensky D., Flesarova S., 2017. Arrangement of renal arteries in guinea pig. *Anat Record*, 300, 556-559.
8. Kurtul I., Dursun N., Ozcan S., 2002. Relation of arterial vascularization of the kidney and the adrenal gland of the German shepherd dogs. *Istanbul Univ Vet Fak Derg*, 28, 65-71.
9. Marques-Sampaio BPS., Pereira-Sampaio MA., Henry RW., Favorito LA., Sampaio FJ., 2007. Dog kidney: anatomical relationships between intrarenal arteries and kidney collecting system. *Anat Record*, 290, 1017-1022.
10. Shively MJ., 1978. Origin and branching of renal arteries in the dog. *J Am Vet Med Assoc*, 173, 986-

- 989.
11. Ozdemir D., Ozudogru Z., Malkoc I., 2009. Intrarenal segmentation of the renal arteries in the Kangal dog. *Kafkas Univ Vet Fak Derg*, 15, 41-44.
  12. Aslan K., Nazli MA., 2001. Comparative macro-anatomic investigation on the intrarenal segmentation of the renal artery in goats and morkaraman sheep. *Indian Vet J*, 78, 139-143.
  13. Aksoy G., Kurtul I., Ozcan S., Aslan K., Ozudogru Z., 2004. Intrarenal arteries and their patterns in the Tuj sheep. *Vet Med*, 49, 57-60.
  14. Buys-Goncalves GF., Souza DB., Sampaio FJB., Pereira-Sampaio MA., 2016. Anatomical relationship between the kidney collecting system and the intrarenal arteries in the sheep: Contribution for a new urological model. *Anat Rec (Hoboken)*, 299, 405-411.
  15. Rani N., Singh S., 2014. Surgical importance of arterial segments of human kidneys: an angiography and corrosion cast study. *J Clin Diagnos Res*, 8, 1-3.
  16. Mahalakshmi R., Kumar DD., Kumari KR., Sekharan CB., 2016. Morphological Study of Renal Arteries in South Indian Population. *Saudi J Med*, 1, 76-81.
  17. Pereira-Sampaio MA., Favorito LA., Sampaio FJB., 2004. Pig kidney: anatomical relationships between the intrarenal arteries and the kidney collecting system. Applied study for urological research and surgical training. *J Urol*, 17, 2077-2081.
  18. Pereira-Sampaio MA., Favorito LA., Henry RW., Sampaio FJ., 2007. Proportional analysis of the pig kidney arterial segments. *J Endourol*, 21, 784-788.
  19. Hadziselimovic H., Cus M., 1975. Blood vessels and excretory apparatus of the kidney in some wild animals. *Acta Anat (Basel)*, 91, 71-82.
  20. Atalar O., Yilmaz S., 2004. Macroanatomical investigation of the renal arteries in the porcupines (*Hystrix cristata*). *Firat University, J Health Sci*, 18, 51-53.
  21. Nerantsiz C., Antonakis E., Avgoustakis D., 1978. A new corrosion casting technique. *Anat Rec*, 191, 321-325.
  22. Tompset DH., 1970. *Anatomical Techniques*. 2nd ed. E. and S. Livingstone, Edinburg and London.
  23. Ghoshal NG., 1975. Ruminant heart and arteries. In "Sisson and Grossman's the Anatomy of the Domestic Animals", Ed., R Getty, 5th ed., 528, W.B. Saunders Company, Philadelphia.
  24. Nickel R., Schummer A., Seiferle E., 1981. *The Anatomy of the Domestic Animals*. Vol. 3, Verlag Paul Parey, Berlin and Hamburg.
  25. Mohamed RAA., 2014. Double renal artery in Baladi rabbit. *Inter j Vet Sci*, 33, 105-108.
  26. Nickel R., Scummer A., Seiferle E., 1979. *The viscera of domestic animals*, 294, Springer, New York,
  27. Aksoy G., Ozudogru Z., 2003. A macroscopical investigation on the intrarenal segmentation of the renal arteries in the Van cat. *J Faculty Vet Med Kafkas Univ*, 9, 9-13.
  28. Ozudogru Z., Ozdemir D., 2005. Intrarenal arterial patterns in the wolf. *Vet Med*, 50, 411-414.
  29. Paryani MR., 2012. Intrarenal patterns of the vascular supply in one humped camel (*Camelus dromedarius*). *Ann Biolog Res*, 3, 4947-4950.
  30. Mazensky D., Purzyc H., Danko J., 2012. Variation in the vascular anatomy of the rabbit kidney and its experimental significance. *Acta Sci Pol, Med Vet*, 11, 25-34.
  31. Nowicki W, Brudnicki W, Iwanczyk M., Jabłoński R., Skoczylas B., 2010. Branches of the abdominal aorta in European rabbit. *EJPAU*, 13, 10.
  32. Christensen GC., 1952. Circulation of blood through the Canine Kidney. *Am J Vet Res*, 13, 236-245.
  33. Wiland C., Indykiewicz P., 1999. Multiple renal arteries (Aa. renales) in mink and dog. *Electronic Journal of Polish Agricultural Universities*, 2, 14.
  34. Loukas M., Aparicio S., Beck A., 2005. Rare case of right accessory renal artery originating as a commontrunk with the inferior mesenteric artery: a case report. *Clin Anat*, 18, 530-535.
  35. Aslan K., 1995. Macroanatomic investigations on

- the intrarenal segmentation of the renal artery in the Mongrel Dog. *Eur J Vet Sci*, 11, 149-154.
36. Khamanarong KP., Prachaney A., Utraravichien T., Tong U., Sripaoraya K., 2004. Anatomy of renal arterial supply. *Clin Anat*, 17, 334-336.
37. Evan AP., Connors BA., Lingeman JE., Blomgren P., Willis LR., 1996. Branching patterns of the renal artery of the pig. *Anat Rec*, 246, 217-23.
38. Marques-Sampaio BP., Pereira-Sampaio MA., Henry RW., Favorito LA., 2007. Dog kidney: anatomical relationships between intrarenal arteries and kidney collecting system. *Anat Rec*, 290, 1017-1022.
39. Pereira-Sampaio MA., Marques-Sampaio BPS., Henry RW., Favorito LA., Sampaio FJB., 2009. The dog kidney as experimental model in endourology: anatomic contribution. *J Endourol*, 23, 989-993.
40. Nur IH., Yoldas A., 2011. The branches variation of the renal artery in a Wistar rat. *J Faculty of Vet Med, Erciyes Univ*, 8, 211-216.