

Oral hairy leukoplakia in the buccal mucosa of a healthy, HIV-negative patient

Sağlıklı, HIV negatif bir hastada bukkal mukozada oral kıllı lökoplaki

Gülhan Gürel¹, Sevinç Şahin², Betül Aytekin², Emine Çölgeçen¹

¹ Department of Dermatology, Bozok University School of Medicine, Yozgat, Turkey
² Department of Pathology, Bozok University School of Medicine, Yozgat, Turkey

ORCID ID of the authors
GG: 0000-0001-5716-8750
SS: 0000-0002-9409-8138
BA: 0000-0002-2120-6855
EÇ: 0000-0001-9651-6068

Abstract

Oral hairy leukoplakia (OHL), first described in 1984, is an Epstein-Barr virus lesion located laterally in the tongue and manifesting as a white, asymptomatic mucosal plaque which cannot be removed by scraping. OHL is more commonly observed in HIV-positive patients, in immunosuppressed patients after kidney, heart, liver and bone marrow transplantation, in hematological malignancies such as multiple myeloma, and in patients undergoing systemic or topical steroid therapy. OHL has rarely been reported in healthy patients who are not immunosuppressive. The case of an otherwise healthy, HIV-negative 24 year-old woman with OHL lesions in the buccal mucosa is presented here because of its rarity.

Keywords: Oral hairy leukoplakia, HIV-negative patient, Buccal mucosa

Öz

İlk olarak 1984'te tanımlanan oral kıllı lökoplaki (OKL), sıklıkla dil lateralde yerleşen kazınamayan beyaz renkli, asemptomatik mukozal plak olarak kendini gösteren bir Epstein-Barr virüsü lezyonudur. OKL daha çok HIV pozitif hastalarda bulunurken, böbrek, kalp, karaciğer ve kemik iliği transplantasyonu sonrası immünsüpresif hastalarda, multipl miyelom gibi hematolojik malignitelerde ve sistemik veya topikal steroid tedavisi altındaki hastalarda da tanımlanmıştır. Literatürde OKL, nadiren immünsüpresif olmayan sağlıklı hastalarda da bildirilmiştir. Burada, 24 yaşında diğer açılardan sağlıklı, HIV negatif, bukkal mukozada OKL lezyonu olan kadın hasta nadir görülmesi nedeniyle sunulmaktadır.

Anahtar kelimeler: Oral kıllı lökoplaki, HIV-negatif hasta, Bukkal mukoza

Introduction

Oral hairy leukoplakia (OHL), first described in 1984 in homosexual male patients by Greenspan et al. [1], is an Epstein-Barr virus (EBV) lesion located laterally in the tongue and manifesting as a white, asymptomatic mucosal plaque which cannot be removed by scraping [2]. The prevalence of OHL reported among human immunodeficiency virus (HIV) positive individuals is as high as 53% [3]. Despite being mostly observed in HIV-positive patients, OHL has also been described in immunosuppressive patients after renal, heart, liver and bone marrow transplantation, in hematological malignancies such as multiple myeloma, and in patients undergoing systemic or topical steroid therapy [2,4]. OHL has rarely been reported in healthy patients who are not immunosuppressive. In these reports, the definition of healthy includes patients with no history of underlying medical illness or immunosuppressive treatment [4,5].

We describe a case of an otherwise healthy, HIV-negative 24 year-old woman with OHL lesions in the buccal mucosa because of its rarity.

Case presentation

A 24-year-old female patient was admitted to our clinic due to white spots in her mouth for about 3 years. Her history revealed that these white spots never resolved entirely and caused no symptoms other than a mild burning sensation. She had no history of disease other than hypothyroidism. The patient was receiving levothyroxine sodium medication, and did not smoke or drink alcohol. There were no reports of previous use of immunosuppressive drugs or steroids. Dermatologic examination revealed slightly elevated, linear white plaques on the bilateral buccal mucosa, which could not be removed by scraping (Figure 1).

Corresponding author / Sorumlu yazar:

Gülhan Gürel

Address / Adres: Bozok Üniversitesi, Tıp Fakültesi, Dermatoloji Bölümü, 66200, Yozgat, Türkiye

e-Mail: gulhanozturkgurel@hotmail.com

Informed Consent: The author stated that the written consent was obtained from the patient presented in the study.

Hasta Onamı: Yazar çalışmada sunulan hastadan yazılı onam alındığını ifade etmiştir.

Conflict of Interest: No conflict of interest was declared by the authors.

Çıkar Çatışması: Yazarlar çıkar çatışması bildirmemişlerdir.

Financial Disclosure: The authors declared that this study has received no financial support.

Finansal Destek: Yazarlar bu çalışma için finansal destek almadıklarını beyan etmişlerdir.

Received / Geliş tarihi: 04.04.2018

Accepted / Kabul tarihi: 19.04.2018

Published / Yayın tarihi: 19.04.2018

Copyright © JOSAM



Incisional biopsy specimens were taken from the lesions. Histopathological examination revealed hyperkeratosis and parakeratosis in the keratin layer (Figures 2-3). Papillomatosis in the squamous epithelium, evident pseudoepitheliomatous hyperplasia, and balloon-like cells with large vacuolar cytoplasm were also observed (Figure 2-3). No evidence of dysplasia or malignancy was present. Diffuse nuclear positivity in squamous epithelium was observed at immunohistochemical examination using EBV antibody (Figure 4), while HPV and p16 were negative. No fungal microorganisms were observed at histochemical examination with PAS staining.

The patient was assessed by the Department of Internal Medicine in terms of possible underlying immunosuppressive diseases. General physical examination revealed no pathological findings. Laboratory tests were within normal limits. The serological test for HIV antibody was negative. The patient was started on 2 x 500 mg valaciclovir with a diagnosis of OHL. At follow-up after 1 week, the lesions appeared completely regressed (Figure 5). The current treatment was maintained for 3 more weeks and then terminated. There was no recurrence in the first month of follow-up. The patient is still attending regular follow-ups.

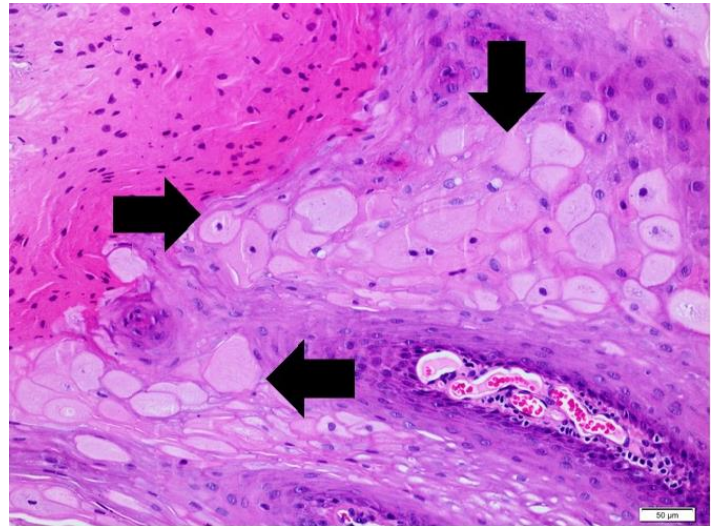


Figure 3: A light microscopic image under higher magnification of the balloon-like cells (arrows) in the squamous epithelium (hematoxylin-eosin staining, original magnification x200).

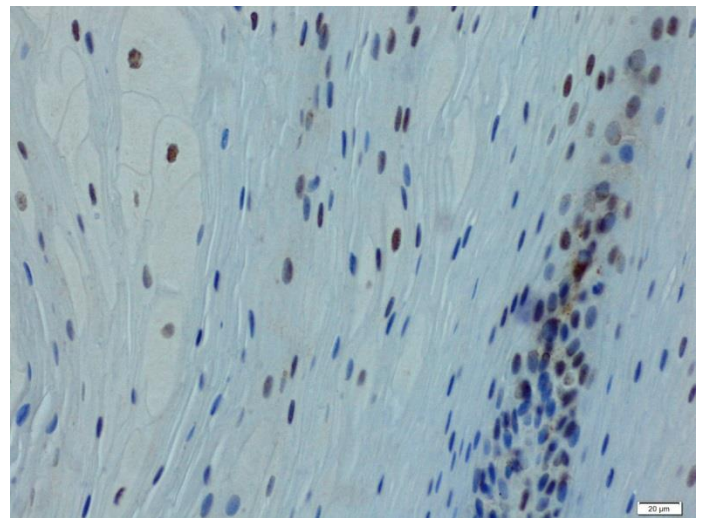


Figure 4: Diffuse nuclear positivity (brown staining) in the squamous epithelium at immunohistochemical examination using EBV antibody (The avidin-biotin-peroxidase method, original magnification x400).

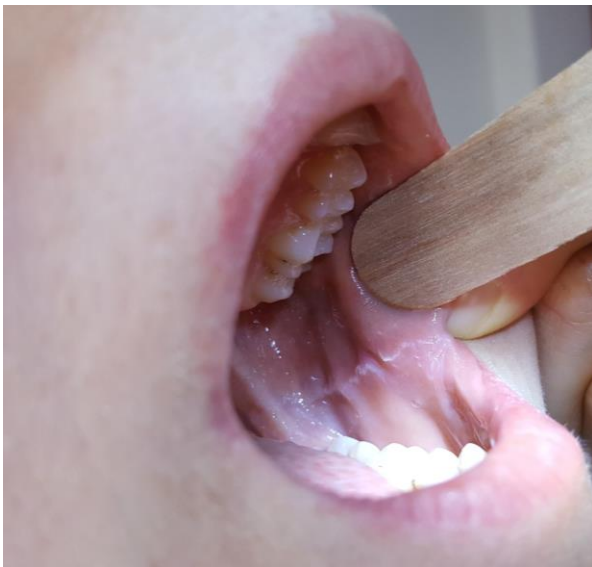

Figure 1: Slightly elevated, linear white plaques on the bilateral buccal mucosa, which could not be removed by scraping.

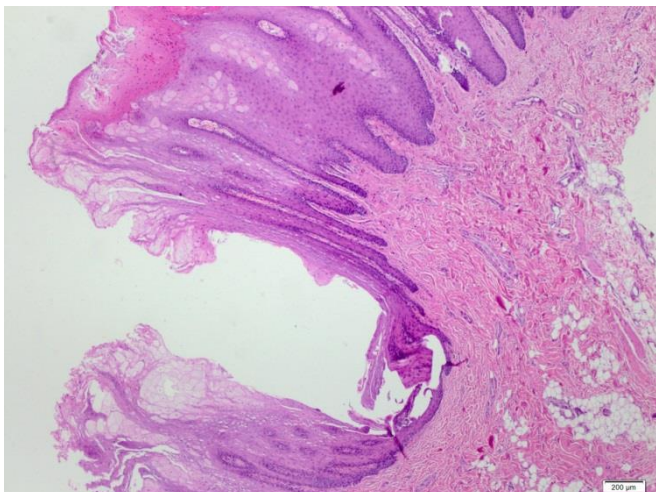


Figure 2: Light microscopic image of the lesion with hyperkeratosis and parakeratosis in the keratin layer, papillomatosis in the squamous epithelium, evident pseudoepitheliomatous hyperplasia and balloon-like cells with large vacuolar cytoplasm (hematoxylin-eosin staining, original magnification x40).

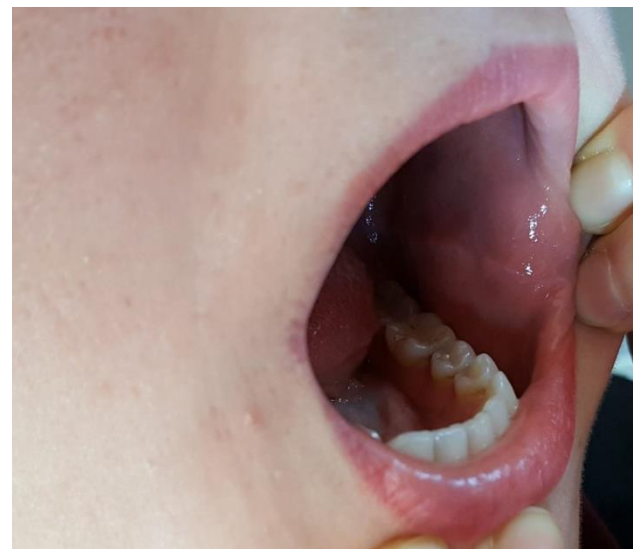

Figure 5: Appearance of the lesions 1 week after oral valaciclovir treatment.

Discussion

Although buccal mucosal involvement has been reported in a few OHL cases, the lesion is generally observed on the lateral edges of the tongue. Although OHL has a characteristic appearance on the tongue, it can be confused with other white lesions when located on the buccal mucosa (such as

candidiasis, idiopathic or smoking-related leukoplakia, frictional keratosis, carcinoma, idiopathic lichen planus and medication related lichenoid reactions). Biopsy may therefore be required to confirm the clinical diagnosis [6]. Histopathological findings in our case were compatible with OHL, and no pathological skin findings were observed except for the oral mucosa.

EBV is a ubiquitous human herpesvirus that affects approximately 90-95% of the adult population worldwide and that primarily infects B-lymphocytes. The virus causes a wide spectrum of mucocutaneous and systemic illnesses, ranging from self-limiting diseases to aggressive malignancies [7]. The virus lives in peripheral blood memory B lymphocytes, which are cellular reservoirs of permanent latent EBV infection. Virus infiltration occurs by secretion of EBV-infected oropharyngeal cells during viral reactivation [2]. EBV can be detected in 10 to 90% of healthy adults using the polymerase chain reaction in the normal lingual epithelium, although it is very rare in healthy non-HIV infected individuals [8]. Other factors may thus be involved in the pathogenesis of OHL, including systemic immunosuppression and persistent EBV replication, as well as suppression of EBV virulence and local host immunity [2].

OHL is usually asymptomatic, but patients may report pain, taste sensation changes, or a burning sensation. Cosmetic concerns can also lead to some psychological distress [7]. White spongiform nevus, lichen planus, idiopathic leukoplakia and oral candidiasis should be considered at differential diagnosis of OHL. Unlike OCL, the oral candidiasis plaque can easily be removed with a tongue depressor, and an erythematous area appears at the base [6,7]. Our patient's lesion could not be removed by scraping.

While OHL is considered a benign condition, definite diagnosis is nevertheless important, since the clinical appearance may mimic a premalign lesion and because the lateral margin of the tongue is a high-risk site for squamous cell carcinoma. This is especially important if there are no underlying predisposing factors in HIV-negative patients or for OHL [4]. OHL treatment should be considered in patients with symptoms or cosmetic concerns. Treatment options include systemic antiviral therapy (acyclovir, valaciclovir), topical podophylline, topical retinoids, gentian violet, surgical excision and cryotherapy [9-13]. Regardless of the type of treatment, OHL often recurs after termination [7]. Our patient was started on 2 x 500 mg valaciclovir. At follow-up after 1 week, the lesions appeared completely regressed. There was no recurrence in the first month of follow-up.

In conclusion, we present this case of a healthy, HIV-negative female patient with no underlying predisposing factors, due to the rarity of the location of the OHL lesion on the buccal mucosa.

References

- Greenspan D, Greenspan JS, Conant M, et al. Oral "hairy" leukoplakia in male homosexuals: evidence of association with both papillomavirus and a herpes-group virus. *Lancet*. 1984;2:831-4.
- Piperi E, Omlie J, Koutlas IG, Pambuccian S. Oral hairy leukoplakia in HIV-negative patients: report of 10 cases. *Int J Surg Pathol*. 2010;18:177-83.
- Bravo IM, Correnti M, Escalona L, et al. Prevalence of oral lesions in HIV patients related to CD4 cell count and viral load in a Venezuelan population. *Med Oral Patol Oral Cir Bucal*. 2006;11:E33-E39.
- Prasad JL, Bilodeau EA. Oral hairy leukoplakia in patients without HIV: presentation of 2 new cases. *Oral Surg Oral Med Oral Pathol Oral Radiol*. 2014;118:e151-60.
- Felix DH, Watret K, Wray D, Southam JC. Hairy leukoplakia in an HIV-negative, nonimmunosuppressed patient. *Oral Surg Oral Med Oral Pathol*. 1992;74:563-6.
- Ficarra G, Romagnoli P, Piluso S, et al. Hairy leukoplakia with involvement of the buccal mucosa. *J Am Acad Dermatol*. 1992;27:855-8.
- Hall LD, Eminger LA, Hesterman KS, Heymann WR. Epstein-Barr virus: dermatologic associations and implications: part I. Mucocutaneous manifestations of Epstein-Barr virus and nonmalignant disorders. *J Am Acad Dermatol*. 2015;72:1-19.
- Scully C, Porter SR, Di Alberti L, et al. Detection of Epstein-Barr virus in oral scrapes in HIV-infection, in hairy leukoplakia, and in healthy non-HIV-infected people. *J Oral Pathol Med*. 1998;27:480-2.
- Walling DM, Flaitz CM, Nichols CM. Epstein-Barr virus replication in oral hairy leukoplakia: response, persistence, and resistance to treatment with valacyclovir. *J Infect Dis*. 2003;188:883-90.
- Moura MD, Guimarães TR, Fonseca LM, et al. A random clinical trial study to assess the efficiency of topical applications of podophyllin resin (25%) versus podophyllin resin (25%) together with acyclovir cream (5%) in the treatment of oral hairy leukoplakia. *Oral Surg Oral Med Oral Pathol Oral Radiol Endod*. 2007;103:64-71.
- Schöfer H, Ochsendorf FR, Helm EB, Milbradt R. Treatment of oral 'hairy' leukoplakia in AIDS patients with vitamin A acid (topically) or acyclovir (systemically). *Dermatologica*. 1987;174:150-1.
- Bhandarkar SS, MacKelfresh J, Fried L, Arbiser JL. Targeted therapy of oral hairy leukoplakia with gentian violet. *J Am Acad Dermatol*. 2008;58:711-2.
- Goh BT, Lau RK. Treatment of AIDS-associated oral hairy leukoplakia with cryotherapy. *Int J STD AIDS*. 1994;5:60-2.