

## EDİTÖRE MEKTUP / LETTER TO THE EDITOR

### A lesion mixed with gallbladder neoplasm: adenomyomatosis

Safra kesesi kanseri ile karışan bir lezyon: adenomyomatosis

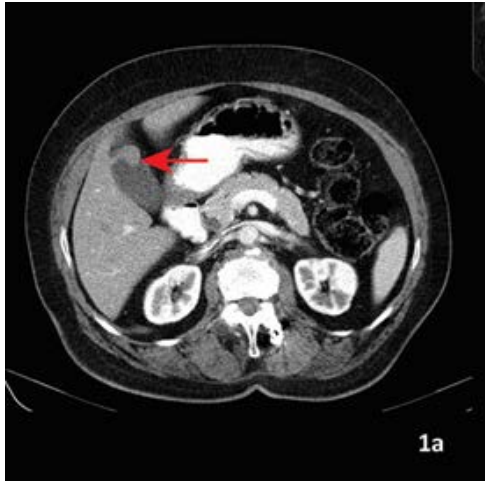
Ali Ezer<sup>1</sup>, Alper Parlakgümüſ<sup>1</sup>

<sup>1</sup>BaskentUniversity School of Medicine, Adana Teaching and Research Center, Dept. of General Surgery, Adana, Turkey

*Cukurova Medical Journal 2018;43(2):528-529*

Dear Editor,

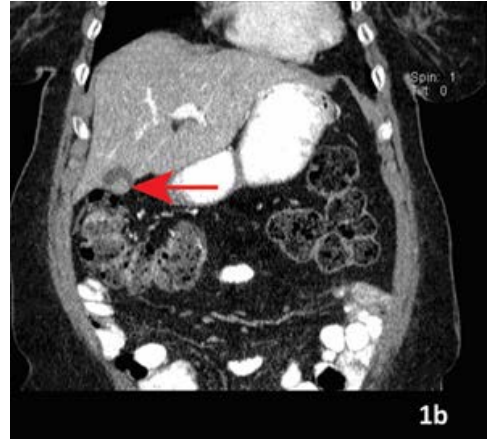Gallbladder adenomyomatosis (GAM) is a benign disorder distinguished by mucosal epithelium proliferation and muscularis mucosae hypertrophy and frequently characterized by the formation of mucosal invagination in the hypertrophied muscularis and intramural diverticula or sinus tracts which is significant in radiological monitoring (Rokitansky-Aschoff sinuses). It is also referred as 'cholecystitis glandular proliferans' in literature<sup>1</sup>.



**Figure 1a** The axial view of an abdominal computed tomography of the patient showing localized type adenomyomatosis of gallbladder settled in fundus (red arrow).

72 years old female patient applied to the hospital with occasionally increasing stomach pain. Her blood test results were as follows; T bil: 0,3 mg/dL,

D. bil: 0,1 mg/dL, ALP: 84 U/L, CEA: 0,75 ng/mL, CA 19-9: 17,15 U/mL, GGT: 9 IU/. Ultrasonography findings revealed that a 18x17 mm hypoechoic lesion existed on the gallbladder wall involving calcification and cystic spaces and was evaluated in support of focal adenomyomatosis. A mass lesion with soft tissue density reaching approximately 16 mm in diameter was found in the gallbladder at the fundus portion on CT results of the patient and this lesion was thought to be in compatible with gallbladder adenomyomatosis (figure 1,2). In the history of the patient, she was diagnosed with sigmoid volvulus and sigmoid colon resection was applied on her.



**Figure 1b.** The coronal view of an abdominal computed tomography of the patient showing localized type adenomyomatosis of gallbladder settled in fundus (red arrow).

The patient was taken into operation and open

cholecystectomy was practiced. Intra-operative frozen section examination was performed. No malignity was identified. Adenomyoma at the fundus portion was reported on pathology examination. The patient was discharged from hospital on the post-operative 2nd day without any problems.

In cases where the possibility of malignity can not be completely distracted, MR imaging aids to get a diagnosis. With selected cases, PET examination helps to distract malignity<sup>2</sup>. With regard to gross characteristics, Jutras et al. categorize the gallbladder adenomyomatosis into three types: segmental, localized or generalized<sup>3</sup>. Segmental type adenomyomatosis is reported to have relation with malignity especially in old patients<sup>3,4</sup>.

The case we present here is an example for a localized type adenomyomatosis. It should always be kept in mind that gallbladder adenomyomatosis

might be confused with malign lesions and this possibility should always come to mind in definitive diagnosis. On old patients suspected with malignity, surgical intervention is the first-choice treatment in gallbladder adenomyomatosis

## REFERENCES

1. Sermon A, Himpens J, Leman G. Symptomatic adenomyomatosis of the gallbladder – report of a case. *Acta Chir Belg.* 2003;103:225-29.
2. Bonatti M, Vezzali N, Lombardo F, Ferro F, Zamboni G, Tauber M et al. Gallbladder adenomyomatosis: imaging findings, tricks and pitfalls. *Insights Imaging.* 2017;8:243-53.
3. Jutras JA, Longtin M, Levesque HP. Hyperplastic cholecystoses. *Am J Roentgenol.* 1960;83:795-827.
4. Owen CC, Bilhartz LE. Gallbladder polyps, cholesterolosis, adenomyomatosis, and acute acalculous cholecystitis. *Semin Gastrointest Dis.* 2003;14:178-88.