

Research Article

OBJECTIVE LENS DENSITOMETRY EVALUATION USING SCHEIMPFLUG TOPOGRAPHY IN CHILDREN AFTER COVID-19 INFECTION

Onur KALAY¹, Ayşe İpek AKYÜZ ÜNSAL^{2*}, Erol ERKAN², Sayime AYDIN EROĞLU³, Sinan BEKMEZ⁴, Esin TUNCA KIRIKKAYA⁵, İmran KURT ÖMÜRLÜ⁶

¹Yalova State Hospital, Department of Ophthalmology, Yalova, TURKIYE

²Aydın Adnan Menderes University, Department of Ophthalmology, Aydın, TURKIYE

³İzmir Çiğli Research and Training Hospital, Department of Ophthalmology, İzmir, TURKIYE

⁴İzmir S.B.U Dr. Behcet Uz Child Diseases and Surgery Research and Training Hospital, Department of Ophthalmology, İzmir, TURKIYE

⁵İzmir Tepecik Research and Training Hospital, Department of Ophthalmology, İzmir, TURKIYE

⁶Aydın Adnan Menderes Üniversitesi, Biyoistatistik Ana Bilim Dalı, Aydın, TURKIYE

*Correspondence: ipekunsal@yahoo.com

ABSTRACT

Objective: To explore the effects of COVID-19 on lens structure in children using Pentacam HR Scheimpflug corneal topography and lens densitometry (LD).

Materials and Methods: This prospective case-control study involved patients aged 7 to 18 who were scheduled for ophthalmologic examination. Pentacam densitometry zones (PDZ 1, 2, and 3) were evaluated in children who had recovered from COVID-19 within the past 6 months and had no systemic diseases, with comparisons made to control subjects.

Results: A total of 114 eyes from 57 patients were evaluated, including 29 (50.9%) children in the patient group and 28 (49.1%) in the control group. PDZ 1 values for ages 7-10, all PDZ values for ages 11-14, and PDZ 3 values for ages 15-18 were significantly higher after COVID-19 compared to those in the control group ($P < 0.05$). Positive correlations were found between PDZ 1-3 values and the time since recovery from COVID-19 in patients aged 11-14 ($r = 0.639, 0.628, \text{ and } 0.590$, respectively; $P = 0.014, 0.016, \text{ and } 0.027$).

Conclusion: Vision quality is influenced not only by visual acuity but also by factors such as contrast sensitivity, higher-order optical irregularities, and the clarity of the visual axis. Our study reveals significant differences in lens density, particularly among children aged 11 to 14, highlighting the potential impact of COVID-19 on their visual quality and underscoring the need for more comprehensive studies on this topic.

Keywords: Children; COVID-19; Lens Densitometry; Pediatric; Scheimpflug Topography

Received: 10 March 2025

Revised: 25 March 2025

Accepted: 22 May 2025

Published: 23 June 2025



Copyright: © 2025 by the authors. Published by Aydın Adnan Menderes University, Faculty of Medicine and Faculty of Dentistry. This article is openly accessible under the Creative Commons Attribution-NonCommercial 4.0 International (CC BY-NC 4.0) License.

INTRODUCTION

COVID-19, a severe acute respiratory infection caused by the SARS-CoV-2 virus, was first declared a pandemic in China by the World Health Organization in late 2019 (1). Although COVID-19 is mainly associated with respiratory symptoms, its effects on the eyes and potential ocular complications merit investigation due to the established possibility of ocular transmission and involvement (2,3). Reported ocular symptoms of COVID-19 include dry eye, a foreign body sensation, itching, blurred vision, conjunctivitis, chemosis, and photophobia (4). Several studies have demonstrated the presence of the virus on the ocular surface, in tears, and in conjunctival swab samples (5).

In cases of COVID-19, virus-induced inflammation and subsequent cytokine storms can disrupt the dynamics of the eye, impacting the anterior segment, including anterior uveitis and changes to the overall lens structure (6,7). Aydemir et al. compared the lens structures of adult COVID-19 patients using the Pentacam HR Scheimpflug topography camera (Oculus Inc., Arlington, WA, USA), which captures detailed images of the entire anterior segment, from the anterior corneal surface to the posterior lens surface (7).

In light of the current literature search, we did not come across a study evaluating the effect of COVID-19 on lens density among pediatric patient groups. Thus, we have designed a prospective observational case-control study to compare objective lens densitometry (LD) measurements with a Scheimpflug topography device among children aged 7-18 who have recovered from COVID-19 with those of healthy children who have no documented history of SARS-CoV-2 infection.

MATERIALS AND METHODS

This prospective cross-sectional comparative study was conducted at the Ophthalmology Department, following the provision of specific information regarding parental consent and child assent, and approval from the local ethics committee (No:2022/31, Date:10.02.2022), in accordance with the tenets of the Declaration of Helsinki.

The patient group of this study included children aged 7-18 years at the time of inclusion who applied to our outpatient clinic for eye examinations between February 2022 and December 2022 and had a history of COVID-19 disease confirmed by at least one positive PCR test with more than 6 months having passed since their recovery.

All included patients had no additional chronic diseases and voluntarily participated in the research. The control group consisted of children of the same age range who applied to our outpatient clinic for eye examinations and had no confirmed history of COVID-19 (i.e., no positive COVID-19 PCR tests), reported no COVID-19 symptoms, had no chronic diseases, and volunteered to participate in the research. The exclusion criteria for both groups were age greater than 18 years, diabetes mellitus, glaucoma, diseases of the corneal surface, corneal edema, cataracts, and previous intraocular surgery.

Thorough ophthalmological examinations included best-corrected visual acuity with a Snellen chart, intraocular pressure with a non-contact tonometer device, and anterior segment examination with slit-lamp biomicroscopy. 2.5% phenylephrine, 1% cyclopentolate, and 0.5% tropicamide drops were instilled into both eyes at 5-minute intervals for fundus examination. This comprehensive approach ensured that all potential factors influencing lens clarity were taken into account, thereby enhancing the accuracy of our data.

After the dilated fundus exam, LD measurements were performed for all patients by the same practitioner (O.K.) under standard dim lighting conditions using the Scheimpflug topography imaging system (Pentacam HR, Oculus Inc., Wetzlar, Germany). The Pentacam HR was chosen for this study due to its ability to provide objective, noninvasive, and reproducible measurements of lens density using Scheimpflug imaging. This imaging technique has been previously validated for assessing subtle changes in lens opacity and has been widely utilized in corneal and lens densitometry research (7). Images that were difficult to evaluate due to poor quality or high levels of reflection were excluded from the study. Mean LD values were calculated at 2 mm in diameter for Zone 1, 4 mm for Zone 2, and 6 mm for Zone 3, using the middle of the pupil as the reference point. These values were recorded as Pentacam densitometry zones PDZ 1, PDZ 2, and PDZ 3, respectively (Figure 1). The average, standard deviation and maximum values of LD measurements were calculated.

The study included both eyes to enhance the robustness of the dataset and increase statistical power. Since systemic diseases commonly affect both eyes symmetrically, incorporating bilateral measurements allowed for a more comprehensive evaluation of potential alterations in lens density.

Statistical analysis

R software, version 4.1.0 (R Foundation for Statistical Computing, Vienna, Austria) was used for statistical analyses. To facilitate the statistical analysis of the obtained data and enable reliable comparisons, one-to-one matching was performed between the patient and control groups based on age and gender. Descriptive statistics are given as number (n), percentage (%), mean \pm standard deviation (SD), median (M), first quartile (Q1), and third quartile (Q3). The normality of numerical variables was evaluated using the Shapiro-Wilk normality test. Comparisons of numerical variables between the patient and control groups were performed using the independent two-sample t-test and the Mann-Whitney U test. Relationships between age and numerical variables were evaluated with Spearman correlation analysis. Values of $p < 0.05$ were accepted as statistically significant.

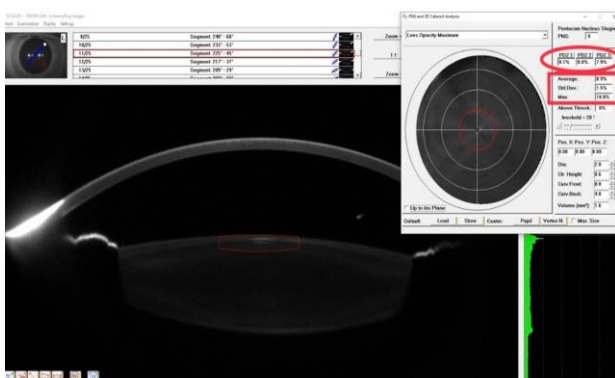


Figure 1. Screenshot of the Lens Densitometry Analysis using the Pentacam HR Scheimpflug Topography System.

RESULTS

Descriptive characteristics of the participants

Within the scope of this study, 114 eyes from a total of 57 children aged 7 to 18 were evaluated. The gender balance was carefully maintained, with 29 participants (17 boys and 12 girls) in the patient group and 28 participants (15 boys and 13 girls) in the control group. The study included 32 (56.1%) male participants and 25 (43.9%) female participants. This balanced representation ensures that our findings apply to a diverse pediatric population. The mean age was 12.92 ± 3.27 years in the patient group and 12.79 ± 3.43 years in the control group ($P = 0.880$). In the patient group, a mean of 15.95 ± 4.97 months had passed since COVID-19 infection.

There were no significant differences in PDZ values, average LD values, or maximum LD values measured for

the 58 eyes of the patient group and the 56 eyes of the control group ($p > 0.05$). The LD values obtained with the Pentacam HR imaging system are presented in Table 1 for comparison.

Table 1. Comparison of lens densitometry measurements by groups.

	Patient Group N = 58	Control Group N = 56	
Variables	M [Q1-Q3]		p*
PDZ 1 (%)	7.90 [7.80-8.10]	7.90 [7.80-8.17]	0.447
PDZ 2 (%)	7.90 [7.77-8.10]	7.90 [7.80-8.30]	0.396
PDZ 3 (%)	7.90 [7.80-8.10]	7.90 [7.80-8.20]	0.614
AVERAGE LD	8.70 [8.20-8.90]	8.60 [8.30-8.87]	0.472
STD DEV LD	1.50 [1.17-1.70]	1.40 [1.10-1.77]	0.776
DENS MAX	18.00 [16.00-	17.80 [15.80-	0.792
LD	22.10]	23.0]	

N: Number of eyes, PDZ: Pentacam densitometry zone, LD: Lens densitometry, STD DEV: Standard deviation, DENS MAX: Maximum densitometry, M: Median, Q1: First quartile, Q3: Third quartile. * Group comparisons were made using the Mann-Whitney U test.

No significant differences were observed in the PDZ values, average LD values, or maximum LD values measured for the 24 eyes of the girls in the patient group and the 26 eyes of the girls in the control group ($P > 0.05$). Similarly, no significant differences were observed in the PDZ values, average LD values, or maximum LD values measured for the eyes of the boys in the patient and control groups ($P > 0.05$).

Table 2. Comparison of lens densitometry measurements by groups for children aged 7-10.

	PATIENT GROUP N = 20	CONTROL GROUP N = 18	
Variables	M [Q1-Q3]		p*
PDZ 1 (%)	7.90 [7.80-8.10]	8.10 [7.87-8.42]	0.028
PDZ 2 (%)	7.90 [7.72-8.07]	8.20 [7.87-8.32]	0.063
PDZ 3 (%)	8.00 [7.72-8.10]	8.15 [7.95-8.22]	0.105
AVERAGE LD	8.55 [8.10-8.80]	8.60 [8.40-9.00]	0.141
STD DEV LD	1.55 [1.40-1.80]	1.80 [1.32-2.05]	0.217
DENS MAX	16.90 [15.40-	19.60 [17.52-	0.228
LD	21.90]	25.00]	

N: Number of eyes, PDZ: Pentacam densitometry zone, LD: Lens densitometry, STD DEV: Standard deviation, DENS MAX: Maximum densitometry, M: Median, Q1: First quartile, Q3: Third quartile. * Group comparisons were made using the Mann-Whitney U test.

For participants aged 7-10 years, the median PDZ 1 value in the patient group was 7.90, based on 20 eyes, while for the 18 eyes in the same age range as the control group, it was 8.10 ($p = 0.028$). However, the PDZ 2, PDZ 3, average LD, and maximum LD values did not differ significantly among participants aged 7-10 years ($p > 0.05$). The LD values of children from this age group are presented comparatively in Table 2.

For participants aged 11-14 years, the mean values of PDZ 1, PDZ 2, and PDZ 3 are presented in Table 3. A statistically significant difference was found between the groups for all these parameters. LD values also differed significantly between the groups among children aged 11-14 ($p < 0.05$).

Table 3. Comparison of lens densitometry measurements by groups for children aged 11-14.

	Patient Group N = 14	Control Group N = 18	
Variables	M [Q1-Q3]		p*
PDZ 1 (%)	8.05 [7.87-8.35]	7.80 [7.72-7.90]	0.010
PDZ 2 (%)	8.05 [7.87-8.12]	7.80 [7.72-7.90]	0.009
PDZ 3 (%)	8.10 [8.00-8.12]	7.80 [7.72-7.90]	0.001
AVERAGE LD	8.85 [8.50-9.22]	8.20 [8.00-8.60]	0.002
STD DEV LD	1.65 [1.47-1.85]	1.20 [1.02-2.47]	0.001
DENSMAX	21.20 [18.60-24.30]	16.10 [14.50-18.80]	<0.001

N: Number of eyes, PDZ: Pentacam densitometry zone, LD: Lens densitometry, STD DEV: Standard deviation, DENSMAX: Maximum densitometry, M: Median, Q1: First quartile, Q3: Third quartile. * Group comparisons were made using the Mann-Whitney U test.

Among children aged 15-18 years, only the median PDZ 3 value differed significantly between the groups ($p = 0.034$). There were no significant differences in the other LD values between the groups for this age range (Table 4).

Table 4. Comparison of lens densitometry measurements by groups for children aged 15-18.

	Patient Group N = 24	Control Group N = 22	
Variables	M [Q1-Q3]		p*
PDZ 1 (%)	7.90 [7.72-8.07]	7.90 [7.80-8.22]	0.147
PDZ 2 (%)	7.85 [7.70-8.00]	7.90 [7.80-8.30]	0.078
PDZ 3 (%)	7.90 [7.80-7.90]	7.95 [7.90-8.22]	0.034
AVERAGE LD	8.70 [8.12-8.87]	8.60 [8.30-8.95]	0.991
STD DEV LD	1.15 [0.90-1.47]	1.30 [1.10-1.50]	0.107
DENS MAX	16.50 [14.10-21.40]	17.65 [16.50-23.40]	0.172

N: Number of eyes, PDZ: Pentacam densitometry zone, LD: Lens densitometry, STD DEV: Standard deviation, DENSMAX: Maximum densitometry, M: Median, Q1: First quartile, Q3: Third quartile. * Group comparisons were made using the Mann-Whitney U test.

Correlation analysis results

Table 5 shows correlation analysis results for age and LD measurements. For the patient group, a significant weak negative correlation was detected between LD SD values and age ($r = -0.381$, $p = 0.003$). When the patient and control groups were examined, a significant weak negative relationship was again determined between LD SD and age ($r = -0.325$, $p < 0.001$).

The results of the correlation analysis were performed between LD findings and the number of months since COVID-19 diagnosis, according to the age of the patients. A significant moderate positive correlation was observed between the maximum LD values of children aged 7-10 in

the patient group and the time elapsed since COVID-19 infection ($r = 0.585$, $p = 0.006$). Similarly, a moderate positive correlation existed between LD SD and time since COVID-19 ($r = 0.521$, $p = 0.019$). Significant high-level positive correlations were detected between the PDZ 1, PDZ 2, and PDZ 3 values of patients aged 11-14 and time since COVID-19 ($r = 0.639$, 0.628 , and 0.590 and $p = 0.014$, 0.016 , and 0.027 , respectively).

Table 5. Correlation analysis of age and lens densitometry measurements.

Groups		PDZ 1	PDZ 2	PDZ 3	DENSMAX LD	AVERAGE LD	STD DEV LD
Patient Group (N = 58)	r	0.010	-0.035	-	-0.052	0.151	-0.381
	p*	0.938	0.793	0.546	0.700	0.257	0.003
Control Group (N = 56)	r	-0.190	-0.192	-	-0.033	-0.009	-0.206
	p*	0.160	0.157	0.555	0.808	0.949	0.128
Total (N = 114)	r	-0.082	-0.118	-	-0.044	0.085	-0.325
	p*	0.383	0.211	0.086	0.642	0.370	<0.001

N: Number of eyes, PDZ: Pentacam densitometry zone, DENSMAX: maximum densitometry, LD: Lens densitometry, STD DEV: Standard deviation. *Spearman's correlation test was applied

DISCUSSION

The COVID-19 pandemic has impacted the world in every aspect of life, and SARS-CoV-2 affects various parts of the body. However, data on the impact of COVID-19 on the structures of the anterior segment of the eye are still insufficient (8). Recently published studies have shown the presence of ACE2 receptors in the conjunctival, limbal, and corneal structures (9,10), and together with those findings, reported changes in both corneal and LD values in adult COVID-19 patients prompted us to investigate the effects of the virus on the cornea and other structures of the anterior segment in pediatric patients, who have a long life expectancy ahead of them. With this aim, we compared objective LD measurements in children between the ages of 7 and 18 years who had been serologically proven to have had COVID-19 with the LD values of age-matched children with no history of COVID-19 infection, using the Pentacam HR Scheimpflug topography system.

Children are estimated to account for only 1% of COVID-19 cases and have a significantly lower risk of severe illness or death (11). There are limited publications on the ocular findings of COVID-19 in the pediatric population. The most common ocular finding reported in non-ophthalmological studies is the congestion of conjunctival vessels (12).

Although the primary route for the transmission and spread of the SARS-CoV-2 virus is the upper respiratory tract, conjunctivitis in COVID-19 patients suggests that the ocular surface may serve as a reservoir for COVID-19 or a route for its transmission (13). After discovering that ACE2 is the primary binding receptor of the virus, the presence of this receptor in ocular structures was investigated (14). In recent studies, the ACE2 receptor, which is known to facilitate viral entry into cells after the virus binds to the receptor, and the transmembrane protease serine 2 (TMPRSS2) enzyme, which provides a path of entry for the virus, have been detected in the cornea, conjunctiva, and limbal regions (9,15,16). The eyes of human cadavers were examined to clarify the expression patterns of ACE2 and TMPRSS2, and it was determined that ACE2 expression was mainly present in the corneal epithelium, the conjunctival surface, and the limbus (17). Furthermore, ACE2 and TMPRSS2 expressions were detected in human corneal epithelial samples taken during refractive surgery (17,18). It has been reported that ACE2 and TMPRSS2 are co-expressed in the retinal pigment epithelium and cornea. The cornea is likely to be a non-respiratory entry point for SARS-CoV-2. In a study comparing the corneal densitometry parameters of patients with COVID-19 and a control group, Aydemir et al. identified effects of COVID-19 on the cornea, and especially the top layer and central zones (7). Corneal involvement in SARS-CoV-2 has been established in studies like those presented here, but knowledge about lens involvement in COVID-19 remains limited. While the development of episcleritis and uveitis due to virus-induced inflammation and subsequent cytokine storms has been demonstrated, it seems possible that the structures and transparency of the cornea or lens are also affected (19). The presence of the virus is also possible in various parts of the eye, such as the lens, as ACE2 receptors have been demonstrated in the aqueous humor (20). Although direct viral involvement of the structures of the lens could not be demonstrated in our study, the LD values of children who had recovered from COVID-19 infection at least 6 months previously were objectively evaluated by Scheimpflug topography and compared with the values of a control group, and the short-term effects of the disease were investigated.

To date, only one study in the literature has evaluated LD parameters in adult patients with a history of COVID-19. In that study, the mean, standard deviation (SD), and maximum LD values for zones 2 and 3 were significantly higher in patients compared to the control group (7). In the present study, following the COVID-19 pandemic, we observed that PDZ 1 values in children aged 7-10, all PDZ values in children aged 11-14, and PDZ 3 values in

children aged 15-18 were significantly higher compared to the control group. These findings suggest that COVID-19 affects lens clarity not only in adults but also in children. Although the presence of ACE2 receptors in the lens has not been demonstrated, infiltration of the aqueous humor by SARS-CoV-2 or disruption of the metabolic balance during the inflammatory process may negatively affect the nourishment of the lens (10).

The significant difference in LD values in the 11-14 age group may be attributed to heightened metabolic activity in the crystalline lens during this critical developmental phase, rendering it more vulnerable to external stressors such as systemic inflammation and oxidative damage. As the primary nutrient source for the avascular lens, the aqueous humor may mediate these effects, with potential alterations resulting from the presence of SARS-CoV-2 that could affect lens metabolism. Anatomical and physiological differences between pediatric and adult lenses further suggest that children in this age range may be more susceptible to metabolic imbalances triggered by systemic infections. Additionally, pubertal hormonal changes may play a role in modulating lens transparency and metabolism, potentially interacting with COVID-19-induced inflammatory processes (10).

In recent studies, the authors state that the intraocular effects of COVID-19 may depend on direct virus attachment to the ACE2 and TMPRSS2 receptors on the ocular surfaces, as well as indirectly through the inflammatory process it causes, such as anterior uveitis and multisystem inflammatory syndrome (21-25). Ishigooka et al. demonstrated that increased levels of ACE in the lens lead to cataract formation in an experimental rat model of diabetes. They showed that ACE blockade with candesartan prevents cataract development (26). Given these findings, we believe COVID-19 could raise ACE levels in the lens, resulting in increased oxidative damage, protein aggregation, and lens opacity.

The only previous study on this subject was conducted with adults, so the different results obtained in the present study may be due to differences in developmental processes between adult patients and children (7). Just as ACE levels may vary across different childhood stages, the sensitivity of lens clarity may also fluctuate after a COVID-19 infection. This could explain the varying LD levels in our study groups.

Our study has several limitations. First, the groups consisted of relatively small numbers of children. This was because relatively few pediatric patients experience COVID-19 infections, some are asymptomatic, and not all

patients have serological confirmation. In selecting the control group, any history of COVID-19-related symptoms in the participants or their household members was established as an exclusion criterion. Accordingly, only individuals with no history of symptoms suggestive of COVID-19 were included in the study. However, since this study involved a pediatric population, obtaining serological or PCR tests from children was not feasible due to ethical and practical constraints. Given that COVID-19-related ocular changes have been reported to be more pronounced in symptomatic cases, the likelihood of significant confounding effects from undiagnosed asymptomatic infections in the control group remains limited. Second, although our research employed a prospective design, LD measurements had not been performed for the patient group before the onset of COVID-19 infection; therefore, a causal relationship between COVID-19 and changes in the lens could not be fully established. Research conducted with larger cohorts of pediatric COVID-19 patients from multiple centers is needed to confirm our findings. Furthermore, this study investigated ocular changes in the early post-recovery period. As a result, it is currently not possible to determine whether the differences in LD values of the patients will persist over time or be reversed. On the other hand, this study also has its strengths. To our knowledge, this is the first case-control study in the literature involving LD measurements in children with a history of COVID-19. In addition, since no relevant treatments were given to the children during their COVID-19 infections, possible drug side effects on the lens were excluded.

CONCLUSION

Our study has revealed significant changes in the LD values of children who applied to our clinic for various reasons and did not have diabetes, glaucoma, corneal diseases, cataracts, or a history of trauma or intraocular surgery, but did have a history of COVID-19, compared to children who did not have a history of COVID-19. Although the pandemic appears to be waning, the effects of COVID-19 continue to affect many people. The measurement of LD values using the Pentacam HR device, a reliable, easy-to-use, and non-invasive method, enables the objective evaluation and clinical monitoring of lens health in children who have had COVID-19. In this study, although no differences were observed in the LD values between the groups, a significant difference was found for patients aged 11-14. It should be remembered that lens transparency may deteriorate at any stage among these patients, even if there is no immediate visible loss in lens clarity. Visual quality depends not only on visual acuity

but also on contrast sensitivity, high-order aberrations, and visual axis clarity. Our results, particularly those obtained for the 11-14 age group, may reflect long-term impacts on visual quality in children after COVID-19. Long-term studies are needed with larger patient groups, and ophthalmologists should consider the potential effects of COVID-19 when performing eye examinations on pediatric patients.

Acknowledgments

None

Authorship contributions

Concept and design: A.İ.A.Ü., O.K., İ.K.Ö.; Data Collection and Processing: A.İ.A.Ü., O.K.; Analysis or Interpretation: A.İ.A.Ü., O.K., S.A.E., E.E., S.B., E.K., İ.K.Ö. ; Literature Search: and Writing: A.İ.A.Ü., O.K., S.A.E., E.E., S.B., E.K., İ.K.Ö.

Data availability statement

The data that support the findings of this study are available from the corresponding author upon reasonable request.

Declaration of competing interest

None.

Ethics

Aydin Adnan Menderes University Ethics Committee and Review Board (code and decision number: 2022/31; 22.12.2022-287204-13).

Funding

None.

REFERENCES

1. Veritti D, Sarao V, Bandello F, Lanzetta P. Infection control measures in ophthalmology during the COVID-19 outbreak: a narrative review from an early experience in Italy. *Eur J Ophthalmol* 2020;30:621-628.
2. Seah I, Agrawal R. Can the coronavirus disease 2019 (COVID-19) affect the eyes? A review of coronaviruses and ocular implications in humans and animals. *Ocul Immunol Inflamm* 2020;28:391-395.
3. Ho D, Low R, Tong L, Gupta V, Veeraghavan A, Agrawal R. COVID-19 and the ocular surface: a review of transmission and manifestations. *Ocul Immunol Inflamm* 2020;28:726-734.
4. Mahayana IT, Angsana NC, Alya Kamila A, Fatiha NN, Sunjaya DZ, Andajana W et al. Literature review of conjunctivitis, conjunctival swab and chloroquine effect in the eyes: a current

updates on COVID-19 and ophthalmology. *Berkala Ilmu Kedokteran* 2020;52:21-28.

5. Nasiri N, Sharifi H, Bazrafshan A, Noori A, Karamouzian M, Sharifi A. Ocular manifestations of COVID-19: a systematic review and meta-analysis. *J Ophthalmic Vis Res* 2021;16:103-112.

6. Sanjay S, Mutalik D, Gowda S, Mahendradas P, Kawali A, Shetty R. Post coronavirus disease (COVID-19) reactivation of a quiescent unilateral anterior uveitis. *SN Compr Clin Med* 2021;3:1843-1847.

7. Aydemir E, Aksoy Aydemir G, Atesoglu H, Goker YS, Kiziltoprak H, Ozcelik KC. Objective assessment of corneal and lens clarity in patients with COVID-19. *Optom Vis Sci* 2021;98:1348-1354.

8. Hu K, Patel J, Swiston C, Patel BC. Ophthalmic Manifestations of Coronavirus (COVID-19). StatPearls Publishing LLC; 2022. Accessed February 16, 2024. <https://www.ncbi.nlm.nih.gov/books/NBK556093/>.

9. Collin J, Queen R, Zerti D, Dorgau B, Georgiou M, Djidrovski I et al. Co-expression of SARS-CoV-2 entry genes in the superficial adult human conjunctival, limbal and corneal epithelium suggests an additional route of entry via the ocular surface. *Ocul Surf* 2021;19:190-200.

10. Ma D, Chen CB, Jhanji V, Xu C, Yuan XL, Liang JJ et al. Expression of SARS-CoV-2 receptor ACE2 and TMPRSS2 in human primary conjunctival and pterygium cell lines and in mouse cornea. *Eye (Lond)* 2020;34:1212-1219.

11. She J, Liu L, Liu W. COVID-19 epidemic: Disease characteristics in children. *J Med Virol* 2020;92:747-754.

12. Li LQ, Huang T, Wang YQ, Wang ZP, Liang Y, Huang TB et al. COVID-19 patients' clinical characteristics, discharge rate, and fatality rate of meta-analysis. *J Med Virol* 2020;92:577-583.

13. Wu P, Duan F, Luo C, Liu Q, Qu X, Liang L et al. Characteristics of ocular findings of patients with coronavirus disease 2019 (COVID-19) in Hubei Province, China. *JAMA Ophthalmol* 2020;138:575-578.

14. Wan Y, Shang J, Graham R, Baric RS, Li F. Receptor recognition by the novel coronavirus from Wuhan: an analysis based on decade-long structural studies of SARS coronavirus. *J Virol* 2020;94:e00127-20.

15. Ma N, Li P, Wang X, Yu Y, Tan X, Chen P et al. Ocular manifestations and clinical characteristics of children with laboratory-confirmed COVID-19 in Wuhan, China. *JAMA Ophthalmol* 2020;138:1079-1086.

16. Zhou L, Xu Z, Castiglione GM, Soiberman US, Eberhart CG, Duh EJ. ACE2 and TMPRSS2 are expressed on the human ocular surface, suggesting susceptibility to SARS-CoV-2 infection. *Ocul Surf* 2020;18:537-544.

17. Yuan J, Fan D, Xue Z, Qu J, Su J. Co-expression of mitochondrial genes and ACE2 in cornea involved in COVID-19. *Invest Ophthalmol Vis Sci* 2020;61:13.

18. Cheema M, Aghazadeh H, Nazarali S, Ting A, Hodges J, McFarlane A et al. Solarte C. Keratoconjunctivitis as the initial

medical presentation of the novel coronavirus disease 2019 (COVID-19). *Can J Ophthalmol* 2020;55:e125-e129.

19. Roshanshad A, Ashraf MA, Roshanshad R, Kharmandar A, Zomorodian SA, Ashraf H. Ocular manifestations of patients with coronavirus disease 2019: a comprehensive review. *J Ophthalmic Vis Res* 2021;16:234-247.

20. Holappa M, Valjakka J, Vaajanen A. Angiotensin(1-7) and ACE2, "the hot spots" of renin-angiotensin system, detected in the human aqueous humor. *Open Ophthalmol J* 2015;9:28-32.

21. Oren B, Kocabas, DO. Assessment of corneal endothelial cell morphology and anterior segment parameters in COVID-19. *Therapeutic advances in ophthalmology*. 2022; 14, 25158414221096057.

22. Soysal GG, Seyyar SA, Kimyon S, Mete A, Güngör K. Examination of the Corneal Endothelium in Pediatric Patients With COVID-19. *Eye & Contact Lens*. 2023; 49(11), 508-510.

23. SeyedAlinaghi S, Mehraeen E, Afzalian A, Dashti M, Ghasemzadeh A, Pashaei A, et al Dadras O. (2024). Ocular manifestations of COVID-19: A systematic review of current evidence. *Preventive Medicine Reports*. 2024;38, 102608.

24. Kaya-Guner E, Sahin A, Ekemen-Keles Y, Karadag-Oncel E, Kara-Aksay A, Yilmaz D. A prospective long-term evaluation of the ocular findings of children followed with the diagnosis of multisystem inflammatory syndrome (long-term evaluation of ocular findings following MIS-C). *Eye*, 2023; 37(16), 3442-3445.

25. Alnahdi, M. A., & Alkharashi, M. (2023). Ocular manifestations of COVID-19 in the pediatric age group. *European Journal of Ophthalmology*, 33(1), 21-28.

26. Ishigooka, G., Mizuno, H., Oosuka, S., Jin, D., Takai, S., & Kida, T. (2023). Effects of angiotensin receptor blockers on streptozotocin-induced diabetic cataracts. *Journal of Clinical Medicine*, 12(20), 6627.