



Peroneus Quartus with Variant Insertions: A Case Report

Varyant İnsersiyonlu Peroneus Quartus: Bir Olgu Sunumu

Sushma RK¹, Rohini Alva¹, Antony Sylvan D' Souza¹, Kumar MR Bhat¹

¹Manipal University Kasturba Medical College, Department of Anatomy, Manipal-Karnataka, INDIA

CukurovaMedicalJournal 2014;39(4):889-893.

ABSTRACT

Variations in the musculature of the lateral compartment of the leg are not uncommon but are of importance to clinicians and radiologists in diagnosis or imaging interpretations. During routine dissection classes for undergraduate students this rare variation was encountered. A small additional muscle belly (peroneus quartus) was found arising along with peroneus brevis from the upper lateral surface of the fibula with little contribution from the peroneus longus. The rounded tendon after passing through the superior peroneal retinaculum was mainly inserted on to the lateral side of the base of the fifth metatarsal along with the peroneus brevis. Further, it also provided small fibrous extensions to the shaft of the fifth metatarsal bone and a large extension to the base of the 4th metatarsal bone. Awareness of such variations in the insertion pattern of this muscle is of importance to the surgeons undertaking reconstructive procedures.

Key Words: Peroneus quarters, peroneus longus, peroneus brevis, metatarsals.

ÖZET

Bacağın lateral bölgesinin kassis temindeki varyasyonlar nadir değildir, ancak tanı ve görüntülemelerin yorumlanması klinisyenler ve radyologlar için büyük önem taşımaktadır. Lisans öğrencileri için rutin diseksiyon esnasında bu nadir varyasyonlarla karşılaşıldı. Bel bölgesindeki küçük kas grubunu (peroneus quartus); peroneus longusun küçük katkılarıyla fibulanın üst lateral yüzeyinden gelen peroneus brevis ile birlikte olduğu bulunmuştur. Süperior peroneal retinakulumu geçtikten sonra esas olarak yuvarlak tendon, peroneus brevis ile birlikte beşinci metatarsal kemiğinin tabanından lateral bölgeye yerleşmiştir. Aynı zamanda bundan başka 5. metatarsal kemiğinin gövdesine küçük fibröz bir uzantı ve dördüncü metatarsal kemiğinin tabanına geniş bir uzantı gösterilmiştir. Bu kasın insersiyon paternindeki varyasyonlar hakkındaki farkındalık; rekonstrüktif prosedürleri üstlenen cerrahlar için büyük önem taşımaktadır.

Anahtar Kelimeler: Peroneus quarter, peroneus longus, peroneus brevis, metatarsallar

INTRODUCTION

The peroneus quartus (PQ) muscle is one of a group of accessory peroneal muscles present in man. It is reported to be unique to humans, and is believed to represent an evolutionary step in the development of upright posture. The peroneus quartus apart from providing eversion to foot also prevents undue inversion and protects the lateral ligament from being put to stretch by this movement.

This muscle is not only of interest from an anatomical point of view, but also because several case reports have described associated symptomatology including pain in the ankle, with or without previous trauma, splits or tears in peroneus brevis, subluxation or dislocation of the peroneal tendon, tendinous calcification and painful hypertrophy of the retrotrochlear eminence¹⁻³.

The present case is of a small muscle belly arising from both peroneus longus and brevis and

presenting an unusual insertion pattern unlike previous findings.

CASE REPORT

During routine dissection classes for undergraduate, the following rare variation was encountered in the right inferior extremity of a 58-year-old male cadaver.

The peroneus longus (PL) and brevis (PB) had a normal origin. In addition to this, a small muscle belly was found arising along with peroneus brevis with little contribution from the peroneus longus near its origin i.e., from the upper lateral surface of the fibula, to form a separate muscle superficial to both PB and PL. This may be called as peroneus quarters (PQ). This muscular belly then turned into a rounded tendinous band running superficial to PB and anterior to the PL tendon. Further, all three tendons passed through the superior peroneal retinaculum to reach the

dorso-lateral part of the foot (Figure 1). Here, we found that, the inferior peroneal retinaculum was very thin and broad and blending with the deep fascia of the dorsum of the foot.

PL and PB had their normal course and insertion pattern. The tendon of the PQ, when traced further, the rounded tendon now became flattened and inserted (a) mainly into the lateral side of the base of the fifth metatarsal along with the peroneus brevis. Further, a small fibrous extension (b) was found attached to the lateral surface of the base of fifth metatarsal bone distal to the insertion of the PB. Additionally, a long tendinous extension (c) was attached to the dorso-lateral part of the shaft of the fourth metatarsal bone (Figure 2). This additional PQ had its nerve supply from the superficial peroneal nerve near its origin. However, no such abnormalities were found in the left inferior extremity of the same cadaver.

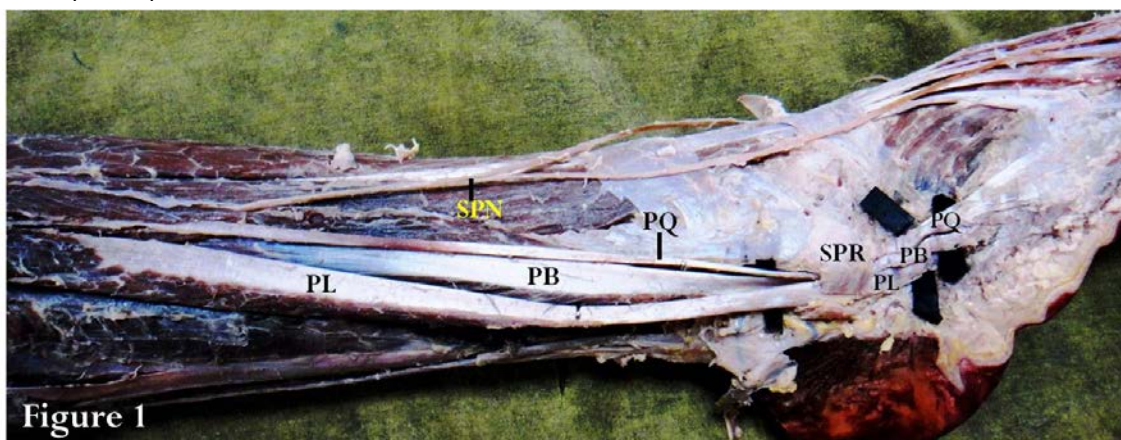


Figure 1. Lateral compartment of the leg showing the peroneus longus (PL) and peroneus brevis (PB) with normal origin and course. An additional tendon (PQ) was found arising from the PB and PL and its rounded tendon was running anterolateral to the tendon of PB towards the retromalleolar groove under the superior peroneal retinaculum (SPR). Within the SPR, the PQ was superficial to the tendon of PB and anterior to the tendon of PL. SPN= Superficial Peroneal Nerve.

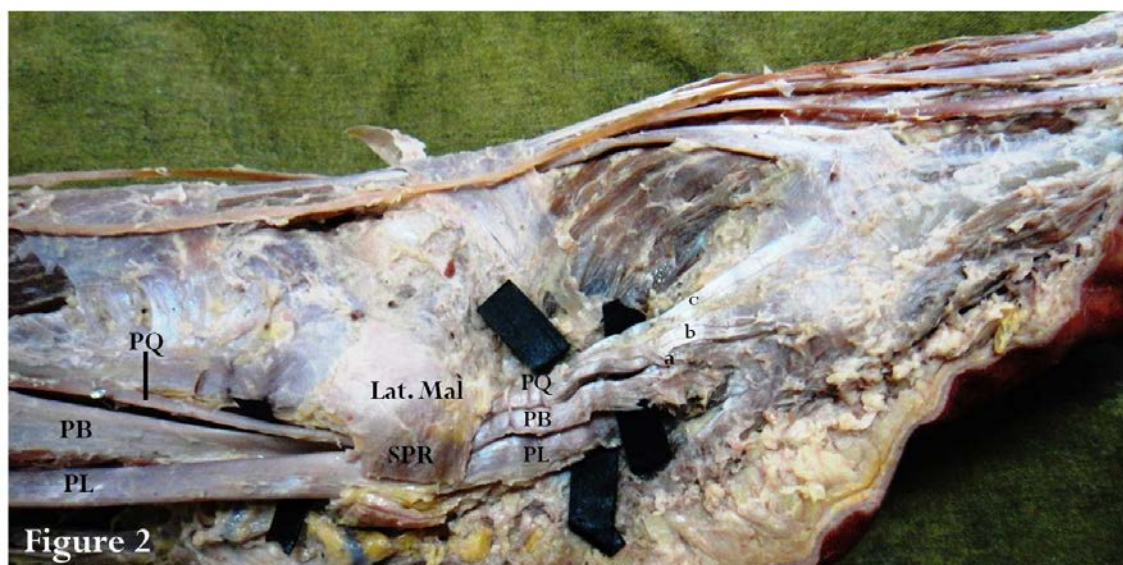


Figure 2. Lateral side of the ankle showing the tendons of peroneus longus (PL) and brevis (PB) having a normal course and insertion. The additional tendon (PQ) when traced further after emerging from superior peroneal retinaculum (SPR), divided into 3 slips- a) to the base of the fifth metatarsal bone along with the PB, b) to the shaft of the fifth metatarsal bone c) to the base of the fourth metatarsal bone. Lat. Mal = lateral malleolus.

DISCUSSION

The PQ muscle is one among the accessory peroneal muscles present in man. Its occurrence was first described by Otto in 1816 and studied in depth in 1923 by Hecker, who estimated its incidence to be 13% in the general population⁴. Various anatomists have described and named the muscle based on its multiple origins and insertions. In a cadaveric study comprising of 124 lower limbs, Sobel, and his co-workers suggested that these should all be referred to as variants of the same muscle, the peroneus quartus (PQ). They showed that it was present in 21.7% of cadavers. The most frequent origin was from the muscle fibres of PB and its most frequent insertion was into the retrotrochlear eminence of the calcaneum. The PQ muscle although usually stems from the peroneus brevis; however some cases of emergence from the PL were also reported i.e., 15% of cases for Sobel et al⁵. In the present case, PQ was found to arise both from the PB and PL.

Insertions also can be variable and into several sites. Authors have been arguing about the

most common insertion site. In a study by Zammit and his co-workers, the retrotrochlear eminence of the calcaneum was the commonest site of insertion as observed in 50% of the dissections and 83% of MRI exams¹. This was in general agreement with Cheung et al. who observed them in 78% of the cases⁶. Sobel et al. reported the insertion as the peroneal tubercle of the calcaneum in 63% of the cases⁵. Authors have also reported distinct fibers arising from peroneus brevis and inserting to the base of the fifth metatarsal bone superior to the insertion of PB. The variant muscle was found to originate from the distal fibula, lying posterior to the peroneus brevis and sending a fleshy contribution to this muscle before passing beneath the superior peroneal retinaculum to insert into the cuboid¹.

In the present case the tendon of the PQ after arising from PB and gaining little contributions from PL, became flattened and inserted mainly into the lateral side of the base of the fifth metatarsal along with the PB. It also provided additional slips distal to the insertion of the PB and also a long tendinous extension to the dorso-lateral part of the shaft of the fifth metatarsal bone and to the base of the

fourth metatarsal bone. The role of musculoskeletal sonography in the evaluation of patients presenting with peroneal (fibularis) tendon disorders is well established⁷. When three tendinous structures are envisioned in the retromalleolar region, the differential diagnosis is generally limited to a longitudinal split tear of the peroneus brevis, resulting in two hemitendons, or a peroneus quartus^{8,9}. The peroneus quartus is identified by its typical location posterior and medial to the tendons of PL and PB tendons, whereas the split brevis hemitendons are positioned anteriorly in the retromalleolar groove, adjacent to the fibula^{1,8,9}. Unlike the above mentioned fact, in the present case the tendon of PQ was located anterior to PL and superficial to PB in the retromalleolar region. Thus the location of the anomalous tendon was atypical for the traditionally described peroneus quartus. Therefore sonologists and sonographers should consider this variation when scanning patients with suspected peroneal tendon disorders to avoid misdiagnosis.

The presence of peroneus quartus muscle is usually asymptomatic. Occasionally, however, it can cause crowding in the retromalleolar groove, laxity of the superior peroneal retinaculum predisposing to peroneus brevis tendon dislocation and tear¹⁰. It can also be a source of pain in the lateral hindfoot area, particularly in relation with a lesion of the PB tendon¹¹.

Earlier it was shown that, the peroneus quartus muscle was the cause for chronic lateral ankle pain in a female professional Ballet Dancer¹² and in a professional high jump athlete¹³. In different cases of patients with chronic pain and swelling around the ankle after lateral ankle sprain, the surgical exploration revealed the presence of PQ muscle and after conservative treatments failed, surgical resection was found to be more effective treatment¹⁴. In spite of its shortcomings, the PQ muscle has been used successfully in the reconstruction of the peroneal retinaculum for the treatment of recurrent anterior subluxations of the

peroneal tendons and has thus proved to be beneficial^{5,15}.

CONCLUSION

The knowledge of existence of such variant muscle in the lateral compartment may help the surgeon not only in diagnosing the possible associated pathology, but also in its potential use in reconstructive surgery.

REFERENCES

1. Zammit J, Singh D. The peroneus quartus muscle. Anatomy and clinical relevance. *J Bone Joint Surg Br.* 2003;85:1134–7.
2. Lepow GM, Korfin DH. Calcification of an accessory peroneal tendon in an athlete: a case presentation. *J Am Podiatr Med Assoc.* 1985;75:323-5.
3. Wachter S, Beekman S. Peroneus quartus: a case report. *J Am Podiatry Assoc.* 1983;73:523-4.
4. Hecker P. Study of the peroneus of the tarsus. *Anat Rec.* 1923;26:79-82.
5. Sobel M, Levy ME, Bohne WH. Congenital variations of the peroneus quartus muscle: An anatomic study. *Foot Ankle.* 1990;11:81-9.
6. Cheung YY, Rosenberg ZS, Ramsinghani R, Beltran J, Jahss MH. Peroneus quartus muscle: MR imaging features. *Radiology.* 1997;202:745–50.
7. Grant TH, Kelikian AS, Jereb SE, McCarthy RJ. Ultrasound diagnosis of peroneal tendon tears: a surgical correlation. *J Bone Joint Surg Am.* 2005;87:1788–94.
8. Chepuri NB, Jacobson JA, Fessell DP, Hayes CW. Sonographic appearance of the peroneus quartus muscle: correlation with MR imaging appearance in seven patients. *Radiology.* 2001;218:415–9.
9. Bianchi S, Delmi M, Molini L. Ultrasound of peroneal tendons. *Semin Musculoskelet Radiol.* 2010;3:292–306.
10. Xiao-Tian Wang, Zehava Sadka, Rosenberg, Michael B, Mechlin, Mark E, Schweitzer. Normal Variants and Diseases of the Peroneal Tendons and Superior Peroneal Retinaculum: MR Imaging Features. *RadioGraphics.* 2005;25:587–602

11. Regan TP, Hughston JC. Chronic ankle sprain secondary to anomalous peroneal tendon: A case report. *ClinOrthop*.1977;123:52-4.
12. Patrick Vienne, Tobias Wyss. Peroneus Quartus Muscle as Cause Of Chronic Lateral Ankle Pain By A Female Professional Ballet Dancer: A Case Report. *Sportmedizin und Sporttraumatologie*. 2006;54:27–8.
13. Sammarco GJ, Brainard BJ. A symptomatic anomalous peroneus brevis in a high-jumper. A case report. *J Bone Joint Surg Am*. 1991;73:131–3.
14. G. Lotito, J. Pruvost, H. Collado, J.M. Coudreuse, L. Bensoussan, G. Curvale, J.M. Viton, A. Delarque. Peroneus quartus and functional ankle instability. *Annals of Physical and Rehabilitation Medicine*. 2011;54:282–92
15. Mick CA, Lynch F. Reconstruction of the peroneal retinaculum using the peroneus quartus: a case report. *J Bone Joint Surg Am*. 1987;69:296–7.

YazışmaAdresi / Address for Correspondence:

Dr.Kumar MR Bhat
Manipal University, Kasturba Medical Collage
Department of Anatomy,
Manipal-576104, India
E-mail: kumar.mr@manipal.edu

geliştarihi/received :06.01.2014

kabultarihi/accepted:14.02.2014