



A Rare Case of Aneurysmal Bone Cyst of the Talus

Nadir Bir Talus Anevrizmal Kemik Kist Vakası

Sandesh S. Madi¹, Alok Verma¹

¹Manipal University; MGMMC, Indore. INDIA

CukurovaMedicalJournal 2014;39(4):932-937.

ABSTRACT

Talus bone is an unusual location for Aneurysmal Bone Cysts. Although considered benign, it has a locally aggressive behavior making it difficult both from diagnostic and therapeutic point of view. It becomes even more challenging when unusual sites are encountered. We report a rare and challenging case of Aneurysmal Bone Cyst in Talus in a young male patient who was treated with curettage and bone grafting.

Key Words: Talus, Aneurysmal Bone Cyst, bone tumor

ÖZET

Talus kemiği; anevrizmal kemik kisti için nadir bir lokalizasyondur. İyi huylu olarak değerlendirilmesine rağmen, onu hem teşhisi hem de tedavisi için zor yapan lokal agresif davranışa sahip olmasıdır. Hatta alışılmadık bölgelerde olduğu zaman daha da sıkıntı verici bir hal alabilmektedir. Bu makalede küretaj ve kemik grefti uygulanmış genç bir erkek hastanın Talus'unda nadir görülen ve hasta için yaşamsal olarak zorlayıcı olan bir anevrizmal kemik kisti olgusu sunulmuştur.

Anahtar Kelimeler:Talus, Anevrizmal Kemik Kisti, Kemik Tümörü

INTRODUCTION

Aneurysmal Bone Cyst (ABC) is a rare bone tumor of unknown origin and natural course. ABC represents about 1% of all primary bone tumors collectively¹ although it has been reported from most locations, this tumor has a predilection more for metaphyseal regions of long tubular bones (Femur-22%: Tibia-17%: Humerus-10%) and from Spine 12% and Pelvis-9%.² Its frequency of occurrence in foot bones is about 3% compared to other bones³ and less than 20 cases involving the Talus bone have been reported in PubMed till 2012. In fact, the most common tumors of Talus are intra-osseous ganglion cysts⁴. It is the only bone tumor to be named in the literature on the basis of its radiological appearance rather than its histopathology.

It can be primary or secondary i.e., as a collision tumor along with other osseous lesions like Chondroblastoma, Giant Cell Tumor or Osteosarcoma, in about 30% cases⁵, affecting both diagnosis and prognosis as well.

Its incidence is slightly more among females and age group of affection is around second decade. The cyst usually begins in the cancellous part of the bone and as the cyst expands it slowly erodes the surrounding cortex and also the adjacent articular bone. There are five distinct stages for the Aneurysmal Bone Cyst formation as described by Campannacci, et.al.,1986⁶.

Here we report an unusual case of primary Aneurysmal Bone Cyst in Talus in a young male patient who was treated with curettage and bone grafting.

CASE REPORT

A 30 year old male patient, electrician by occupation, came to the Department of Orthopaedics, MGMMC, Indore, India, with a chief complaint of pain in the left ankle since 6 months. The pain was insidious in onset and gradually progressive. It was dull aching in nature and present on and off. Pain aggravated with activity and relieved with rest and some pain killers. There was no history of trauma or infections. No history suggestive of any other significant medical comorbid conditions. Not a smoker or an alcoholic. In local examination, there was no obvious swelling. However, mild tenderness was noted over anterior and lateral aspect of left ankle. All peripheral pulses felt good. The range of movements of the left ankle joint was normal.

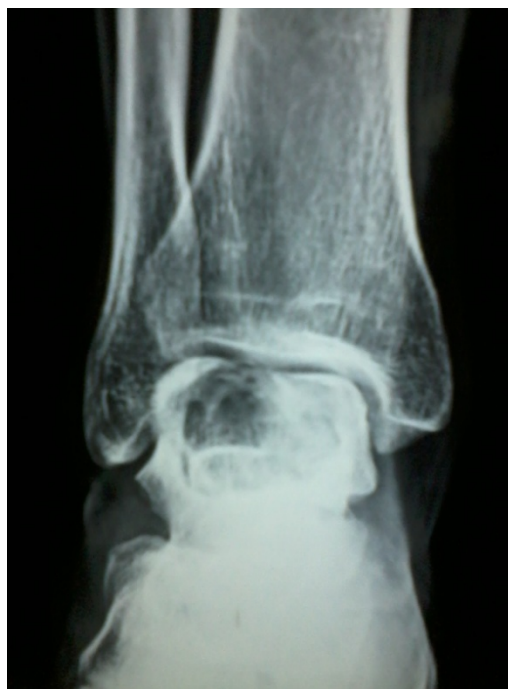Plain X-ray of the left ankle revealed a solitary well defined lytic lesion located eccentrically in antero-lateral aspect of body of Talus. Articular surface appeared intact. It had a geographic pattern of bone destruction. No periosteal reaction was seen. (Fig 1 and 2). 3-D CT scan of the left ankle further defined subtle internal septations and scalloped margins. However, there was no cortical breach (Fig 3, 4 and 5). A differential diagnosis of Giant Cell Tumor, subacute infection and Aneurysmal bone cyst (although an unusual location) were considered.

Patient was planned for operation for open biopsy and subsequently curettage of lesion and bone grafting. An anterolateral approach to the ankle along with distal fibular osteotomy was done to directly access the lesion. A small cortical window was made over the lateral wall of Talus. On gross examination, a well circumscribed hemorrhagic cystic space with some fibrous septae was seen. No macroscopic feature of malignancy was evident (Fig 6 and 7).

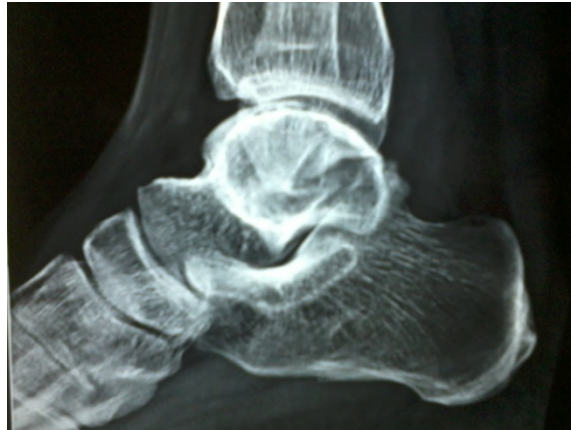The specimen was sent for histopathological examination. Adequate curettage of the lesion was done. Suspecting it to be an Aneurysmal Bone Cyst (notorious for its recurrence), chemical cauterization with phenol soaked swabs was also

done. The core of the empty cavity was filled with hydroxapatite bone graft substitute blocks (G bone) and the remaining void was filled with autologous cortico-cancellous bone grafts harvested from ipsilateral iliac crest. A 6mm cancellous screw was used to fix fibula. Post operative period was uneventful and patient was discharged with a below knee slab support. He was advised non-weight bearing for six weeks and further four weeks he was allowed partial weight bearing in walking boots. Subsequent monthly follow ups for the last one year have shown dramatic improvement and no signs of recurrence (Figure 8 and 9).

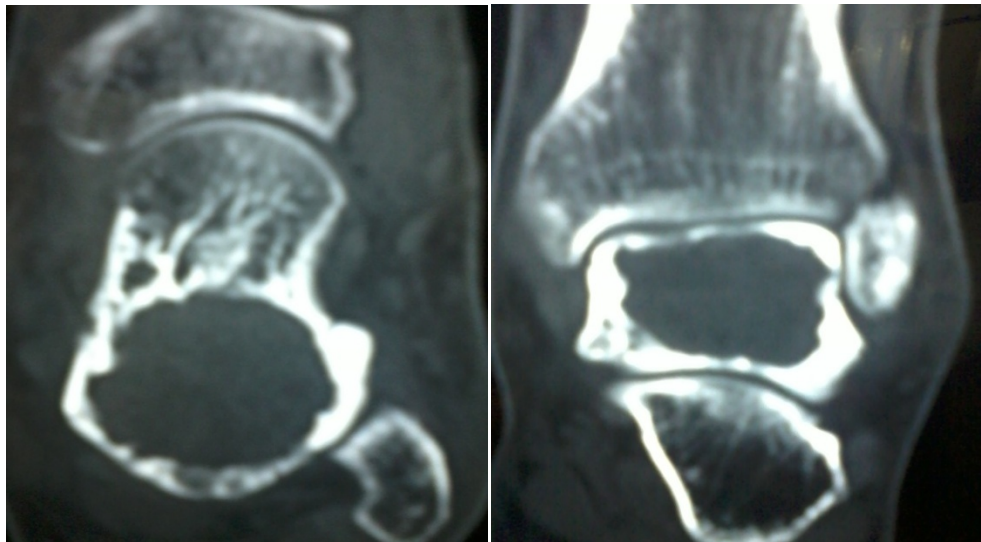Histopathology revealed many vascular canals filled with blood and fibrous bands containing stromal cells of giant cell type seen. Some osteoid were also noted (Figure10). The findings were suggestive of Aneurysmal bone cyst.



Resim 1. X-ray anteroposterior lateral view

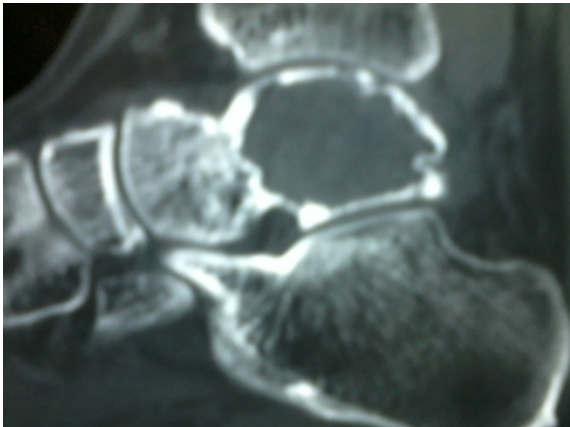


Resim 2.X-ray lateral view

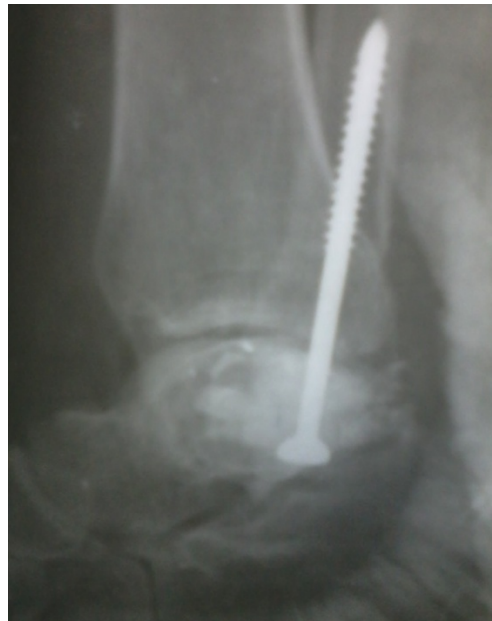

Resim 3.Axial CT view

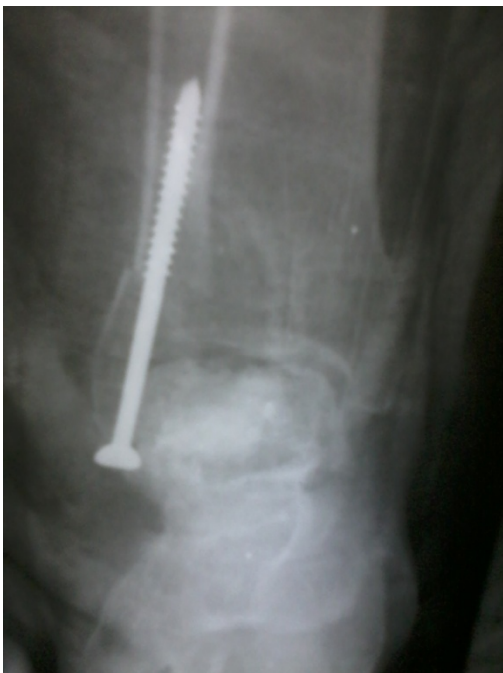Resim 4. CT coronal view



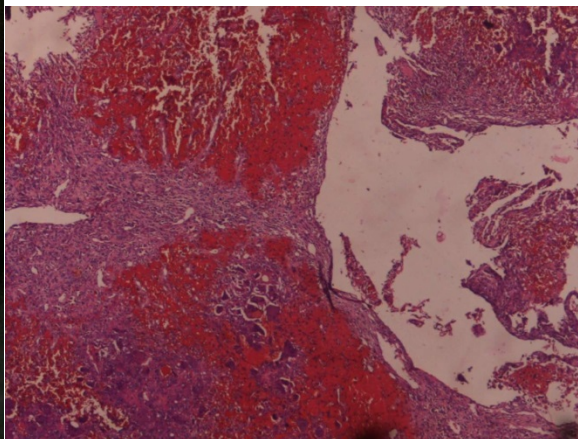
Resim 5.CT sagittal view



Resim 6. Immediate post operative photo.



Resim 7. Follow up at 1 year



Resim 8.Photomicrograph of histopathology.

DISCUSSION

Aneurysmal Bone Cyst has become a common bone tumor in literature since it was first described by Jaffe and Lichtenstein in 1942⁷ yet, it has still remained an enigma in terms of etiology and pathogenesis. It is also difficult to make a diagnosis and distinguish it from other benign and malignant lesions solely based on radiology. Classically described as an expansile, eccentrically located lytic lesion, with “soap-bubble” appearance and outlined by a rim of subperiosteal bone. CT scans further demonstrates its multi-loculations and defines the extent of lesion. MR imaging verifies the expansile nature of the cyst containing septa and the fluid levels⁸.

A number of differential diagnoses are still warranted, like Giant Cell Tumor, ChondroMyxoid Fibroma, and Telangiectatic Osteosarcoma. Distinction among these is difficult. Accurate evaluation rests upon entities like age of presentation, location of the lesion, progression rate, and histopathological features, all of which helps us to come to a reasonable conclusion⁹.

Histopathological examination demonstrates the basic fibrous matrix in which there are numerous small and large blood filled spaces. Hemorrhage into these fibrous walls is frequently seen and in these areas, hemosiderin and giant cells may be abundant. Osteoid and new bone formation may also be found in the fibrous tissue lining the vascular spaces¹⁰.

A number of treatment options exist, but it depends upon the site and predilection for recurrence. Curettage and bone grafting, use of a high speed burr¹¹, liquid nitrogen, phenol, use of polymethylmethacrylate, bone graft substitutes, en bloc resection, selective arterial embolization and radiation² are some of the many treatment modalities available at present. Debulking the lesion by intralesional curettage and autologous bone grafting has shown satisfying results.

We treated this case with curettage and autologous bone grafting and also used bone graft substitutes to fill up the bone void. Here, Phenol was also used as an adjuvant. Aneurysmal bone cysts are notorious for being locally aggressive and have a tendency to recur. Their behavior in rate of progression is also unpredictable. Staging is helpful in planning the treatment. But, whenever an unusual location like talus is encountered we believe an aggressive approach towards treating this tumor is justified and a close follow up for any signs of recurrence is also warranted.

REFERENCES

1. Duke Orthopaedics: Wheeler's Textbook of Orthopaedics, Aneurysmal Bone Cyst, Online article, Jan 2007
2. Cottarolda J, Bourelle S. Current treatments of primary aneurysmal bone cysts. *J PediatrOrthop.*2006;15-B:155-67.
3. Anand MK, Wang EA. Aneurysmal Bone Cyst. *eMedicine*, Jan, 2007
4. Sharma S, Gupta P, Sharma S, Singh M, Singh D. Primary aneurysmal bone cyst of talus. *J Res Med Sci.* 2012;17:1192-94.
5. Cottarolda J, Bourelle S. Modern concepts of primary aneurysmal bone cyst. *Arch OrthopTrauma Surg.*2007;127:105-14.
6. Campanacci M. et al. Unicameral and aneurysmal bone cysts: A study of 416 UBC and 198 ABC. *ClinOrthop.* 1986;204:25.
7. Jaffe, H. L. & Lichtenstein, L. Solitary unicameral bone cyst with emphasis on the roentgen picture, the pathologic appearance and the pathogenesis. *Arch.Surg.* 1942;44:1004.
8. Mendenhall WM, Zlotecki AR, Gibbs CP et al. Aneurysmal bone cyst. *Am J ClinOncol.*2006;29:311-5.
9. Megas P, Papathanassiou ZG, Kasimatis G, Papachristou DJ. Aneurysmal bone cyst of the

- scapula a case report. Acta Orthop Belg. 2009;75:684-9.
10. Frank A, Slowick Jr, Crawford J et al. Aneurysmal Bone Cyst : An analysis of thirteen cases. J Bone Joint Surg. 1968;50-A:1142-51.
11. Gibbs CP Jr et al., Aneurysmal Bone Cyst of the Extremities: factors related to local recurrence after curettage with high speed burr. J Bone Joint Surg Am. 1999;81:1671-8.

Yazışma Adresi / Address for Correspondence:

Dr. Sandesh S Madi
Manipal University
MGMMC, Indore-INDIA
E-mail: madimania@gmail.com

Geliş tarihi/Received on : 20.04.2014

Kabul tarihi/Accepted on: 26.05.2014