



Diabetic Lymphocytic Mastitis: A Clinico-Imaging Mimicker of Malignancy

Diyabetik Lenfositik Meme İltihabı: Malinitenin Klinik-Görüntüleme Taklitçisi

Smita B. Sankaye¹, Sushil Ghanshyam Kachewar¹

¹Rural Medical College, PIMS(DU), Loni, Ta-Rahata, Ahmednagar Maharashtra, INDIA

CukurovaMedicalJournal 2014;39(4):950-954.

ABSTRACT

The clinical and imaging appearance of diabetic lymphocytic mastitis and stromal fibrosis very much resembles a malignant lesion. These clinico-imaging findings are not specific and often create doubts about possibility of underlying malignancy ultimately leading to biopsy. Accurate diagnosis can reduce patient's anxiety and prevent unnecessary surgery as these lesions are known to recur. Therefore, we present a classic case of this entity for the benefit of one and all.

Key Words:Lymphocytic mastitis Breast Imaging; Diabetes; Breast cancer

ÖZET

Diyabetik lenfositik meme iltihabı ve stromalfibrozis'in klinik ve görüntüleme sonuçları malin lezyonlara oldukça benzemektedirler. Bu klinik-görüntüleme bulguları spesifik değildir ve altta yatan malinite olasılığı hakkında genellikle şüpheyi meydana getirmektedir ki bu da sonunda biyopsiye sebep olmaktadır. Doğru teşhis hastanın kaygısını azaltabilir ve nüksettiği bilinen bu lezyonların gereksiz cerrahi müdahalelerini önleyebilir. Dolayısıyla, burada benzer bir durum söz konusu olduğunda faydalı olabilecek klasik bir vakayı sunmaktayız.

Anahtar Kelimeler: Diyabet, Meme görüntüleme, Meme Kanseri, Lenfositik Meme İltihabı

INTRODUCTION

Soler and Khardori were the first to describe the clinico-imaging features of breast masses in diabetic patients¹. Now, this entity is thought to be responsible for < 1% of benign breast lesions². Usually long-standing type 1 or type 2 diabetic patients are affected by it^{3,4,5}.

Because of their slow growth and painless nature, the breast masses are ignored by males as well as females. Conventional X-ray mammogram often demonstrates a focal or diffuse dense mass which on the Sonomammogram shows irregular margins and diffuses posterior acoustic shadowing⁶.

The combination of clinico-radiological findings is not very specific for any single etiology and the patients usually lands for histopathological confirmation which reveals the true benign nature of this malignancy.

CASE REPORT

A 42 years lady, with a 3.2 year history of type 2 diabetes, presented with a painless palpable lump in her right breast which she had noticed recently. There was no other significant personal or family history.

Physical examination revealed a firm, irregular, mobile, painless nodule in her right breast. No nipple discharge, skin abnormalities or any axillary lymphadenopathy was present.

Conventional X-ray mammogram showed nodular radio-opacity opacity in the right breast with speculated margins, taller than wider located

in the heterogeneous dense breast parenchyma, highly suspicious of malignancy. No abnormal micro calcifications, other masses, or architectural distortions were evident. The skin over it was neither thickened nor was the nipple puckered (Figure 1).

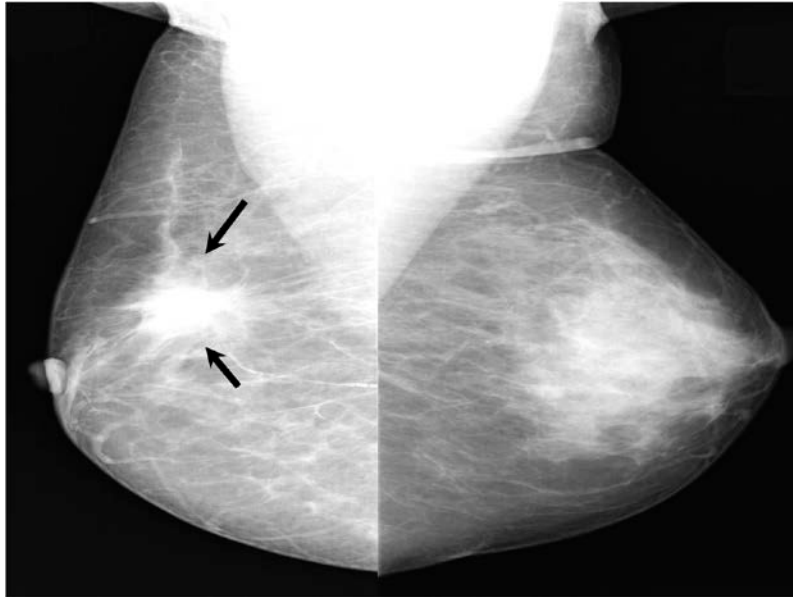


Figure 1.X- Ray Mammogram showing irregularly marginated suspicious opacity in right breast

Sonomammogram of the right breast showed a heterogeneous predominantly hypoechoic solid mass with irregular contours measuring 2.4 x

3.9cm; parts of which demonstrated posterior acoustic shadowing (Figure 2).

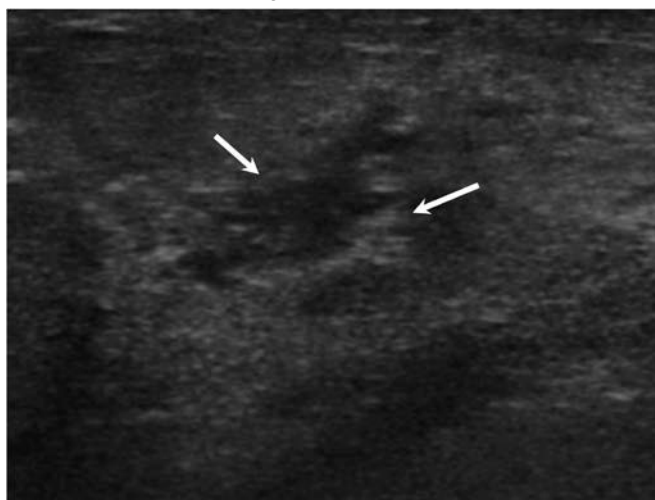


Figure 2.Sono Mammogram of right breast showing irregularly marginated hypoechoic solid lesion in right breast

Breast MRI could not be performed due to its local unavailability and patient's in-affordability.

As clinico-imaging features were highly suspicious of a neoplastic breast mass, a biopsy

was performed and it showed periductal lymphocytic infiltration without any evidence of atypia or malignancy amidst dense stromal fibrosis (Figure 3).

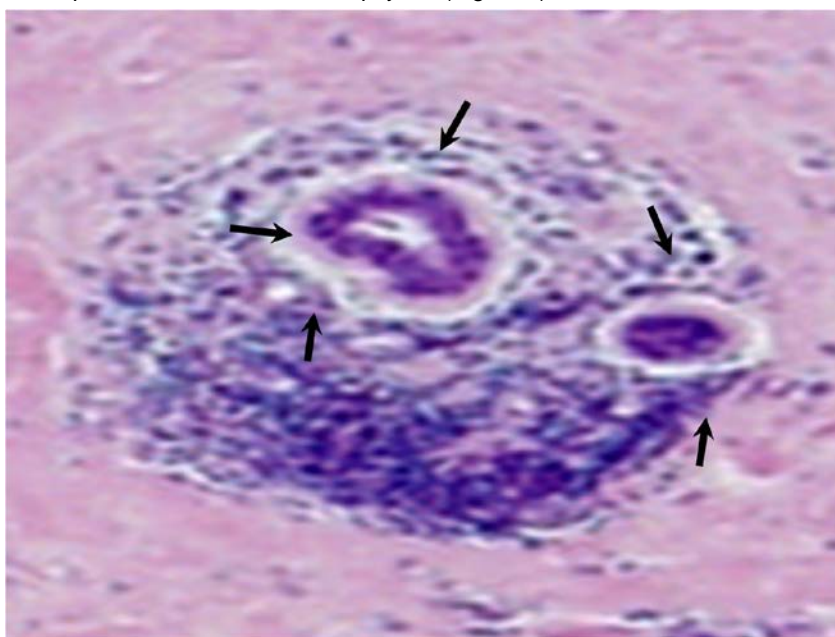


Figure 3. The biopsy from suspicious lesion shows lymphocytic infiltration around the ducts and marked stromal fibrosis on H & E Stain at 40X power – Diabetic Lymphocytic Mastitis

DISCUSSION

Diabetic Lymphocytic Mastitis (DLM) occurs in 0.6% to 13% in women with type 1 diabetes;^{1,2} and is a rare self-limiting fibro-inflammatory course. These patients are usually known to have other associated complications arising from diabetes such as retinopathy, neuropathy and nephropathy.¹ The patient reported by us had no such associated complications.

DLM has also been reported in patients with type 2 diabetes as well as those with thyroid diseases and also in men³.

Palpation demonstrates the firm, mobile, painless palpable, unilateral or bilateral breast masses suspicious of malignancy^{1,2,5}. Our patient too had firm, mobile and painless mass in her right breast.

X-ray mammogram brings out the localized increased density, with or without any distinct

masses, devoid of spiculation or calcifications. Posterior acoustical shadowing from the palpable breast masses is the hallmark on Sonomammogram, which was also seen in our case. The underlying fibrotic nature of the lesions is the cause for this appearance².

Because the imaging features are not specific of DLM, many times it is not possible to differentiate benign mass from a malignant one without biopsy^{6,7,8}.

On ultrasound guided fine needle aspiration cytology an unusually firm resistance experienced during the back-and-forward motion of the needle is the clue to the diagnosis of DLM⁹. The ductal epithelium shows no signs of malignancy and characteristically has densely hyalinised fibrous tissue with paucity or even absence of cellular material as well as adipose tissue. There is a rich

focal periductal, perivascular and perilobular lymphocytic infiltration with mature B-cell predominance. Epithelioid fibroblasts in the interlobular stroma may also be seen^{5,9}. Our patient too had similar pathological findings.

Contrast-enhanced Computerized Tomography Scan (CT) findings of DLM too are a vague and show irregular mass with poor enhancement in early phase and heterogeneous spotty enhancement on delayed phase¹⁰. Magnetic Resonance Imaging (MRI) in such cases also shows poor enhancement in the early phase that increases gradually so that finally, the mass shows heterogeneous spotty enhancement in the delayed phase¹¹.

Although scirrhous cancer may show similar findings, heterogeneous spotty enhancement may be one of the typical findings of lymphocytic mastitis on CT and MRI images.

Surgery should better be avoided as the entity is known to recur². Instead, a periodic imaging follow up would be helpful to assure to the patient that all is well. It is now believed that secondary autoimmune reaction to abnormal extracellular matrix accumulation arising from the effects of hyperglycemia on connective tissue is the underlying mechanism of pathogenesis. Glycosylation induced by hyperglycemia, increases intermolecular cross-linkage and matrix expansion of altered quality and quantity which resists degradation. The triggered autoimmune response manifests with autoantibody production and B-cell proliferation^{2,3,4}.

To the best of our knowledge regression of this entity has been reported but malignant transformation of these lesions is never reported yet⁵.

Paucity of reports on DLM is the reason why there are no standard protocols for the long-term management of these patients. We believe that yearly follow up by imaging studies would be useful in identifying the progression and detection of other abnormalities at the earliest.

Hence it is only the knowledge about this rare entity and a careful clinico-imaging-pathological correlation in the appropriate clinical setting of diabetes can one identify this entity and avoid unnecessary surgical biopsy and diagnostic dilemma.

REFERENCES

1. Soler NG, Khardori R. Fibrous disease of the breast, thyroiditis, and cheiroarthropathy in type I diabetes mellitus. *Lancet*.1984;1:193-5.
2. Camuto P, Zetrenne E, Ponn T. Diabetic Mastopathy: A Report of 5 Cases and a Review of the Literature. *Arch Surg*.2000;135:1190-3.
3. Neetu G, Pathmanathan R, Weng NK. Diabetic Mastopathy: A Case Report and Literature Review. *Case Rep Oncol*.2010;3:245-51.
4. Tomaszewski JE, Brooks JS, Hicks D, Livolsi VA. Diabetic mastopathy: a distinctive clinicopathologic entity. *Hum Pathol*.1992;23:780-6.
5. Mak CW, Chou CK, Chen Y, Lee PS and Chang JM. Diabetic mastopathy. *The British Journal of Radiology*. 2003;76:192-4.
6. Sankaye SB, Kachewar SG. Diabetic mastopathy *AMJ*. 2012;5:296-9.
7. Wong KT, Tse GMK, Yang WT. Ultrasound and MR imaging of diabetic mastopathy. *ClinRadiol*.2002;57:730-5.
8. Kachewar SG, Sankaye SB. Reviewer index: a new proposal of rewarding the reviewer. *Mens Sana Monogr*. 2013;11:274-84.
9. Logan WW, Hoffman NY. Diabetic fibrous breast disease. *Radiology*.1989;172:667-70.
10. Yajima S, Fukutomi T, Akashi-Tanaka A, Nanasawa T, Miyakawa K and Hasegawa T. Diabetic mastopathy:a case report with reference to the findings of enhanced computed tomography. *Breast Cancer*.2001;8:246-9.
11. Sakuhara Y, Shinozaki T, Hozumi Y, Ogura S, Omoto K and Furuse M. MR Imaging of Diabetic Mastopathy. *Am J Roentgenol*.2002;179:1201-3.

YazışmaAdresi / Address for Correspondence:

Dr.Smita B. Sankaye
Rural Medical College, PIMS (DU)
Loni, Ta-Rahata,Ahmednagar Maharashtra
INDIA
E-mail: smitasankaye@gmail.com

Geliştarihi/Received on : 27.04.2014

Kabul tarihi/Accepted on: 30.05.2014