



Bell's Palsy: A Case Report and Literature Review

Bell Palsisi: Bir Olgu Sunumu ve Gözden Geçirme

Tashika Kushraj¹, Laxmikanth Chatra¹, Prashanth Shenai¹, K M Veena¹, Prasanna Kumar Rao¹, Rachana V Prabhu¹, Prathima Shetty¹, K A Shahin¹

¹Department of Oral Medicine and Radiology, Yenepoya Dental College, Yenepoya University, Mangalore, Karnataka, INDIA.

Cukurova Medical Journal 2014;39(3):581-588.

ABSTRACT

Bell's palsy is considered as a disease of exclusion. It is a form of lower motor neuron paralysis affecting the facial muscles. Rapid onset of paralysis causes panic to the patients. For speedy recovery, correct diagnosis and early treatment are crucial. Here a case of Bell's palsy is reported and the literature on Bell's palsy is reviewed.

Key Words: Bell's palsy, idiopathic facial palsy, facial nerve.

ÖZET

Bell palsisinin dışlanmış bir hastalık olduğu düşünülür. Bu hastalık yüz kaslarını etkileyen aşağı motor nöron felcinin bir formudur. Bir anda başlayan felç durumu hastalarda paniğe yol açmaktadır. Hastalığın hızlı iyileşmesinde, doğru teşhis ve erken müdahale oldukça önemlidir. Burada Bell'in palsisi ile ilgili bir vaka rapor edilmekte olup aynı zamanda Bell palsisi ile ilgili literatürde derlenmiştir.

Anahtar Kelimeler: Bell'in palsisi, idyopatik fasiyal palsisi, fasiyal sinir

INTRODUCTION

Bell's palsy is a form of facial paralysis where the cause is not attributed to any local or systemic factors¹. The term was first coined by Dr Charles Bell of Edeinburgh in 1882. The various triggering factors includes pregnancy, diabetes, cold, respiratory distress or due to infection with a virus. Reactivation of herpes simplex virus [HSV-1] present in the saliva of patients with Bell's palsy is another factor implicated in the pathogenesis of this condition.^[2] Inflammation of the facial nerve followed by demyelination and edema in the stylomastoid foramen further causes decreased blood supply. Although Bell's palsy is a disease of

exclusion, a large number of cases are misdiagnosed. In this article a case of Bell's palsy is reported and the literature on Bells palsy is reviewed.

Case History: A 68 years old male patient reported with a complaint of inability to open mouth widely or smile and also of inability to raise his eyebrows. He reported that the problems were of sudden onset 5 years back. Patient does not recollect any trauma or accident or ear infection or any significant infections. Patient does not report any taste abnormality or decrease in salivary secretion. The patient did not complaint of any difficulty in eating or drinking. He complained of slurring of speech, inability to close in eyelids. He also demonstrated loss of voluntary control over

eyelids and inability to blow out left cheek. No relevant medical history was elicited by the patient. Extra oral examination revealed gross facial asymmetry with deviation of the face to the right during movements and at rest the patient has an expressionless face.

Evaluation of the muscles supplied by five branches of facial nerve was performed. On examination of the frontalis muscle supplied by the temporal branch the patient demonstrated inability to raise eyebrows and mild loss of horizontal folds on left side of the forehead. Examination of the orbicularis oculi muscle supplied by the zygomatic branch revealed inability to close eyelids tightly. Examination of the buccinators/orbicularis oris

muscle supplied by the buccal branch revealed inability to blow air [Figure 1A, B & C]. Examination of the buccinators/orbicularis oris muscle supplied by the mandibular branch revealed inability to evert his lips on the left side. Examination of the platysma muscle supplied by the cervical branch of the facial nerve revealed inability to clench his teeth and grin on the left side. Intra oral examination revealed grossly decayed tooth in relation to 35, decayed 13, 45 and plaque and calculus deposits. Chairside examinations revealed positive Joffroy's sign on the left side, Bell's phenomenon and water holding test were positive. Test for hypoglossal nerve was negative.

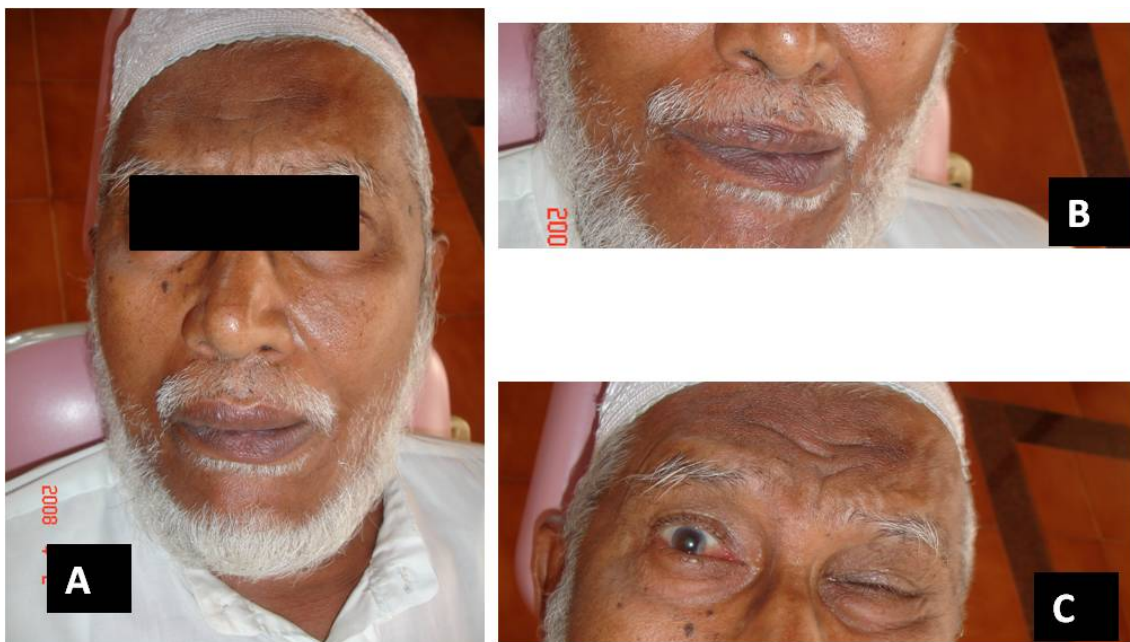

Figure 1. A- Expressionless face, B- Drooping of the Right lower lip, C- Inability to close eyelids on the right side

The differential diagnosis considered were, firstly Ramsay Hunt Syndrome. Lack of history of infection and absence of vesicles in the ear excluded this condition. The case reported here did not give any history of tick exposure, arthralgias or rash, so Lyme disease was excluded. There was no history of pain near the ear and the onset was sudden thus otitis media and lesions

secondary to lesion within parotid gland was ruled out where the onset is gradual. Supranuclear lesions were ruled out because the patient's frontalis muscles on the left side were weak as compared to the normal side moreover the patient did not have weakness in his extremities which are characteristically present in supranuclear lesions.

Based on the history and clinical examination a final diagnosis of Bells palsy of the left side of the face was established. The other diagnosis were chronic generalized periodontitis, dental caries in relation to upper right canine and lower right and left second premolars and partial edentulous spaces in relation to upper and lower posteriors.

Treatment plan of the patient included extraction of lower left second premolar, oral prophylaxis, and restoration of to upper right canine and lower right second premolars and replacement of missing teeth. Since the patient reported to us after 5 years of onset of facial paralysis , steroids and antiviral drugs were not prescribed because recovery rate is poor considering the time lap and the adverse effects overweights the benefits of treatment. The patient was advised to wear sunglasses during daylight to prevent corneal drying and advised ophthalmic follow up.

DISCUSSION

Bell's palsy is defined as an idiopathic unilateral facial nerve paralysis, usually self-limiting. The condition is characterized by sudden onset of complete or partial facial paralysis that usually occurs overnight^{3,4}. The onset of paralysis is accompanied by pain near the mastoid process in majority of the cases along with excess tearing 33%, hyperacusis and dysgeusia. The signs include unilateral facial weakness, stapedius dysfunction and taste and sensory abnormalities on the affected side. However 1% of unilateral cases, bilateral involvement are seen. In our case the patient reported a history of sudden onset of unilateral paralysis without hyperacusis and dysgeusia.

Incidence of Bell's palsy increases with age, in diabetics and in the third trimester of pregnancy.^[5] In around 63% of cases right side of the face is paralyzed. Recurrence rate is up to 7%. The reported patient is 68years old and nondiabetic

and had paralysis on the left side with no history of recurrence.

The ethiopathogenesis of Bell's palsy is controversial. Various trigger factors like trauma, stresses like emotional, environmental [cold], metabolic disturbances have been suggested which probably reactivates dormant viral infection^{6,7}. Herpes group of viruses have been detected by PCR within the facial nerve and HSV 1 has been implicated in the pathogenesis of the disease. In a recent study [2006] HSV 1 has been isolated in the saliva of Bell's palsy patients and concluded that viral reactivation as the possible etiology of the disease⁸.

Bell's palsy characterizes by the involvement of one nerve but sometimes patients have myriad neurological symptoms like tingling sensation of the face, mild to moderate neck pain or head ache, balance problems, ipsilateral limb weakness and memory problems⁹.

Our patient however did not report these symptoms.

Other conditions that can produce isolated facial nerve palsy identical to Bell's palsy are Ramsay Hunt Syndrome, where the cause is reactivation of existing herpes zoster infection leading to facial paralysis. The major differences are the presence of small vesicles on the external ear and hearing disturbances, but these findings may occasionally be lacking (zoster sine herpete). Structural lesions in the ear or parotid gland (e.g., cholesteatoma, salivary tumors) may produce facial nerve compression and paralysis. Lyme disease can be considered in endemic areas; however it often has a history of tick exposure, rash, or arthralgias and lyme specific antibodies in the blood. Facial nerve palsies from acute and chronic otitis media have a more gradual onset, with accompanying ear pain and fever. Tumors will present with a more insidious onset of symptoms over weeks or months. Central nervous system lesions (e.g., multiple sclerosis, stroke, and tumor) can also cause facial nerve palsy. However, some

motor neurons to the forehead cross sides at the level of the brainstem, so the fibers in the facial nerve going to the forehead come from both cerebral hemispheres (Figure 2). Supranuclear (central) lesions affecting the facial nerve will not paralyze the forehead on the affected side, resulting in a unilateral facial paralysis with forehead sparing. Often, there will be at least some weakness of extremities on the affected side as well^{10,11, 12}.

In the past influenza vaccines were known to cause facial paralysis by around 2 weeks of administration. However recent vaccines have not reported with these complications^{13,14,15,16}. In the clinical evaluation, a patient with an acute onset of

unilateral facial weakness, the most probable diagnosis is Bell's palsy. A careful history of the onset and progression of paralysis is important because gradual onset of more than two weeks' duration give a strong indication of a mass lesion. Medical history should include recent rashes, arthralgias, fevers; history of peripheral nerve palsy; exposure to influenza vaccine or new medications; and exposure to ticks or areas where Lyme disease is endemic. The physical examination should include inspection of the ear canal, tympanic membrane, and oropharynx, palpation of the parotid gland and evaluation of peripheral nerve function in the extremities.

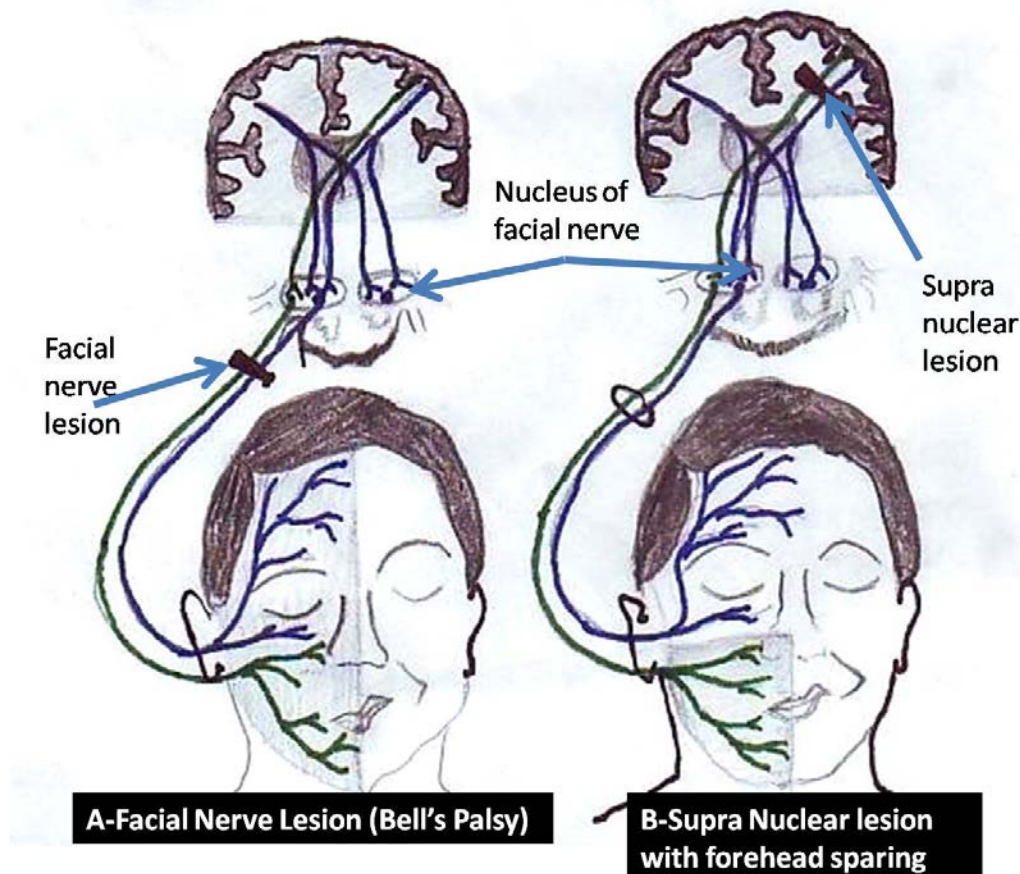


Figure 2.-A-facial nerve lesion [Bell's palsy], B- supranuclear lesion with forehead muscles sparing.

The degree of nerve damage can be assessed using the House-Brackmann score. The grading system developed by House and Brackmann categorizes Bell palsy on a scale of I to VI^{17,18,19}.

Grade I - Normal facial function.

Grade II - Mild dysfunction. Characteristics include Slight weakness is noted on close inspection, Slight synkinesis may be present, Normal symmetry and tone are noted at rest, Forehead motion is moderate to good, Complete eye closure is achieved with minimal effort, Slight mouth asymmetry is noted.

Grade III - Moderate dysfunction. The characteristics includes An obvious, but not disfiguring, difference is noted between the 2 sides , A noticeable, but not severe, synkinesis, contracture, or hemifacial spasm is present, Normal symmetry and tone are noted at rest, Forehead movement is slight to moderate, Complete eye closure is achieved with effort, A slightly weak mouth movement is noted with maximal effort.

Grade IV - Moderately severe dysfunction. Signs include An obvious weakness and/or disfiguring asymmetry is noted, Symmetry and tone are normal at rest, No forehead motion is observed, Eye closure is incomplete, An asymmetrical mouth is noted with maximal effort.

Grade V - Severe dysfunction. Characteristics includes Only a barely perceptible motion is noted, Asymmetry is noted at rest, No forehead motion is observed, Eye closure is incomplete, Mouth movement is only slight.

Grade VI - Total paralysis with Gross asymmetry and No movement.

In this system, grades I and II are considered good prognosis, grades III and IV represent moderate dysfunction, and grades V and VI describe poor results. Grade VI is defined as complete facial paralysis; all of the other grades are defined as incomplete facial paralysis. The patient reported here had symptoms of grade III.

Although the diagnosis of Bell's palsy is a straight forward approach, management remains controversial. The goal of treatment is to improve the function of the facial nerve and reduce neuronal damage. According to the American Academy of Neurology [AAN] guidelines 2012 steroids are highly effective in the in the recovery of the facial nerve function in new-onset Bells palsy²⁰. In a study in the year 2007 showed that complete recovery time was significantly reduced by the use of Prednisolone. Valacyclovir did not show facial recovery compared to the placebo group²¹. In the study in the year 2007and 2011 showed significant recovery by prednisolone when given within 48 hours and also showed insignificant difference in the rate of recovery between untreated patients and patients treated between 49 hours -72 hours²². The recommended dose of prednisone for the treatment of Bell palsy is 1 mg/kg or 60 mg/day for 6 days, followed by a taper, for a total of 10 days. Caution should be used in patients with active infection, Tuberculosis, Immunocompromised conditions, Pregnancy, Sarcoidosis, Sepsis, Peptic ulcer disease, Diabetes mellitus, Renal or hepatic dysfunction, and Malignant hypertension. High-dose steroids (>120 mg/day of prednisone) have been safely used to treat Bell palsy in patients with diabetes.^[23] However, optimal dosing has not been established. Caution should be used in these cases because of the risk of hyperglycemia.

Although a reasonable amount of cases have shown limited benefit from antiviral, a large number of cases may result from a viral infection^{24,25}. Hence antiviral therapy becomes mandatory in such situations. Acyclovir 400 mg can be given five times per day for seven days or valacyclovir 1 g can be given three times per day for seven days. According to the 2001 AAN use of acyclovir alone is not effective for the treatment of Bell palsy and that therapy with this agent is only possibly effective in facial recovery.^[26] According to the academy's 2012 guidelines, benefit from antivirals

has not been established^{27,28}. In an analysis by Quant et al, the routine use of antiviral agents was not warranted and the study recommended that newer antiviral agents may prove more beneficial than older antiviral agents used in the studies analyzed to date²⁹.

The non-pharmacological measures that have been used are facial exercises, neuromuscular retraining and acupuncture. These treatment modalities mainly show benefits in reducing the recovery time and no reports of adverse reactions are noted^{30,31}.

Surgical options includes Facial nerve decompression, Subocularis oculi fat (SOOF) lift, Implantable devices (eg, gold weights) placed into the eyelid, Tarsorrhaphy, Transposition of the temporalis muscle, Facial nerve grafting and Direct brow lift. The most common complication of surgery is postoperative hearing loss, affecting 3 to 15 percent of patients. The evidence of significant potential for harms and the paucity of data supporting benefits of surgery, the American Academy of Neurology currently do not recommend surgical decompression for Bell's palsy³².

CONCLUSION

Bell's palsy due to its sudden onset gives an impression of a stroke and creates panic in patients and clinicians. Hence proper history and examination is important to arrive at an accurate diagnosis. An expression-less face causes a lot of social dilemma to the patient. Various treatments are available, but early initiation of treatment is the key to recovery in majority of the cases. Although Corticosteroids remains the main mode of treatment, recent implication of viruses in the pathogenesis demands antiviral treatment. If antiviral agents are used, they should be initiated in conjunction with corticosteroids. Future studies will be needed to determine which population will most benefit from antiviral therapy.

REFERENCES

1. Scully C, Cawson R A .Medical problems in dentistry. 5th edition,2005: Elsevier. New Delhi. 2005;308-14.
2. Yasushi F, Satoshi F, Eiji C, Tsuyoshi T, Fumio O, Yukio I, Kazuo N . Reactivation of herpes simplex type 1 in patients with Bell's palsy.J. Med. Virol. 1998;54:162-66.
3. Kim YH, Choi IJ, Kim HM, Ban JH, Cho CH, Ahn JH. Bilateral simultaneous facial nerve palsy: clinical analysis in seven cases. Otol Neurotol. Apr. 2008;29:397-400.
4. Gilden DH. Clinical practice. Bell's Palsy. N Engl J Med. 2004;351:1323-31.
5. Vrabec JT, Isaacson B, VanHook JW: Bell's palsy and pregnancy. Otolaryngol Head Neck Surg. 2007;137:858-61.
6. Vanopdenbosch L J, Verhoeven K ,Casselmann J W: Bell's palsy with ipsilateral numbness, J Neurol Neurosurg Psychiatry. 2005;76:1017-8
7. Ahmed A When is facial paralysis Bell palsy? Current diagnosis and treatment. Cleve Clin J Med. 2005;72:398-401.
8. Paulo Roberto Lazarinil; Melissa Ferreira Viannall; Mônica Porto Alves Alcantarall; Rodolfo Alexander Scaliall; Hélio Hehl Caiaffa FilhoIII. Herpes Simplex Virus in the saliva of peripheral Bell's palsy patients. Rev. Bras. Otorrinolaringol. 2006vol.72 no.1 <http://dx.doi.org/10.1590/S0034-72992006000100002>.
9. Morris AM, Deeks SL, Hill MD et al.. "Annualized incidence and spectrum of illness from an outbreak investigation of Bell's palsy". Neuroepidemiology. 2002;21:255-61.
10. Gilden DH. Clinical practice. Bell's palsy. N Engl J Med. 2004;351:1323-31.
11. Makeham TP, Croxson GR, Coulson S. Infective causes of facial nerve paralysis. Otol Neurotol. 2007;28:100-3.
12. Redaelli de Zinis LO, Gamba P, Balzanelli C. Acute otitis media and facial nerve paralysis in adults. Otol Neurotol. 2003;24:113-7.

13. Zhou W, Pool V, DeStefano F, Iskander JK, Haber P, Chen RT, for the VAERS Working Group. A potential signal of Bell's palsy after parenteral inactivated influenza vaccines: reports to the Vaccine Adverse Event Reporting System (VAERS)—United States, 1991-2001. *Pharmacoepidemiol Drug Saf* 2004;13:505-10.
14. Izurieta HS, Haber P, Wise RP, Iskander J, Pratt D, Mink C, et al. Adverse events reported following live, cold-adapted, intranasal influenza vaccine [Published correction appears in *JAMA* 2005;294:3092]. *JAMA*. 2005;294:2720-725.
15. Zhou W, Pool V, Iskander JK, English-Bullard R, Ball R, Wise RP, et al. Surveillance for safety after immunization: Vaccine Adverse Event Reporting System (VAERS)—United States, 1991-2001 [Published correction appears in *MMWR Morb Mortal Wkly Rep* 2003;52:113]. *MMWR Surveill Summ*. 2003;52:1-24.
16. Mutsch M, Zhou W, Rhodes P, Bopp M, Chen RT, Linder T, et al. Use of the inactivated intranasal influenza vaccine and the risk of Bell's palsy in Switzerland. *N Engl J Med*. 2004;350:896-903.
17. Vrabec JT, Backous DD, Djalilian HR, Gidley PW, Leonetti JP, Marzo SJ, et al. Facial Nerve Grading System 2.0. *Otolaryngol Head Neck Surg*. 2009;140:445-50.
18. Seiff SR, Chang J. Management of ophthalmic complications of facial nerve palsy. *Otolaryngol Clin North Am*. 1992;25:669-90.
19. House JW, Brackmann DE. Facial nerve grading system. *Otolaryngol Head Neck Surg*. 1985;93:146-7.
20. Anderson P. New AAN guideline on Bell's palsy. *Medscape Medical News*. November 7, 2012. Accessed November 12, 2012.
21. Sullivan FM, Swan IR, Donnan PT, Morrison JM, Smith BH, McKinstry B, et al. Early treatment with prednisolone or acyclovir in Bell's palsy. *N Engl J Med*. 2007;357:1598-607.
22. Axelsson S, Berg T, Jonsson L, Engström M, Kanerva M, Pitkäranta A, et al. Prednisolone in Bell's palsy related to treatment start and age. *Otol Neurotol*. 2011;32:141-6.
23. Kanazawa A, Haginomori S, Takamaki A, Nonaka R, Araki M, Takenaka H. Prognosis for Bell's palsy: a comparison of diabetic and nondiabetic patients. *Acta Otolaryngol*. 2007;127:888-91.
24. Allen D, Dunn L. Aciclovir or valaciclovir for Bell's palsy (idiopathic facial paralysis). *Cochrane Database Syst Rev*. 2004;CD001869.
25. Hato N, Yamada H, Kohno H, Matsumoto S, Honda N, Gyo K, et al. Valacyclovir and prednisolone treatment for Bell's palsy: a multicenter, randomized, placebo-controlled study. *Otol Neurotol*. 2007;28:408-13.
26. Grogan PM, Gronseth GS. Practice parameter: Steroids, acyclovir, and surgery for Bell's palsy (an evidence-based review): report of the Quality Standards Subcommittee of the American Academy of Neurology. *Neurology*. 2001;56:830-6.
27. Anderson P. New AAN guideline on Bell's palsy. *Medscape Medical News*. November 7, 2012. Accessed November 12, 2012.
28. Gronseth GS, Paduga R. Evidence-based guideline update: Steroids and antivirals for Bell palsy: Report of the Guideline Development Subcommittee of the American Academy of Neurology. *Neurology*. Nov 7 2012.
29. Quant EC, Jeste SS, Muni RH, Cape AV, Bhussar MK, Peleg AY. The benefits of steroids versus steroids plus antivirals for treatment of Bell's palsy: a meta-analysis. *BMJ*. 2009;339:b3354.
30. Teixeira LJ, Valbuza JS, Prado GF. Physical therapy for Bell's palsy (idiopathic facial paralysis). *Cochrane Database Syst Rev*. Dec 7 2011;CD006283.
31. Chen N, Zhou M, He L, Zhou D, Li N. Acupuncture for Bell's palsy. *Cochrane Database Syst Rev*. Aug 4 2010;CD002914.
32. Grogan PM, Gronseth GS. Practice parameter: steroids, acyclovir, and surgery for Bell's palsy (an evidence-based review): report of the Quality Standards Subcommittee of the American Academy of Neurology. *Neurology* 2001;56:830-6. Accessed April 17, 2007, at: <http://www.aan.com/professionals/practice/pdfs/gl0064.pdf>.

Yazışma Adresi / Address for Correspondence:

Dr. Tashika Kushraj
Yenepoya University
Yenepoya Dental College
Department of Oral Medicine and Radiology
Mangalore, Karnataka, İNDİA
Email: drashikakushraj@gmail.com

Geliş tarihi/Received on: 26.09.2013

Kabul tarihi/Accepted on:21.10.2013