



Reconstruction of Injured Carotid Artery in a Comatose Patient

Komadaki Hastanın Hasarlı Karotid Arter Rekonstrüksiyonu

Arben Zenelaj¹, Rasim Madani¹, Engjellushe Shalari¹.

¹University Hospital of Trauma.Surgery Department.Tirana/ALBANIA.

Cukurova Medical Journal 2014;39(3):598-601.

ABSTRACT

A man, 30 years old, was brought to the emergency department after being injured on the left side of the neck area. Massive bleeding from the wound caused by a glass was observed. The patient was in cerebral coma and hemorrhagic shock. The eye pupils remained isochoric during and after the operation. He was taken immediately at the surgery room. The bleeding was stopped by external compression. Exposure of the left neck blood vessels was carried out .The left common carotid artery and internal jugular vein injury was revealed. A provisory Pruitt-Inahara shunt was put in the carotid artery, while the injured vein was ligatured. The suture of the left common carotid artery using Prolen 6-0 completed the procedure. After the surgery the patient was transferred to the intensive care unit. About two hours later he woke up, conscious. The left thoracic drainage because of the hemothorax was applied in the second postoperative day. The patient was lively and left the hospital in the 14 postoperative day. The right facial paresis and mild left hemiparesis persisted. Two months after the event no residual neurologic deficits were observed.

Key Words: Carotid,artery,injury,coma,patient.

ÖZET

30 yaşında erkek hastanın boyun bölgesinin sol tarafı yaralı olarak acil servise getirildi. Ağır kanamaya bir camın neden olduğu gözlemlendi. Hastada serebral koma ve hemorajik şok meydana geldi. Gözbebekleri operasyon sırası ve sonrasında izokor kaldı. Hasta acil olarak ameliyathaneye alındı. Kanama dış basıyla durduruldu. Sol boyun damarlarında gerçekleşen bu durum sol karotik arter ve internal jugular ven yaralanması olarak ortaya çıkmıştır. Karotik artere geçici Pruitt- Inahara Şantı konularak yaralı ven ligature edildi. Sol karotik arter dikişi için Prolen 6-0 kullanıldı. Operasyondan sonra hasta yoğun bakım ünitesine alındı. İki saat sonra hastanın bilinci açıldı. Operasyondan sonraki ikinci günde sol göğüs drenajı uygulandı. Hasta on dört gün sonra hastaneden taburcu edildi. Sağ yüz parazisi ve orta düzey sol hemiparazisi devam etti. Olaydan iki ay sonra hastada kalıcı hiçbir nörolojik hasar gözlenmedi.

Anahtar Kelimeler: Karotid arter, Yaralanma, Koma hastası

INTRODUCTION

Our purpose is to bring one more evidence in the treatment of the carotid artery injury, in a patient who fell in the cerebral coma.

Treatment of carotid artery injuries,particularly those associated with bleeding constitutes a major problem in emergency department.

CASE REPORT

A man, 30 years old, was brought to our emergency department about 20 minutes after receiving an injury at the left side of the neck. The wound has been externally compressed from the venue of the injury up to the hospital in order to stop the massive bleeding. The patient arrived in hemorrhagic shock and cerebral coma. The eye pupils were isochoric, and remained so during and after the operation. Under such circumstances we couldn't collect further information related to the neurologic status. He was taken immediately to the operation theatre without any kind of preliminary examination. The patient was put under general anesthesia by using Pavulon, Thiopental and tracheal intubation. We carried out a surgical exploration by using a left anterior sternocleidomastoid muscle surgical incision. The traumatic wound located at the posterior edge of the left sternocleidomastoid muscle. We left the gauzes in place at the traumatic wound and applied external compression to temporarily stop the bleeding. We controlled the common carotid artery and its bifurcation. A laceration of 2/3 of the common carotid artery circumference, about 1 cm from its bifurcation, as well as a transection of the internal jugular vein was revealed. In the first instance a Pruitt-Inahara shunt ensured the brain blood circulation from common carotid to the internal carotid artery. The ligation of the internal jugular vein stopped definitely any massive bleeding source. The injured artery was repaired

by direct suturing using Prolen 6-0. No important stenosis was observed. The wound was closed and a drain was left in place. During the operation we transfused three units of blood, infusion of two units FFP, 3000 ml NaCl 0.9 %; 500 ml Glucose 5% .We infused Mannitol 20 % to reduce brain edema was used. An additional blood unit was transfused the next day. The patient was transferred to the ICU. About 2 hours after surgery the patient became conscious and his blood pressure reached the normal values. In the third postoperative day the CT scan [Fig 1] of the head revealed left frontal-temporal-parietal ischemic area. The chest CT scan [Fig 2] revealed left hemothorax. The left thoracic drainage was therefore performed. Clinically the patient had a left facial palsy with a right side hemiparesis, which improved substantially in the following days. In the third postoperative day the tracheal tube was taken out and the patient was transferred to the ward. He started to walk, speak and eat. A brain CT scan [Fig 3] two weeks later displayed significant reduction of the ischemic area. The CT angiography [Fig 4] of the neck arteries resulted to be normal in terms of anatomic continuity and blood circulation, without any important stenosis. The patient left the hospital on the 14th postoperative day. Treatment with oral anticoagulation was continued. Two months after the operation the patient had no neurologic deficits. The brain CT [Fig 5] by that time resulted to be the same with the previous one.

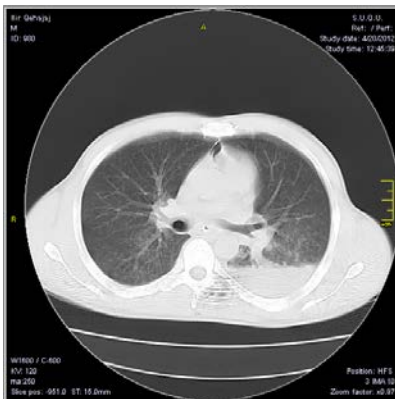
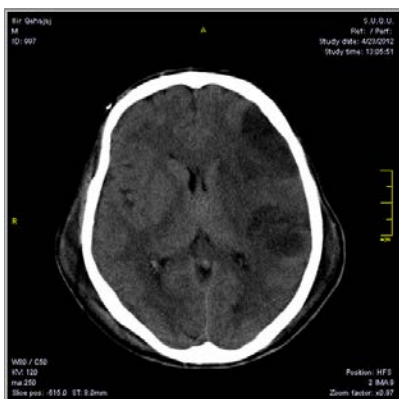


Figure 1. Brain CT third postoperative day.

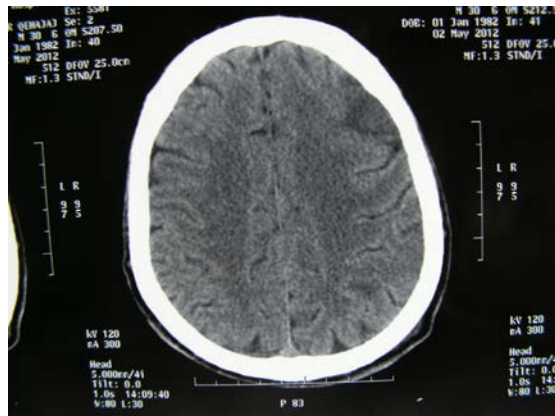


Figure 2. Chest CT with left side hemothorax.

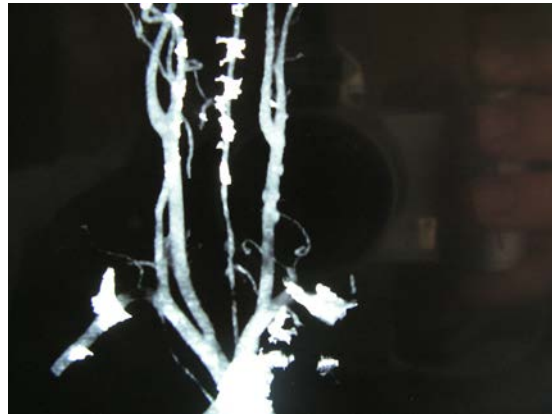

Figure 3. Brain CT two weeks latter

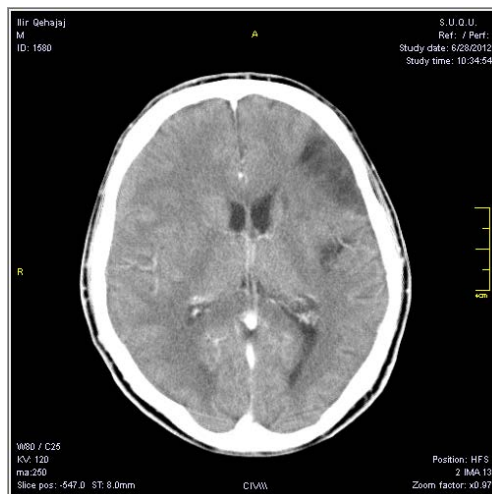


Figure 4. Neck CT angiography.

Figure 5. Brai CT two months latter.

DISCUSSION

The injury of the carotid artery is not a frequent event in our emergency department. This report can not serve as a study design, it can however serve as an additional evidence in any study related to the topic. The incidence of the common carotid artery injury was 29 %, followed by the internal carotid artery injury 15 % according to a study reported by Richardson and coworkers¹. The data collected from the literature pointed out that such situations are associated by a high mortality rate. The airway occlusion and the exsanguinating hemorrhage pose the most immediate risks to life in the patients with neck

traumas. The treatment should come along the ATLS protocol². Our case had concomitant internal jugular vein injury which caused massive bleeding. While we knew well what do to with the injured vein, the discussion focused on what to do with the injured artery. The data from the literature are controversial. Some authors recommend just the hemostasis without an artery reconstruction in the patients under cerebral coma patients caused by the carotid artery injury since neither repair, nor ligation appears to affect the poor prognosis³. Others are prone to think of repair in comatose patients and/or neurological deficits^{2,4}. In a study conducted in 36 patients⁵ the repair was

recommended in all patients who are not comatose, have stable vital signs, and have technically repairable injury. Special importance is given to the presence of prograde flow in the injured carotid artery². In fact, the brain blood circulation able to sustain the vitality of cerebral cells for a short period of time has been reported by Bonalumi F et al⁶. Based in this data and using provisory shunt during operation we reached to the decision of repairing the carotid artery. The type of repair is dependent on the mechanism of injury³. The postoperative period proved that, if immediately repaired the carotid artery, even in a cerebral coma patient, leads to better outcome not only in terms of consciousness but also in what we believe to be a faster improvement of the neurologic deficits. Of special importance were, the good temporary hemostasis during transport from where venue of the accident up to the hospital, the plan to expose the injured blood vessels, the use of temporary shunts during repair. We can not say that comma degree influences the outcome, as we were not able to make a real evaluation of the neurologic status under the conditions of massive bleeding.

CONCLUSION

Our reported case brings one more evidence that in the patients in cerebral coma due to the injured carotid artery, the repair of the artery is better than just hemostasis. The effort to reconstruct the injured artery should be done without putting into further jeopardy patient's life.

Other measures such as the provisory shunt, the attempts to reduce brain edema via drug infusion like Mannitol as well as keeping the patient under mechanical ventilation can help in faster improvement of neurological deficits.

Word account:

No conflict of interest: We assume that authors have no conflict of interest with any product mentioned at the article.

REFERENCES

1. Richardson R, Obeid FN, Richardson JD, Hoyt DB, Wisner DH, Gomez GA et al. Neurologic consequences of cerebrovascular injury Trauma. 1992;32:755-8.
2. Dar M A; Salati A S et al. Penetrating carotid artery injuries-A Cashmir experience. The internet J of Thoracic and Cardiovascular Surgery. ISSN 1524-0274. 2012;13:2.
3. Likeweg W G and Greenfield L Management of penetrating carotid arterial injury. Ann Surg. 1978;188:587-92.
4. Yasa H, Ozela A, Yetkin U et al. The internet J of thoracic and cardiovascular surgery. DOI:10-5580/2157. ISSN 1524-0274. 2008;11:2.
5. Ledgerwood A M. Primary repair vs ligation for carotid artery injuries. Arch Surg. 1980;115:488-93.
6. Bonalumi F, Carlesi R, Zaretti D. Insufficienza cerebrovascolare da patologia carotidea in Arteriopatie. Agrifoglio G, Agus B G, Gabrielli L. Masson. 1991;147-173.

Yazışma Adresi / Address for Correspondence:

Dr. Arben Zenelaj
University Hospital of Trauma Laprake,
Tirana/ALBANIA.
Email: arbenzeneli@yahoo.com

Geliş tarihi/Received on: 13.11.2013

Kabul tarihi/Accepted on: 16.12.2013