



### Adenoid Cystic Carcinoma of the Larynx

Larinksin Adenoid Kistik Karsinomu

Roopesh Sankaran<sup>1</sup>, Abdullah Sani Mohamed<sup>2</sup>

<sup>1</sup>Universiti Kebangsaan Malaysia Medical Centre Department of Orl-Hns faculty Of Medicine Medical Officer

<sup>2</sup>Senior Consultant In Laryngology Jalan Yaacob Latif bandar Tun Razak, Kuala Lumpur MALAYSIA

*Cukurova Medical Journal 2014;39(3):.611-615.*

#### ABSTRACT

This is case where a middle aged gentleman presented with history of progressively worsening hoarseness for 1 year. On further history taking and examination including imaging noted patient had supraglottic mass arising from left ventricle, measuring 2x2cm with smooth surface mimicking a benign lesion. Histopathological examination revealed as adenoid cystic carcinoma of left ventricle with perineural invasion

**Key Words:** Laryngeal ACC, minor salivary gland tumor, adenoid cystic carcinoma

#### ÖZET

Bu çalışma orta yaşlı, 1 senedir gittikçe kötüleşen ses kısıklığına sahip erkek birey ile yapılmıştır. Hastanın geçmişine ve görüntülemeyi de içeren daha önceki testlerine bakıldığında hastada supraglottik kitlenin sol ventrikülden kaynaklandığı, 2x2cm'lik düzgün yüzeyli benign bir lezyona benzediği saptanmıştır. Histopatolojik incelemede perinöral invazyonlu, sol ventrikülün adenoid kistik karsinomu saptanmıştır.

**Anahtar Kelimeler:** Laringeal ACC, minor salgı bezi tümörü, adenoid kistik karsinom

#### INTRODUCTION

Adenoid cystic carcinoma (ACC) is a malignant tumor that can occur in minor and major salivary glands. Robin and Laboulbene were the first to describe the histopathology of what they termed "tumeurs heteradentique" or "heteradentic tumors" in 1853. However, it was Billroth in 1856 who coined the term "cylindroma," which became a widely accepted term for this tumor<sup>1</sup>. Other terms which have been applied to describe this entity include basalioma, adenocarcinoma of the cylindromatous type, adenocarcinoma of the mixed type, and ACC<sup>1</sup>. The most common malignant minor salivary tumor are adenoid cystic (32-69%) followed by mucoepidermoid (15-35%)<sup>2</sup>. However the frequency of ACC in the larynx is very rare and

extremely low. Its accounts for 0.6 to 1% of laryngeal malignant tumor and only around 120 cases have been reported so far<sup>3</sup>.

ACC is characterized by an indolent growth pattern and late distant metastasis most commonly in the lungs. Due to slow growth, indolent nature and submucosal spread, ACC are difficult to detect earlier and usually patients will present with locally advanced tumor at the time of diagnosis. They tend to spread perineurally and may recur after treatment.

According to Dexemble et al, 64% of laryngeal ACC occurs in the subglottic, 25% occurs in the supraglottis, 5% occurs in the glottis and 6% occurs in the transglottis. This is possibly because the distribution density of the minor salivary glands in this area<sup>4</sup>.

### CASE REPORT

A 43 years old chinese gentleman was referred to our clinic with the history of progressively worsening hoarseness for 1 year duration. However there is no shortness of breath, dysphagia or odynophagia. No history of vocal abuse, chronic cough or contact with pulmonary tuberculosis patient. No loss of weight or appetite. He also developed noisy breathing (stridor) since 1 month prior he came to our clinic. Denies any aspiration symptoms. Patient was seen in a private hospital and was adviced regarding obtaining a biopsy but patient refuse any sort of intervention and radiographic imaging. He was then referred to our hospital.

He had background history of hypertension on single anti-hypertensive drug. Non diabetic. Non smoker or alcohol consumer. There is no family history of malignancy.

On examination patient was alert, conscious, inspiratory stridor heard. He was not in respiratory distress. Hoarseness present. No cervical lymphadenopathy. Flexible nasopharyngolaryngoscope revealed a supraglottic mass arising from left ventricle. Ear, nose and oropharynx examination was unremarkable. All the

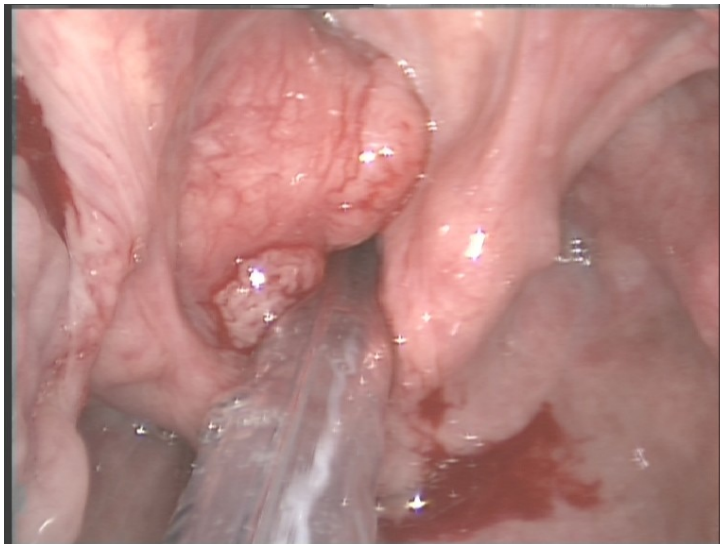
blood investigation are within normal range. His chest x-ray were normal.

Patient underwent direct laryngoscope and endolaryngeal laser surgery and intra operation findings was supraglottic mass arising from left ventricle, measuring 2x2cm with smooth surface (Figure 1) mimicking a benign lesion. Aryepiglottic fold, arythenoids and epiglottis appeared normal. No extension to glottis and subglottic. The mass was excised and the specimen was sent for histopatological Examination (HPE).

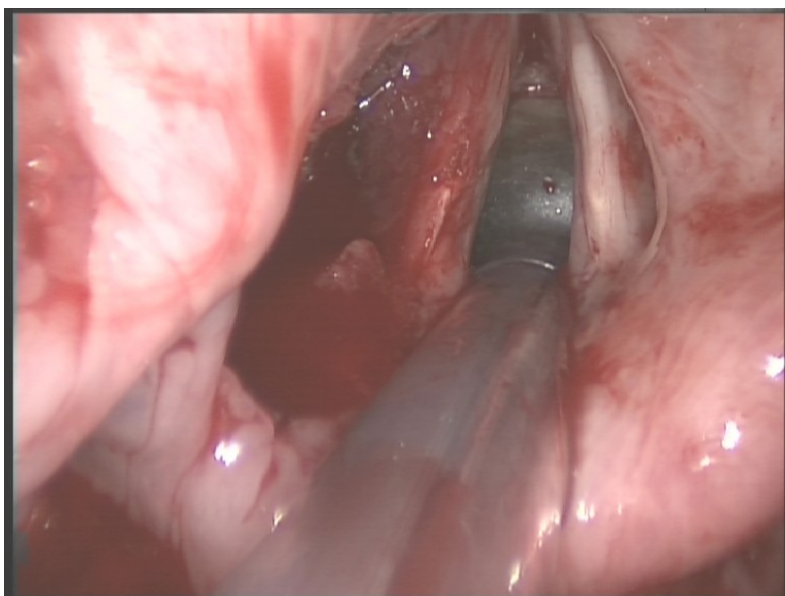
HPE was reported as adenoid cystic carcinoma of left ventricle with perineural invasion. The tumor has predominantly cribriform pattern formed by nest of basaloid small tumor cells.

We diagnosed him as adenoid cystic carcinoma of left ventricle with perineural invasion. Patient currently undergoing radiotherapy after wide excision of mass which was done during direct laryngoscope.

Post operative computerized tomography scan (CT Scan) was done and reported as there is a mass (1.0cm x 1.6cm x1.4cm ) anterosuperiorly to the arythenoids and cricoid cartilage, anterior to laryngopharynx. Inferiorly its not involving vocal cords and anterior commissure. No distal metastasis seen.



**Figure 1.** Supraglottic mass arising from left ventricle, measuring 2x2cm with smooth surface



**Figure 2.** Post removal of the supraglottis mass with laser

## DISCUSSION

Adenoid cystic carcinoma (ACC) is a relatively common salivary gland malignancy in the head and neck region however, its presence in the airway is rare. In the larynx it arises from mixed seromucinous glands and constitute less than 1% of all laryngeal tumor. ACC usually occurs as a asymptomatic, nonulcerated submucosal mass which usually cause diagnosis late and give opportunity to the mass to invade deeply before there are disagnosed.

A wide age range has been reported for adenoid cystic carcinoma, including cases in the pediatric age group. Most individuals are diagnosed with the disease in the fourth through sixth decades of life. There is a slight female preponderance (female to male ratio approximately 3 to 2). The cause of ACC is unknown at this time, and risk factors for this type of cancer have not been proven consistently with scientific research. There is some evidence that the *p53* tumor suppressor gene (a gene that limits cell growth by monitoring the rate at which cells divide) is somehow inactivated in advanced and aggressive forms of ACC<sup>6</sup>.

The presenting symptoms patients with ACC is related to location and size of tumor. A supraglottic ACC patient usually present with dysphagia. Hoarseness and dyspnoea is indicative of glottis involvement as in our patient. Meanwhile tumor at subglottis will present with stridor or airway obstruction. There is a reported case by E.zvrko et al shows prelaryngeal pain was the only symptom in a patient with advanced ACC of larynx<sup>4</sup>. Other symptom that reported in literatures are neck mass, hemoptysis, cough, ear pain and weight loss. In our patient the presenting symptoms was progressively worsening hoarseness and stridor.

The diagnosis of ACC is done by obtaining a histopatological analysis of a biopsy or resected specimen of a tumor mass. The most widely accepted histological grading system for ACC according to Szanto et al is Grade I, tumors with tubular and cribriform areas but without solid components; Grade II, cribriform tumors that were either pure or mixed with less than 30% of solid areas; and Grade III, tumors with a predominantly (more than 30%) solid pattern<sup>7</sup>. The former has

good prognosis and the latter has worse prognosis. In our case it was grade II tumor.

A well planned pre-operative assessment are essential for patients with laryngeal ACC. Obtaining a histopathological analysis is mandatory. CT Scan imaging is useful in the assessment of primary tumor location, extra luminal extension, regional and distant metastasis. It also can be obtained post-operatively as a tool for follow up as patients require long term follow up since local recurrence and distant metastasis are common and can arise years after primary tumors has been diagnosed and treated.

Compared with most other carcinomas, ACC has a slow course with a survival rate of 89 percent at five years. Tumors progress persistently and often recur, resulting in a survival rate of only 40 percent after 15 years.<sup>6</sup> Remote metastases can occur a decade or more after initial treatment of the primary tumor, with the most common metastatic locations being the lung is by far the most common site of metastasis, with the liver being the second most common site. Bone metastases usually indicate a fulminant clinical course. Another unusual feature of ACC is that, unlike most carcinomas, it seldom metastasizes to regional lymph nodes. The most important prognostic factors that need to be taken into account are clinical stage of the lesion, localization, histological pattern, vascular and perineural invasion, positive surgical borders, duration of symptoms, recurrent tumor and metastatic disease.

The optimal therapy for ACC of the head and neck has not been established. The choice of therapy is affected by site, stage, histologic grade, and biologic behavior of the ACC<sup>5</sup>. Surgical resection, whenever possible, is the mainstay therapy. Based on clinical experience, many centers advocate postoperative radiotherapy to help limit local failure. A few specialized centers offer neutron beam therapy which may be more effective than conventional radiation therapy. There appears to be no effective chemotherapy for

metastatic and/or unresectable ACC, although some patients may receive palliation. In the absence of neck metastasis, elective neck dissection is unnecessary. Radical neck dissection is indicated for patients who have clinically or histologically confirmed nodal metastases<sup>3</sup>. In our case patient currently undergoing radiotherapy for the residual mass seen in post operative CT Scan after wide excision of mass.

### CONCLUSION

Although ACC of larynx is rare, a high degree of suspicion is essential if a benign looking mass is seen in an elderly patients. These patients may not have the typical constitutional symptoms of a malignant cancer.

HPE is mandatory and CT Scan pre or post operation is essential to see the extend of tumor or to identify residual mass post operatively.

Long term follow up is essential because of the possibility of late recurrence and metastasis.

### REFERENCES

1. Moukarbel RV, Goldstein DP, O'Sullivan B, Gullane PJ, Brown DH, Wang L, et al.: Adenoid cystic carcinoma of the larynx: a 40-year experience. *Head Neck*. 2008;30:919-24.
2. Ganly I, Patel SG, Coleman M, Ghossein R, Carlson D, Shah JP. Malignant minor salivary gland tumors of the larynx. *Arch Otolaryngol Head Neck Surg*. 2006;132:767-70.
3. Negro AD, Ichihara E, Tincani AJ, Altemani A, Martins AS. Laryngeal Adenoid Cystic Carcinoma: Case Report. *Sao Paulo Med J*. 2007;125:295-6
4. Zvrko E, Golubovic M. Laryngeal adenoid cystic carcinoma. *ACTA otorhinolaryngologica italic*. 2009;29:279-82
5. Bradley PJ . Adenoid cystic carcinoma of the head and neck: a review. *Curr Opin Otolaryngol Head Neck Surgery*. 2004;12:127-32.
6. Oncologist approved cancer information from the American Society of Clinical Oncology. <http://www.cancer.net/cancer-types/adenoid-cystic-carcinoma>.

7. Szanto PA, Luna MA, Tortoledo E, et al. Histologic grading of adenoid cystic carcinoma of the salivary glands Cancer. 1984;54:1062-9.
8. Wang MC, Liu CY, Li WY, Chang SY, Chu PY. Salivary gland carcinoma of the larynx. J Chin Med Assoc. 2006;69:322-5.
9. Calzada AP, Miller M, Lai CK , Elashoff DA, Abemayor E, St. John MA . Adenoid cystic carcinoma of the airway: a 30-year review at one institution. American Journal of Otolaryngology- Head and Neck Medicine and surgery. 2012;33:226-31
10. Escobar-Alfaro G, Luna-Ortiz K, Granados-García M, Godoy-Rivera LM, Ortega-Gutiérrez N, Barerra-Franco JL. Adenoid cystic carcinoma of the larynx: a case report and review of the literature. Revista de Oncología. 2002;4:399-401.

**Yazışma Adresi / Address for Correspondence:**

Dr. Roopesh Sankaran  
Universiti Kebangsaan Malaysia Medical Centre  
Department of Orl-Hns faculty Of Medicine  
Medical Officer  
Jalan Yaacob Latif bandar Tun Razak, Kuala Lumpur  
MALAYSIA  
Email: roop2606@yahoo.com

Geliş tarihi/Received on: 30.09.2013

Kabul tarihi/Accepted on:16.12.2013