



### Acute Necrotizing Encephalopathy of Childhood: A Turkish Case

Çocukluk Çağının Akut Nekrotizan Ensefalopatisi: Türkiye'den Bir Olgu

Olca Ünver<sup>1</sup>, Zehra Işık Hasıloğlu<sup>2</sup>, Sezgin Şahin<sup>3</sup>, Mehmet Sait Albayram<sup>2</sup>, Yücel Taştan<sup>3</sup>, Serap Uysal<sup>1</sup>

<sup>1</sup>Istanbul University Cerrahpaşa Medical School Department of Pediatric Neurology, <sup>2</sup>Department of Radiology, <sup>3</sup>Department of Pediatrics, İSTANBUL

*Cukurova Medical Journal 2014; 39 (3):641-645.*

#### ABSTRACT

Acute necrotizing encephalopathy of childhood is a rare form of acute encephalopathy of unknown etiology characterized by typical symmetrical lesions in the thalami, with variable involvement of the white matter, brainstem and cerebellum. Clinically there is a rapid neurologic deterioration after a short period of a nonspecific viral-like illness associated with gastrointestinal or respiratory signs. Asian children are especially affected. Here we present a 3-year-old boy admitted to our hospital with fever and deterioration of consciousness. His nasopharyngeal swab for polymerase chain reaction revealed positive results for human parainfluenza 2 virüs. The diagnosis of acute necrotizing encephalopathy was made by cranial magnetic resonance imaging findings with symmetrical expansile hyperintense signals in bilateral thalami.

**Key Words:** Acute necrotizing encephalopathy, children, parainfluenza virus.

#### ÖZET

Çocukluk çağının akut nekrotizan ensefalopatisi, talamusta tipik, simetrik lezyonlar ve ak madde, beyin sapı ve serebellumun değişik tutulumu ile nitelenen, etiyojisi bilinmeyen, nadir bir akut ensefalittir. Klinikte, gastrointestinal veya solunum sistemini etkileyen nonspesifik viral enfeksiyonlar sonrasında hızlı nörolojik bozulma izlenir. Asya kökenli çocuklarda daha sık görülür. Üç yaşında bir erkek olgu bilinç bulanıklığı, ve ateş nedeniyle hastanemize başvurdu. Nazofarenks sürüntüsünde polimeraz zincir reaksiyonu ile insan parainfluenza virüs tip 2 saptandı. Beyin manyetik rezonans incelemesinde bilateral talamusta simetrik yayılan hiperintensiteler saptanan hastaya akut nekrotizan ensefalopati tanısı kondu.

**Anahtar Kelimeler:** Akut nekrotizan ensefalopati, çocukluk çağı, parainfluenza virüsü

#### INTRODUCTION

Acute necrotizing encephalopathy of childhood (ANEC) is a novel form of acute encephalopathy firstly described by Mizuguchi et al in East Asia in 1995<sup>1</sup>. The disease is characterized by a rapid neurologic dysfunction such as impairment of consciousness and seizures

following a nonspecific febrile viral illness with gastrointestinal or respiratory signs<sup>2,3</sup>. Multifocal,

symmetric brain lesions involving the thalami, brainstem, cerebellum, and white matter are the hallmarks of the disease<sup>4,5</sup>. This rare entity of encephalopathy mainly affects oriental children living in the Far East<sup>6</sup>. The course of the disease is variable, with a mortality rate of up to 30 %. Death

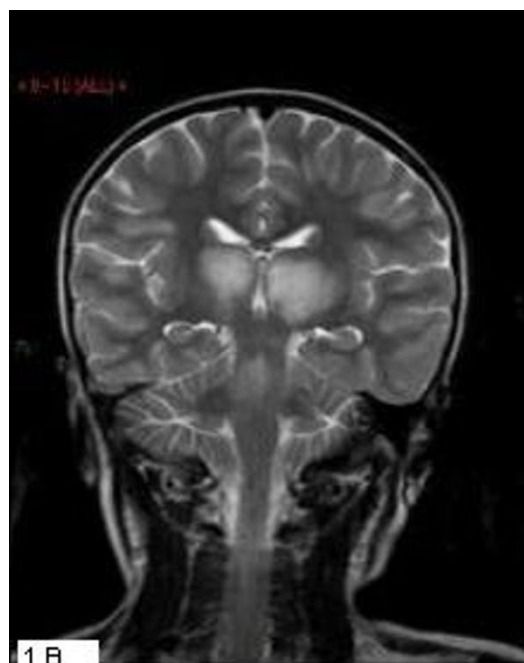
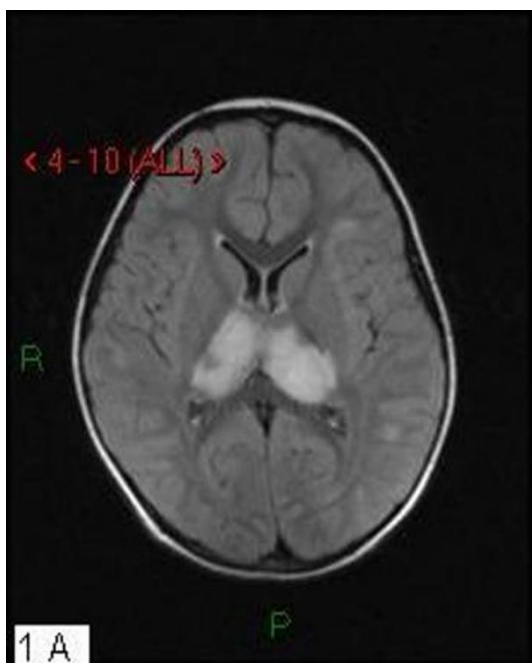
frequently occurs within a few days after onset. Less than 10 % of patients fully recover<sup>7</sup>.

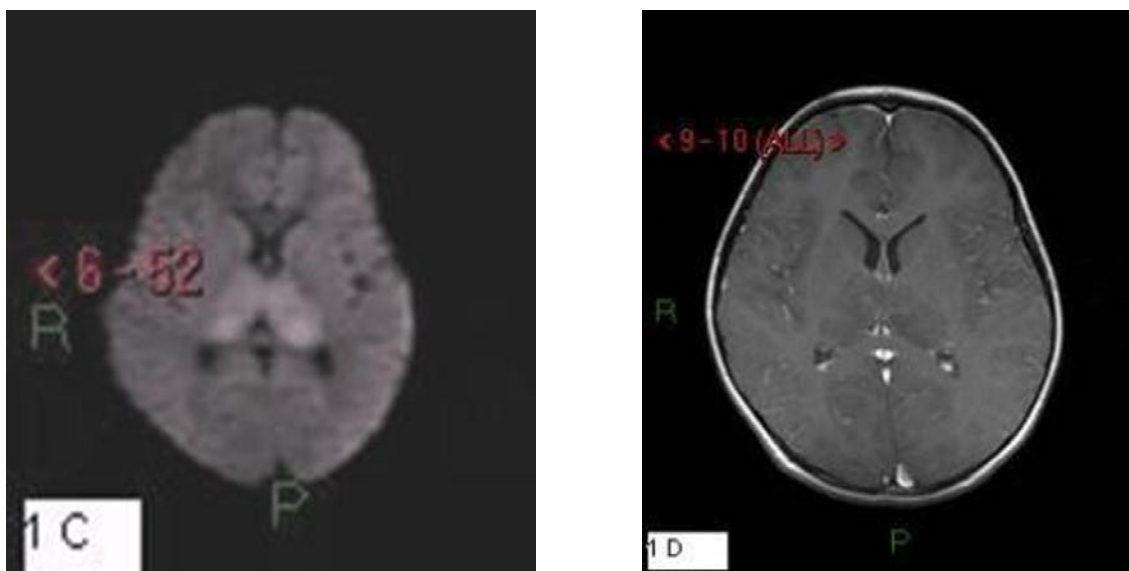
**CASE REPORT**

A 3-year-old boy was admitted to our hospital with fever and cloudy consciousness. His temperature was 38,1 C. On neurological examination he was unresponsive to verbal stimuli, he localised to pain. His glasgow coma score was 7. There were no other abnormal neurological signs. On laboratory examination his white blood cell count was 17300 mm<sup>3</sup> (60 % pnl), hemoglobin 12.9 g/dl and platelets 436.000/mm<sup>3</sup>. His sedimentation rate was 47 mm/hour (0-20) and C reactive protein was 12.6 mg/dl (0-5). His liver and kidney function tests were normal. A lumbar puncture was performed with the diagnosis of encephalitis. Cerebrospinal fluid opening pressure was normal and 10 cells/mm<sup>3</sup> were found (mainly lymphocytes) and cerebrospinal fluid (CSF) protein and sugar were 38.9 mg/dl (15-45), 54 mg/dl

(blood sugar 86 mg/dl) respectively. Antibiotic and antiviral therapy was started with ceftriaxon and

acyclovir. The electroencephalography (EEG) showed generalized slowing of background activity. A virus isolation from CSF and blood revealed negative results. Blood and CSF cultures were sterile. His nasopharyngeal swab for polymerase chain reaction (PCR) revealed positive results for human parainfluenza 2 virüs. The diagnosis of ANEC was made by cranial magnetic resonance imaging findings with symmetrical expansile hyperintense signals in bilateral thalami (Figure 1). Intravenous Human immunoglobulin therapy was started. He improved clinically, became responsive to verbal stimuli, he could walk but his gait was ataxic. Enteral feeding was continued due to swallowing dysfunction. He was discharged with neurologic sequela. However, at the third month of the discharge his neurologic examination was almost normal except for slight tremor.





**Figure 1.** Axial FLAIR (A) and coronal T2 weighted (B) images showing symmetrical expansile hyperintense signals in bilateral thalami. Diffusion restriction in the same localizations in diffusion weighted images (C). There is no marked contrast enhancement in T1 images in these localizations (D).

## DISCUSSION

Acute necrotizing encephalopathy of childhood is a rare form of acute encephalopathy of unknown etiology with a devastating course mainly affecting Asian children. The incidence of the disease is unknown; however, more than 240 cases have been recorded from Asia, 5 from North America and, 10 from Europe<sup>8,9</sup>. The explanation for this racial predilection is not clear, and genetic and epigenetic factors pertinent to these countries have been suggested (1,10). During H1N1 outbreak case reports were published<sup>1,12,13</sup>. Close to 30 % of cases evolve toward death, especially in patients <2 years of age, those with high serum aspartate aminotransferase values, and those with brainstem lesions<sup>10</sup>.

The disease is always associated with viral infections mostly caused by Influenza A, B and exanthema subitum. Other related pathogens are human herpesvirus 6, mycoplasma, Coxsackie A, rotavirus, and measles viruses<sup>10</sup>. To our knowledge the first case of ANEC with parainfluenza virus infection was reported in 2003 with a relatively benign course as in the present case<sup>6</sup>.

The criteria for the diagnosis of ANEC established by Mizuguchi in 1997 are acute encephalopathy with rapid conscious deterioration, absence of serum hyperammonemia and CSF pleocytosis, increase in CSF proteins, neuroimaging studies showing symmetrical, multifocal lesions involving the thalami, and the clinical absence of other diseases resembling ANEC such as hypoxia, prolonged hypotension, hemolytic-uremic syndrome, severe head injury, intoxication, metabolic diseases or neurodegenerative disorders<sup>10</sup>.

As in the present case the clinical course is characterized by acute onset of mental status changes accompanied by seizures in 40 % of cases, most often within the first 24 to 48 h of a nonspecific viral infection. An increase in CSF protein of variable degree has been noted in many patients with ANEC, yet a CSF pleocytosis is usually not present<sup>1,10</sup>. Analyses of cerebrospinal fluid of the present case failed to reveal pleocytosis or high antibody titers, and the laboratory evaluation was unrevealing for infectious agents although parainfluenza 2 virus was detected in a

nasopharyngeal swab. The CSF protein was normal but this may be explained by the time of the procedure at the onset of the symptoms when the brain damage is not fully established. The neuroimaging findings are the hallmarks of the disease with bilateral multifocal, symmetric lesions involving the thalami, brainstem, tegmentum, supratentorial white matter, and cerebellum. Thalamic involvement is presumably present in all cases although other areas mentioned above may variably be involved<sup>8,14</sup>. The neuroimaging of the present case was consistent with ANEC.

The pathophysiology of ANEC has not been fully understood yet. In the few postmortem studies published to date some authors have found evidence of petechial hemorrhages, congestion of intraparenchymal thalamic vessels, microthrombi, and vasogenic edema, suggesting that CNS dysfunction may result from vascular damage without evidence of direct penetration across the blood brain barrier<sup>15</sup>. Other authors describe high plasma concentrations of interleukin 6 and tumor necrosis factor- $\alpha$ , suggesting that proinflammatory cytokines may be mediators of damage<sup>16</sup>.

A local breakdown of the blood-brain barrier and an immunogenetic mechanism rather than direct invasion of the virus were suggested in the pathogenesis of acute necrotizing encephalopathy of childhood<sup>7,10,17</sup>. This may explain the lack of CSF pleocytosis and increase in CSF protein.

The mortality and morbidity of the disease is high and death frequently occurs within a few days after the onset. Less than 10 % of patients fully recover. Irreversible neurologic sequelae are frequent in those who survive<sup>7,17</sup>. But milder forms of the disease with a better outcome as the present case have also been reported<sup>11,18,19</sup>. Regarding the outcome in patients, younger than 2 years of age, those with high serum aminotransferase level, high protein levels of cerebrospinal fluid, and those with brain stem lesions are thought to be poor prognostic factors<sup>2,7,12,20</sup>. The normal transaminase and CSF protein levels and lack of brain stem involvement in

the neuroimaging findings of the present case were consistent with the good prognostic factors of the disease.

There is no known specific treatment for ANEC. The only available therapy is supportive. Use of antiviral agents, immune modulating therapies such as methylprednisolone pulses, high-dose  $\gamma$ -globulin or plasmapheresis have been tried. These interventions seem to decline mortality from 30 % to 15 % in Japan<sup>21</sup>. We also tried high dose  $\gamma$ -globulin with 2 g/kg in the present case.

In conclusion, we presented a case of ANEC, a rare form of encephalopathy with a poor prognosis mostly caused by influenza virus infection and characterized by bilateral symmetric lesions in the thalami, with variable involvement of the white matter, brainstem and cerebellum. Although seen very rarely in western countries, a rapid change in mental status in a child after a nonspecific viral infection should raise the suspicion of ANEC and neuroimaging findings should be obtained. When the diagnosis is made precisely early intervention with antiviral therapy and immune modulating therapies may be life saving.

This case was presented as a poster at the 9<sup>th</sup> congress of the European pediatric Neurology Society in Cavtat Croatia May 10-14 2011.

## REFERENCES

1. Mizuguchi M, Abe J, Mikkaichi K, Noma S, Yoshida K, Yamanaka T, Kamoshita S. Acute necrotizing encephalopathy of childhood: a new syndrome presenting with multifocal, symmetric brain lesions. *Journal of Neurology, Neurosurgery, and Psychiatry*. 1995;58:555-61.
2. San Milan B, Teijeira S, Penin C, Garcia JL, Navarro C. Acute necrotizing encephalopathy of childhood: report of a Spanish case. *Pediatr Neurol*. 2007;37:438-41.
3. Güzel A, Karasalihoğlu S, Ünlü E, Küçükuğurluoğlu Y, Bulut H. Akut nekrotizan ensefalopati. *Türkiye Klinikleri J Pediatr*. 2012;21:40-4.

4. Skelton BW, Hollingshead MC, Sledd AT, Phillips D, Castillo M. Acute necrotizing encephalopathy of childhood: typical findings in an atypical disease. *Pediatr Radiol.* 2008;38:810-13.
5. Albayram S, Bilgi Z, Selcuk H, et al. Diffusion-weighted MR imaging findings of acute necrotizing encephalopathy. *AJNR.* 2004;25:792-7.
6. Mastroianni SD, Voudris KA, Katsarou E et al. Acute necrotizing encephalopathy associated with parainfluenza virus in a caucasian child: *J Child Neurol.* 2003;18:570-2.
7. Ohsaka M, Houkin K, Takigami M, Koyanagi I. Acute necrotizing encephalopathy associated with human herpesvirus-6 infection. *Pediatr Neurol.* 2006;34:160-3.
8. Mastroianni SD, Giannis D, Voudris K, Skardoutsou A, Mizuguchi M. Acute necrotizing encephalopathy of childhood in non-Asian patients: report of three cases and literature review. *J Child Neurol.* 2006;21:872-79.
9. Marco EJ, Anderson JE, Neilson DE, Jonathan B, Strober JB. Acute necrotizing encephalopathy in 3 brothers. *Pediatrics.* 2010;125:693-98.
10. Mizuguchi M. Acute necrotizing encephalopathy of childhood: a novel form of acute encephalopathy prevalent in Japan and Taiwan. *Brain & Development.* 1997;19:81-92.
11. Munakata M, Kato R, Yokoyama H, et al. Combined therapy with hypothermia and anticytokine agents in influenza A encephalopathy. *Brain Dev.* 2000;22:373-7.
12. Martin A, Reade EP. Acute necrotizing encephalopathy progressing to brain death in a pediatric patient with novel influenza A (H1N1) infection. *Clinical Infectious Diseases.* 2010;50:50-2.
13. K m r M, Okuyaz  , Arslankoylu AE, Kara E, Atici A. Acute necrotizing encephalopathy associated with novel influenza A (H1N1) virus in Turkey. *J Pak Med Assoc.* 2011;61:1237-9.
14. Wong A, Simone E, Zimmerman R et al. Acute necrotizing encephalopathy of childhood: correlation of MR findings and clinical outcome. *AJNR Am J Neuroradiol.* 2006;27:1919-23.
15. Sugaya N. Influenza-associated encephalopathy in Japan. *Semin Pediatr Infect Dis.* 2002;13:79-84.
16. Vilensky JA, Foley P, Gilman S. Children and encephalitis lethargica: a historical review. *Pediatr Neurol.* 2007;37:79-84.
17. Maladrini A, Luchini D, Gambelli S, et al. A syndrome of bilateral hemorrhage of the thalamus and myocarditis with fatal course. *J Clin Forensic Med.* 2004;11:208-10.
18. Voudris KA, Skardoutsou A, Haronitis I, et al: Brain MRI findings in influenza A-associated acute necrotizing encephalopathy of childhood. *Eur J Paediatr Neurol.* 2001;5:199-202.
19. Tran TD, Kubota M, Takeshita K, et al: Varicella-associated acute necrotizing encephalopathy with a good prognosis. *Brain Dev.* 2001;23:54-7.
20. Olgar S, Ertugrul T, Nisli K, Aydin K, Caliskan M. Influenza A associated acute necrotizing encephalopathy. *Neuropediatrics.* 2006;37:166-8.
21. Morishima T. Treatment of influenza associated encephalopathy [in Japanese]. *Nippon Rinsho.* 2003;61:2006-12.

#### Yazışma Adresi / Address for Correspondence:

Dr. Olcay  nver  
 İstanbul University Cerrahpaşa Medical Scholl  
 Department of Pediatric Neurology  
 Tel: 0216 3910680  
 Fax: 0216 3910699  
 Email: olcaymd@hotmail.com.

Geliş tarihi/Received on:15.11.2013

Kabul tarihi/Accepted on:26.12.2013