



### A Rare Cause of Small Intestinal Obstruction: Obturator Hernia

İnce Barsak Tıkanıklığının Nadir Bir Sebebi: Obturator Herni

Erdal Karagulle<sup>1</sup>, Emin Türk<sup>1</sup>, Hakan Yabanoğlu<sup>1</sup>

<sup>1</sup>Baskent University Faculty of Medicine, Department of General Surgery, ANKARA

*Cukurova Medical Journal 2014; 39 (3):654-657.*

#### ABSTRACT

Obturator hernia is an uncommon disease and its diagnosis is challenging. It is more prevalent in thin, multiparous, elderly women. In this case report a 93-year-old woman patient with a right-sided strangulated obturator hernia was discussed with review of the relevant literature.

**Key Words:** Obturator hernia; Small bowel obstruction; Computed tomography

#### ÖZET

Obturator fıtık nadir bir hastalıktır ve tanısı zordur. Zayıf, multipar, yaşlı kadınlarda daha sık görülür. Bu olgu sunumunda sağ taraflı strangüle obturator hernisi olan 93 yaşındaki kadın hasta literatür bilgisi ile gözden geçirilerek tartışıldı.

**Anahtar Kelimeler:** Obturator herni; İnce Barsak tıkanıklığı; Bilgisayarlı tomografi

#### INTRODUCTION

Obturator hernia is a type of pelvic hernia in which a bowel segment protrudes through the obturator foramen adjacent to the obturator vessels and nerve. It occurs more frequently in patients with ascites, chronic constipation, and chronic obstructive pulmonary disease and in thin, elderly multiparous women (at seventh or eighth decades)<sup>1</sup>. It can cause significant morbidity and mortality, especially in the elderly<sup>2</sup>. Obturator hernia is a rare entity, accounting for 0.05% to 0.14% of all hernias<sup>3</sup>. Its incidence is estimated to be <1% worldwide and 1.6% in Asian populations<sup>3</sup>. Majority of patients (nearly 90%) present with intestinal obstruction despite absence of a previous operation<sup>4</sup>. A pubmed search using the keyword "obturator hernia" revealed 529 articles, the majority of which were case reports. In this case report a patient who was admitted with signs

of intestinal obstruction and diagnosed with strangulated obturator hernia was presented with review of the relevant literature.

#### CASE REPORT

A 93-year-old female patient presented with right hip and knee pain for 6 months. She was operated with open reduction and internal fixation for right femoral subtrochanteric fracture following a blunt trauma in 2007. Assuming that her pain was due to implant screws, the department of orthopedics removed the screws under local anesthesia. After the operation the patient had nausea and vomiting, abdominal bloating, and inability to defecate or pass gas for 3 months, which worsened progressively for the last 15 days. She had no systemic disease or pregnancy. Her height was 155 cm and weight was 40 kg (BMI

16.6 kg/m<sup>2</sup>). On physical examination skin turgor and tonus were diminished and she had abdominal distention, diffuse abdominal tenderness, and rebound tenderness. The intestinal sounds were metallic in character. In rectal examination rectum was empty and there was no mass. Plain abdominal radiography revealed dilated loops in the small intestines and gas fluid levels. Her oral intake was stopped; a nasogastric tube and a Foley catheter were inserted. A rectal tube was placed but no defecation occurred. Her laboratory results were as follows: Urea 47 mg/dL (normal range 6-21 mg/dL), creatinine 1.54 mg/dL (normal range 0.5-1.3 mg/dL), leucocyte 13.6×10<sup>3</sup>/mm<sup>3</sup> (normal range 4.5-11×10<sup>3</sup>/mm<sup>3</sup>), and C-reactive protein 56 mg/L (normal range 0-10 mg/L). A computerized tomography (CT) of whole abdomen was obtained despite ongoing impairment of renal function after consulting the nephrology department. Abdominal CT revealed herniation of small intestine into the obturator canal. In addition, intestinal loops proximal to the herniated region were dilated and showed air-fluid levels (figure 1). A free fluid collection was detected in the abdominal cavity. There was also bilateral pleural effusion that was more prominent on the left side. A pleurocan catheter was placed for pleural effusion. After consulting with the anesthesiologists and discussion with patient relatives a decision was made to proceed with surgery despite its risks. The abdominal cavity was entered via a subumbilical midline incision. A right-sided strangulated obturator hernia was observed (figure 2). The necrotic ileal loop in that region was resected and an end to end anastomosis was made. Then, the peritoneal layer over the obturator canal was opened and a propylene mesh was inserted as a plaque into the canal and it was stabilized. The peritoneal layer was closed. The patient was discharged 10 days later after an uneventful hospital stay. The patient is now at third month after the operation and has no problems.

## DISCUSSION

Obturator hernia, also called “the skinny old lady hernia,” is an uncommon hernia usually occurring in elderly women, which usually presents with intestinal obstruction<sup>4</sup>. It is six times more common in women due to the wider and more obliquely inclined female pelvis, the larger transverse diameter of the obturator foramen, and pregnancies<sup>4</sup>. Right-side obturator hernia is more common<sup>4</sup>, possibly because of the sigmoid colon lying in front of the obturator foramen on the left side.

Clinical findings include intermittent abdominal pain and repeated episodes of bowel obstruction that resolve without intervention<sup>3</sup>. Its diagnosis is often delayed or missed, which results in high rates (25-100%) of bowel strangulation<sup>3</sup>. The mortality from complicated obturator hernia has been reported 12% to 70%<sup>3,5</sup>. Our case was an elderly female patient with a low body mass index. In addition, she had right-sided obturator hernia and associated intestinal strangulation. Half of patients suffering from an obturator hernia have the Howship-Romberg sign, which indicates pain along the medial aspect of the thigh to the knee due to compression of the anterior branch of the obturator nerve by the contents of the hernia<sup>6,7</sup>. However, this sign is commonly mistaken for neuromuscular pain since joint pain is common in elderly patients and is overlooked. Another clinical sign of obturator hernia is the Hannington-Kiff sign, in which the adductor reflex is absent in the thigh. Our patient has right hip and knee pain for 6 months. It was considered that the pain might have been secondary to the internal fixation screws previously implanted for a fracture and thus the screws were explanted. These findings were not paid attention to during examination of the patient who was recently operated.

Due to its nonspecific symptoms, obturator hernia is difficult to diagnose. The preoperative diagnosis rate has been reported only 10-30%<sup>1</sup>.

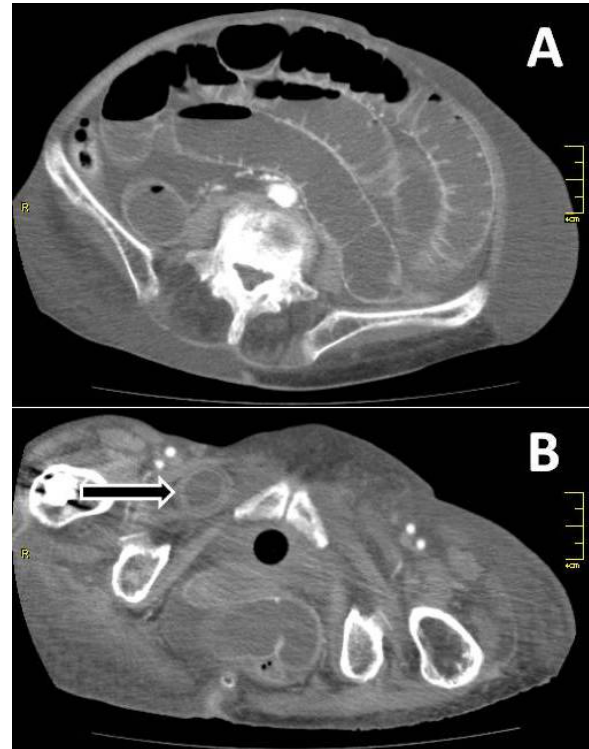Most patients undergo surgery because of an intestinal obstruction and are diagnosed during the operation. As our patient, more than 90% of patients with obturator hernia are admitted to the hospital with acute intestinal obstruction presenting with abdominal pain, nausea, and vomiting<sup>1</sup>. A mass in the obturator area may be detected on rectal or vaginal examination [2,8], although our case did not reveal any abnormality on examination.

Various imaging modalities can be used to establish the diagnosis of obturator hernia. Plain abdominal radiographs can show signs of bowel obstruction such as dilatation of small bowel loops and air fluid levels, or even a gas shadow in the area of obturator foramen<sup>5,8</sup>. A preoperative diagnosis can be made with diagnostic imaging methods, such as ultrasonography and CT. The latter has a high sensitivity and specificity<sup>1</sup>. Therefore, CT scan should be performed routinely in patients suspected to have obturator hernia. Our case was diagnosed with CT. Obturator hernia is often surgically treated by midline or inguinal laparotomy, but laparoscopic surgery has recently been introduced for its management in some institutions. Along with primary repair, mesh repair has recently become a major option. In our patient obturator hernia defect was repaired with a propylene mesh.

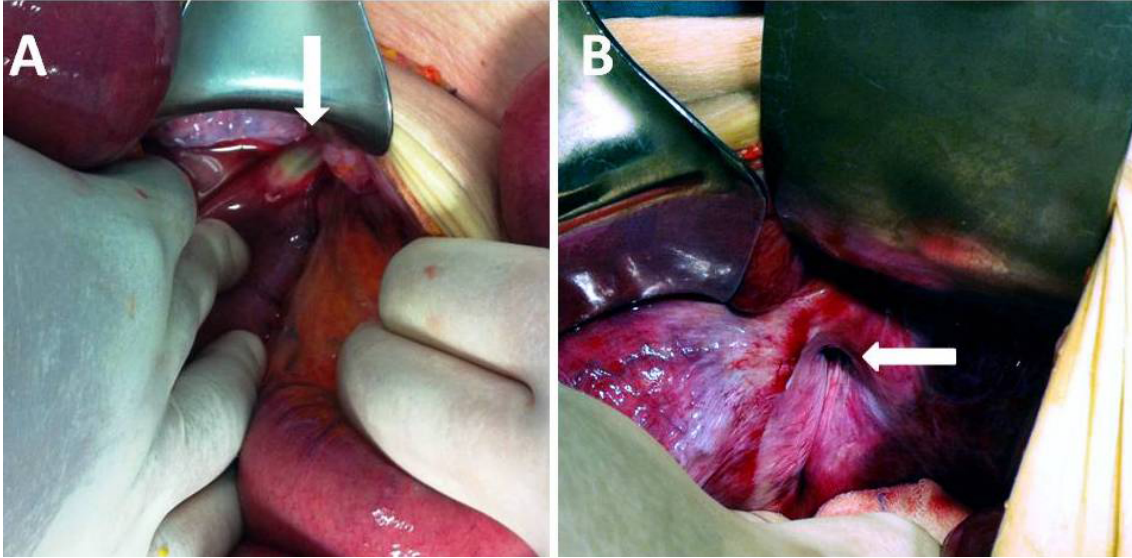
In conclusion, obturator hernia should be considered in the differential diagnosis of thin, multiparous, elderly patients, especially females,

presenting with symptoms of intestinal obstruction. Computed tomography should be used for diagnosis because of its high sensitivity.

Conflict of interest and source of funding statement: The authors declare that they have no competing interests and no funding statement.



**Figure 1.** Abdominal tomography with contrast showed dilatation of intestinal loops with air-fluid levels, which were consistent with the diagnosis of ileus (A); the view of the small intestinal region that was incarcerated into the right obturator canal (B) (black arrow).



**Figure 2.** The view of the ileal loop that herniated into the right obturator foramen and subsequently necrosed (A) (white arrow). The view of the dilated right obturator foramen (B) (white arrow).

## REFERENCES

1. Aydin I, Yucel AF, Pergel A, Sahin DA. Obturator hernia: a rare case of acute mechanical intestinal obstruction. *Case Rep Surg.* 2013;2013:256062. DOI: 10.1155/2013/256062.
2. Mandary MT, Zeng SB, Wei ZQ, Zhang C, Wang ZW. Obturator hernia--a condition seldom thought of and hence seldom sought. *Int J Colorectal Dis.* 2012;27:133-41. DOI: 10.1007/s00384-011-1289-2.
3. Chan PK, Ng TP, Lam YL. Obturator hernia presenting as hip pain: a case report. *J Orthop Surg (Hong Kong).* 2012;20:398-401.
4. Ng DC, Tung KL, Tang CN, Li MK. Fifteen-year experience in managing obturator hernia: from open to laparoscopic approach. *Hernia.* 2013. [Epub ahead of print]
5. Chang SS, Shan YS, Lin YJ, Tai YS, Lin PW. A review of obturator hernia and a proposed algorithm for its diagnosis and treatment. *World J Surg.* 2005;29:450-4.
6. Kammori M, Mafune K, Hirashima T, Kawahara M, Hashimoto M, Ogawa T, et al. Forty-three cases of obturator hernia. *Am J Surg.* 2004;187:549-52.
7. Sorabella RA, Miniati DN, Brandt ML. Laparoscopic obturator hernia repair in an adolescent. *J Pediatr Surg.* 2005;40:39-41.
8. Leow JJ, How KY, Goh MH, Woon WW, Low JK. Non-operative management of obturator hernia in an elderly female. *Hernia.* 2013. [Epub ahead of print]

## Yazışma Adresi / Address for Correspondence:

Dr. Erdal Karagülle  
Baskent Universitesi Konya Hastanesi  
Hocacihan mah. Saray caddesi No:1  
Selcuklu / KONYA  
Tel: +900332 257 0606  
Fax: +900332 257 0637  
E-mail: erenka2000@hotmail.com ,  
erdalk@mail.baskent-ank.edu.tr

Geliş tarihi/Received on: 16.02.2014

Kabul tarihi/Accepted on: 18.03.2014