



Asteroid Hyalosis: A Beautiful Marker of an Ugly Disease

Asteroid Hiyaloz: Çirkin Hastalığın Güzel Belirteci

Sushil Kachewar¹, Smita Sankaye¹

¹Rural Medical College, PIMS(DU), Loni, Ta-Rahata, Ahmednagar Maharashtra, INDIA

Cukurova Medical Journal 2014;39 (2): 323-328.

ABSTRACT

Purpose: Asteroid Hyalosis (AH) is the name given to the condition in which calcium soaps gets deposited on vitreous fibrils in eyes. It gives a beautiful shiny star-like appearance in the black vitreous on ocular ultrasound (B Scan). Its asymptomatic nature, unilateral occurrence and unexplained association with diabetes, are points to ponder. Our previous prospective double blind study was continue further to understand the utility of AH as a harbinger of diabetes in otherwise unsuspected individuals.

Material and Methods: In the study period from 2011 to 2013; 400 non diabetic patients and 200 known diabetic patients, between 40-55 years of age were assessed by B mode ultrasonography for the presence of AH.

Results: The overall incidence of AH in our study was 12.75 % in non-diabetic population and 59.5% in diabetic population. We found that the ultrasound demonstration of AH is 88.51% sensitive and 40.81 % specific to identify presence of diabetes and it has a positive predictive value of 69.31 % and a negative predictive value of 70.17 %.

Conclusion: Individuals with diagnosed diabetes have high incidence of AH. Occurrence of AH is more common in individuals who are prone to develop diabetes. So ocular ultrasound should be included in the routine annual health screening programs. Multicentric studies to evaluate the cause-effect relationship are warranted before this dictum becomes a universal doctrine.

Key Words: Eye; Asteroid Hyalosis; Diabetes; Ocular Ultrasound; B mode ultrasound

ÖZET

Amaç: Asteroid Hiyaloz ismini, gözlerdeki camsı fibrillerde kalsiyum sabunlarının depolanması durumundan almaktadır. Bu durum; göz USG'sinde (B Scan) yıldıza benzeyen göz alıcı parlaklıkta gözlenmektedir. Onun semptomik olmayan doğası, tek taraflı oluşumu ve diabetle açıklanamayan ilişkisi dikkat edilecek hususlardır. İleriye dönük çift kör çalışmamız, umulmadık bireylerin aksine diabetin belirtsinde AH'ın faydalarını anlamak üzerine olacaktır.

Materyal ve Metod: 2011 ve 2013 yılları arasında, 400 diyabetik olmayan ve 200 diyabetik hasta AH tanısının değerlendirilmesi için B mode ultrasonografi ile tarandı.

Bulgular: AH'ın ortalama insidansı diyabet olmayan popülasyonda %12.75 iken diyabetik popülasyonda bu oran %59.5'ti. AH'ın USG gösteriminin özgül değeri %40.81, diyabeti tanımlama hassasiyetini %88.51 olduğunu bulduk. Pozitif beklenen değeri %69.31, negatif beklenen değeri %70.17'tir.

Sonuç: Diyabet tanısı konulmuş bireyler yüksek AH insidansına sahiptir. AH'ın oluşumu diyabete meyilli olan bireylerde daha yaygın görülmektedir. Yani göz USG'si rutin olarak yıllık sağlık görünteleme programlarına dahil edilmesi gerekmektedir. Neden-sonuç ilişkisini değerlendirebilmek için çok merkezli çalışmalar evrensel bir doktrin haline gelen bu görüşten çok daha garantilidir.

Anahtar Kelimeler: Göz, Asteroid Hiyaloz, Diyabet, Göz USG, B mod USG



INTRODUCTION

Asteroid Hyalosis (AH) is a condition characterized by unusual presence of calcium

soaps in the vitreous of eye¹. In this condition one can visualize that the collagen fibrils of the vitreous are interrupted with calcium-lipid complexes²⁻⁵. This term was first explained satisfactorily by Benson in 1894⁶ and the nomenclature was coined by Luxenberg and Sime⁷. Although, these intravitreal suspensions cannot be seen with naked unaided eye, these become beautifully visible on Ocular Ultrasound and Fundoscopy^{1,8}.

High spikes on A scan vector are characteristic of AH⁸. Normal posterior segment appears clean and echo free on B scan imaging⁸⁻¹⁸, as shown in Fig. 1. AH on the other hand, demonstrates separate bright echoes that are mobile, do not have any posterior acoustic shadowing (Fig. 2) and show after movements (Fig. 3). Very refractive shiny bodies floating freely in a hazy media is seen on fundoscopy (Fig. 4).

This entity of unknown etiology has been quoted in about 30 -70% of diabetics^{1,8-18}. This prospective double blind study is the continuation of our earlier study¹ done in our quest to understand utility of AH as a harbinger of diabetes in otherwise unsuspected individuals.

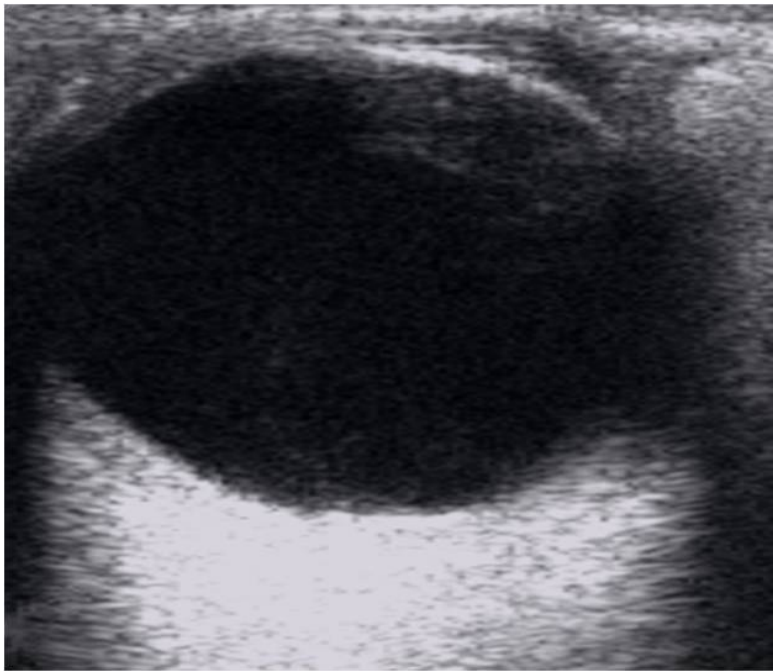


Figure 1. Appearance of vitreous in normal eye. On B mode ultrasound it is echo free.

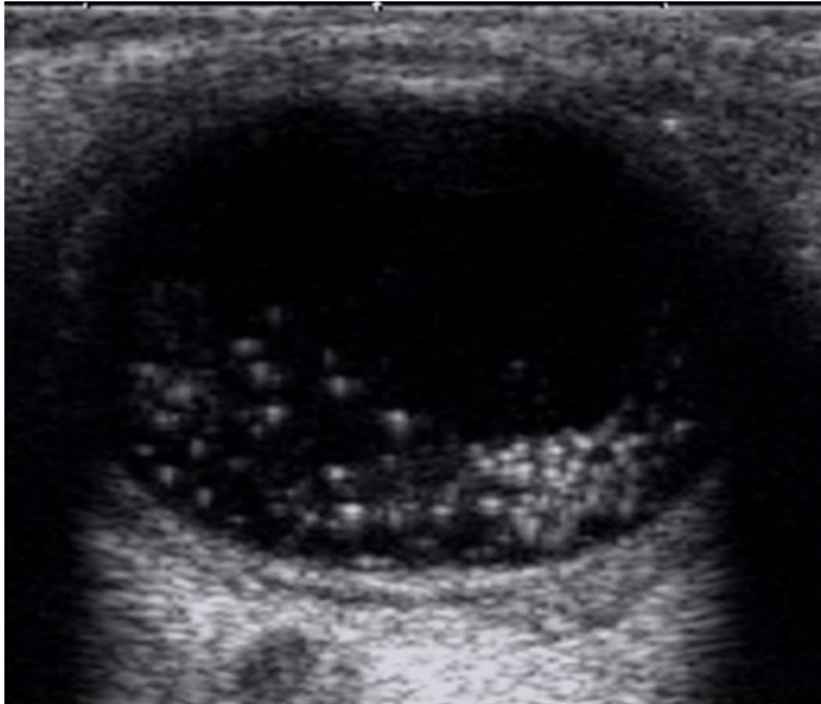


Figure 2. Asteroid Hyalosis seen as bright echoes in black vitreous.

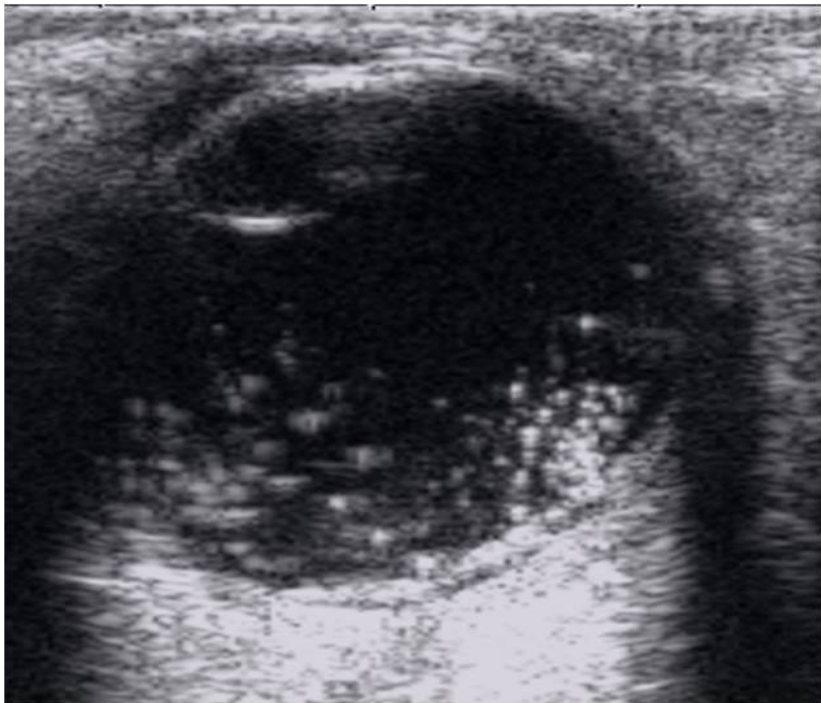


Figure 3. After movements of Asteroid Hyalosis.

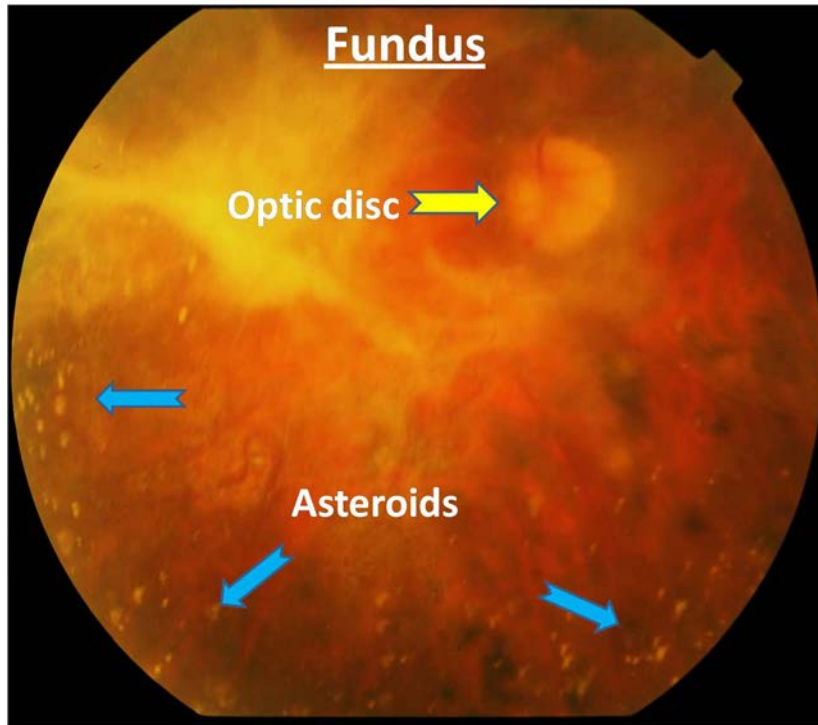


Figure 4. Asteroid Hyalosis on Fundoscopy)

MATERIALS and METHODS

After approval from institutional ethical and research committee, in the study period from 2011 to 2013; 400 non diabetic patients and 200 known diabetic patients, between 40-55 years of age were assessed by B mode ultrasonography for the presence of AH.

Ocular ultrasound was performed by placing them in supine position and using a 8-12 MHz frequency linear ultrasound probe over closed lids over which ultrasound jelly was applied to avoid artifacts^{8,18}.

RESULTS

The following table summarizes our observations:

Table 1: Distribution of participants in the study

Participants	Non diabetic	Diabetic	Total
Males	208	144	352
Females	192	056	248
Total	400	200	600
Participants	AH Present	AH Present	Total
Males	31	98	129
Females	20	21	41
Total	51	119	170
Incidence	12.75 %	59.5%	

The 51 non diabetic patients who had AH in their eyes were then followed up for the development of diabetes at the interval of every 3

months by evaluating their fasting as well as post prandial blood sugar values. By the end of 36 months, 13 out of the 51 patients (25.49 %) had

blood sugar values high enough to label them as diabetic. None of the remaining 38 patients developed diabetes until 36 month follow up.

At three years follow up, when AH was used as the marker for diabetes and blood sugar levels were used as gold standard, number of true

positives was 131 (TP =131), number of true negatives was 40 (TN = 40), number of false positives was 58 (FP = 58) and number of false negatives was 17 (FN = 17). Various statistical calculations were then made as shown in Table 2.

Table 2: Statistical Parameters observed in the study

Sr. No.	Statistical Parameters	Formula	Values	% Results
1	Sensitivity	$\frac{TP \times 100}{TP + FN}$	$\frac{131 \times 100}{148}$	88.51
2	Specificity	$\frac{TN \times 100}{TN + FP}$	$\frac{40 \times 100}{98}$	40.81
3	Positive Predictive Value	$\frac{TP \times 100}{TP + FP}$	$\frac{131 \times 100}{189}$	69.31
4	Negative Predictive Value	$\frac{TN \times 100}{TN + FN}$	$\frac{40 \times 100}{57}$	70.17

DISCUSSION

Literature quotes occurrence of AH in around 30 -70% of diabetics (1, 8-18). Till the pathophysiology and the cause of this interrelationship is still a mystery. In the current study it was seen in 59.5 % of known diabetics.

Our results show that finding of AH was a more sensitive (88.51 %) but a less specific (40.81%) finding for the development of diabetes in an individual. B mode demonstration of AH has a good positive (69.31 %) as well as negative (70.17 %) predictive value in predicting diabetes.

AH was also seen in non-diabetic individuals but the occurrence was not as common as in diabetics.

CONCLUSION

Individuals with diagnosed diabetes have high incidence of AH. Occurrence of AH is more common in individuals who are prone to develop diabetes. So ocular ultrasound should be included in the routine annual health screening programs. Multicentric studies to evaluate the cause-effect relationship are warranted before this dictum becomes a universal doctrine.

REFERENCES

1. Kachewar SG, Patil M. The Emergence of Asteroid Hyalosis as a Sonologist's marker of Diabetes. *PJR*. 2012;22:1-3.
2. Noda S, Hayasaka S, Setogawa T. Patients with asteroid hyalosis and visible floaters. *Jpn J Ophthalmol*. 1993;37:452-5.
3. Topilow HW, Kenyon KR, Takahashi M, Freeman HM, Tolentino FI, Hanninen LA. Asteroid hyalosis-biomechanics, ultrastructure and composition. *Arch Ophthalmol*. 1982;100:964-8.
4. March W, Shoch D, O'Grady R. Composition of asteroid bodies. *Invest Ophthalmol*. 1974;13:701-5.
5. Feist RM, Morris RE, Witherspoon CD, Blair NP, Ticho BH, White MF. Vitrectomy in asteroid hyalosis. *Retina*. 1990;10:173-7.
6. Yazar Z, Hanioglu S, Karakoç G, Gürsel E. Asteroid Hyalosis. *European Journal of Ophthalmology*. 2001;11:57-61.
7. Luxenberg M, Sime D. Relationship of asteroid hyalosis to diabetes mellitus and plasma lipid levels. *Am J Ophthalmol*. 1969;67:406-12.
8. The Sankara Nethralaya Atlas of Ophthalmic Ultrasound. First edition. Jaypee Brothers Medical Publishers (P) Ltd, New Delhi. 2006;56-7.

9. Allison KL, Price J, Odin LJ. Asteroid hyalosis and axial length measurement using automated biometry. *Cataract Refract Surg.* 1991;17:181-6.
10. Byrne SF, Green RL. *Ultrasound of the eye and orbit.* 2 nd ed. Mosby, Inc. St. Louis. 2002.
11. *Ultrasonography of the EYE and Orbit.* Second Edition. Lippincot Williams & Wilkins. Pennsylvania 19106 USA. 2006;76-7.
12. Jaffe N. *The Vitreous in Clinical Ophthalmology.* St.Louis: Mosby, 1969.
13. Cosgrove D, Meire H, Dewbury K. *Clinical Ultrasound a comprehensive text. Abdominal and General Ultrasound.Vol.2.* Second edition. Churchill Livingstone. Harcourt Publishers Limited 2001. Edinburgh: London W1P OLP. 2001;673-4.
14. Sutton D, Fielding JA. *Textbook of Radiology and Imaging.* Volume 2. Elsevier. Churchill Livingstone. London W1T 4LP. 2008;1558-9.
15. McLeod D, Restori M. Rapid B-scanning in ophthalmology. In: Barnett E, Morley P, eds. *Clinical diagnostic ultrasound.* Oxford: Blackwell Scientific. 1985;111-20.
16. Coleman DJ, Lizzy FL, Jack RL. *Ultrasonography of the eye and orbit.* Philadelphia: Lea and Febiger, 1977.
17. McLeod D, Restori M. Ultrasonic examination in severe diabetic eye disease. *Br J Ophthalmol.* 1979;63:533-8.
18. Bergren RL, Brown GC, Duker JS. Prevalance and association of asteroid hyalosis with systemic diseases. *Am J Ophthalmol.* 1991;111:289-93.

Yazışma Adresi / Address for Correspondence:

Dr. Sushil Kachewar
Rural Medical College,
PIMS(DU), Loni, Ta-Rahata,
Ahmednagar Maharashtra, INDIA
Email: sushilkachewar@hotmail.com

geliş tarihi/received :13.01.2014
kabul tarihi/accepted:03.02.2014