



### Acute Interhemispheric Subdural Hematomas: A Report of 3 Cases and Review of the Literature

Akut Intrahemisferik Subdural Hematomlar: Üç Vakanın Sunumu ve Literatürün Gözden Geçirilmesi

Osama Shukir Muhammed Amin

Department of Neurology, Sulaimaniya General Teaching Hospital, Sulaimaniya, IRAQ.

*Cukurova Medical Journal 2014;39(1):137-142.*

#### ABSTRACT

The development of acute supratentorial interhemispheric subdural hematomas is an uncommon yet a highly distinct event because of their unusual location, unknown natural history, and debated management. The majority develop in patients with head trauma, generalized bleeding tendency, or coagulopathy. We report on 3 patients who developed spontaneous acute inter-hemispheric subdural hematomas. They were 72, 66, and 65 years old, respectively. Two were males and the 3<sup>rd</sup> was a female. There was no head trauma, bleeding tendency, or coagulopathy. Two of them were hypertensive but none of them was diabetic, epileptic, or alcoholic. Two patients died, on day 1 and 2 respectively, and the 3<sup>rd</sup> patient was discharged by his next of kin after 3 hours of admission to our Acute and Emergency department. No neurosurgical intervention was carried out and all patients were treated conservatively. The hematoma was fronto-occipital and was located on the left side in 2 patients while in the 3<sup>rd</sup> patient it was a right-sided parieto-occipital one. Although the initial investigations had pointed out to the spontaneous development of those hematomas in our patients, a further search for an underlying etiology was supposed to be done, but the early death of 2 patients and the premature discharge of the 3<sup>rd</sup> patient had intersected with this work-up. The rapid deterioration and death of 2 patients might have been prevented if an early evacuation was done.

**Key Words:** interhemispheric; subdural hematoma; spontaneous; supratentorial

#### ÖZET

Akut supratentoriyal intrahemisferik subdural hematomaların gelişimi yaygın olmamalarına rağmen sıradışı lokasyonları, bilinmeyen hikayeleri ve tartışmalı yönetimi nedeniyle oldukça ayırtedicidir. Majör nedenleri kafa travmaları, kanama yatkınlığı veya koagülopatidir. Burada akut supratentoriyal intrahemisferik subdural hematoma geçiren 3 hastayı rapor ettik. Hastalar sırasıyla 72, 66 ve 65 yaşlarındadır. İlk 2 hasta erkek, 3. hasta ise kadındır. Bu hastalarda kafa travması, kanama eğilimi veya koagülopati yoktu. İkinci hipertansif ama diyabetik, epileptik veya alkolik değiller. İki hasta sırayla 1. ve 2. günlerde öldüler, üçüncü hasta akrabası tarafından akut ve acil bölümüne kabulünden 3 saat sonra taburcu edildi. Hiçbir hastaya nörocerrahi girişimi yapılmadı ve tüm hastalara konservatif tedavi protokolü uygulandı. İki hastada sol frontooksipital hematoma tespit edilirken 3. hastada sağ parietooksipital hematoma tespit edildi. Tüm hastalarımızda hematomun etiyolojisi ve gelişimi tartışmalı olmasına ve iyi araştırılmamasına rağmen ilk iki hastanın erken ölmesi ve 3. hastanın erken taburcu olması bu çalışma grubunun bütünlüğünü bozmuştur. Ayrıca bu iki hasta eğer daha erken takibe alınabilseydi belki de ölmeleri önlenebilir.

**Anahtar Kelimeler:** interhemisferik; subdural hematoma; spontan; supratentoriyal

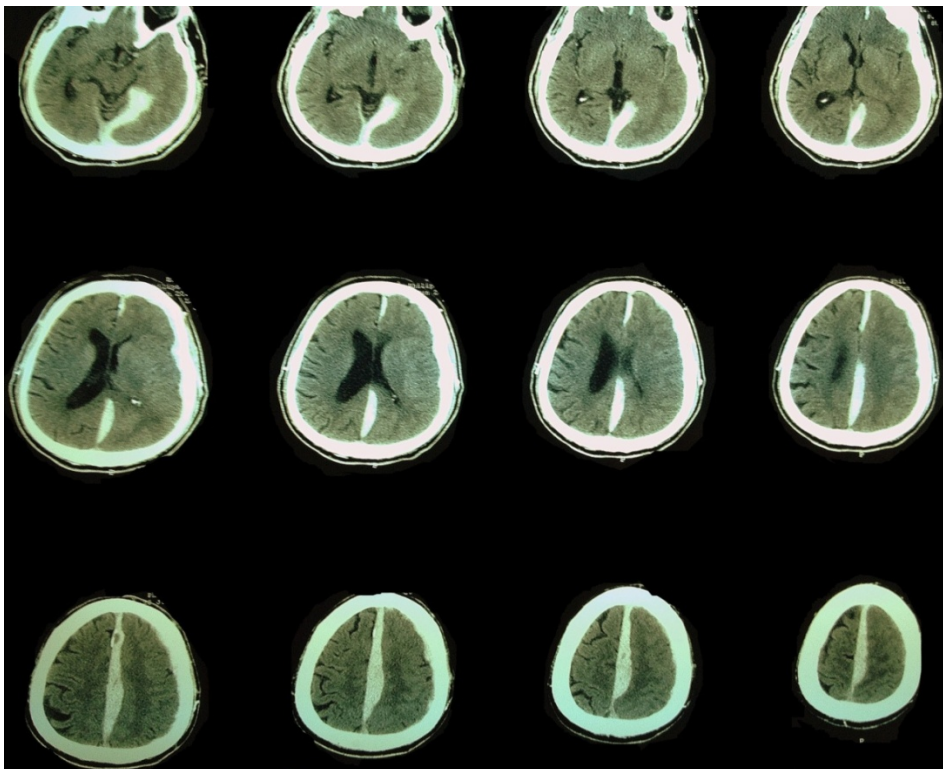
## INTRODUCTION

The development of acute supratentorial interhemispheric subdural hematomas is an uncommon vascular event because of their unusual location, unknown natural history, and debated management. The majority of such hematomas develop in patients with head trauma, generalized bleeding tendency, or coagulopathy<sup>1-4</sup>.

## CASES

Patient 1 was a 72-year-old retired Kurdish male. He was brought to our Acute and Emergency department by his nephew who stated that the patient had developed sudden severe pancephalic headache and repeated vomiting 2 hours ago. He was obtunded. Both planter reflexes were extensors. No signs of head trauma were found. His blood pressure was 230/120 mmHg with

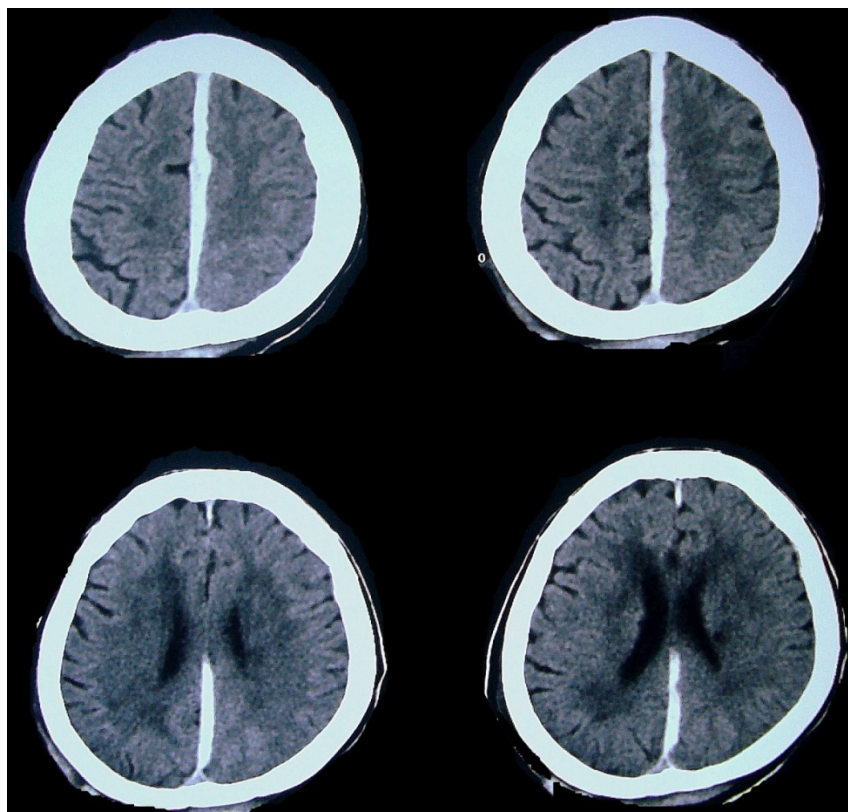
a regular pulse rate of 120 beats per minute, hyperventilation, and a temperature of 37.1 °C. His urgent non-contrast CT brain scan showed an extensive left-sided supratentorial acute interhemispheric subdural hematoma (figure 1). His routine blood tests, including complete blood counts, prothrombin time, and thromboplastin time were unremarkable. 12-lead ECG showed voltage criteria of left ventricular hypertrophy. He had longstanding hypertension for which he declined receiving any treatment. He was on no anti-platelets or anticoagulants. The patient's nephew said that the patient was watching the news on TV when suddenly developed this sudden and severe headache. The neurosurgical department suggested a conservative treatment only. The patient died after 17 hours of admission.



**Figure 1.** Non-contrast CT brain scan of patient 1. There is a left-sided acute inter-hemispheric subdural hematoma, extending from the frontal pole to the occipital pole. The hemorrhage has also extended over the left tentorium. It compresses the underlying cerebral hemisphere and the left lateral ventricle.

Patient 2 was a 66-year-old Kurdish housewife who was referred to Acute and Emergency department from a rural primary care center. Five hours ago, the patient collapsed at home during dinner and complained of severe pancephalic headache. No seizures or vomiting occurred. She was hypertensive and non-complaint with her oral valsartan and bisoprolol. An urgent non-contrast CT brain scan revealed an acute left-sided, supratentorial, interhemispheric subdural hematoma in addition to peri-ventricular white matter ischemia and scattered lacunes (figure 2). Three years ago, she developed a lacunar stroke. Aspirin and clopidogrel were prescribed. After 1 year, a right-sided deep cerebellar hemorrhagic stroke developed. Her dual anti-platelet therapy was stopped and anti-

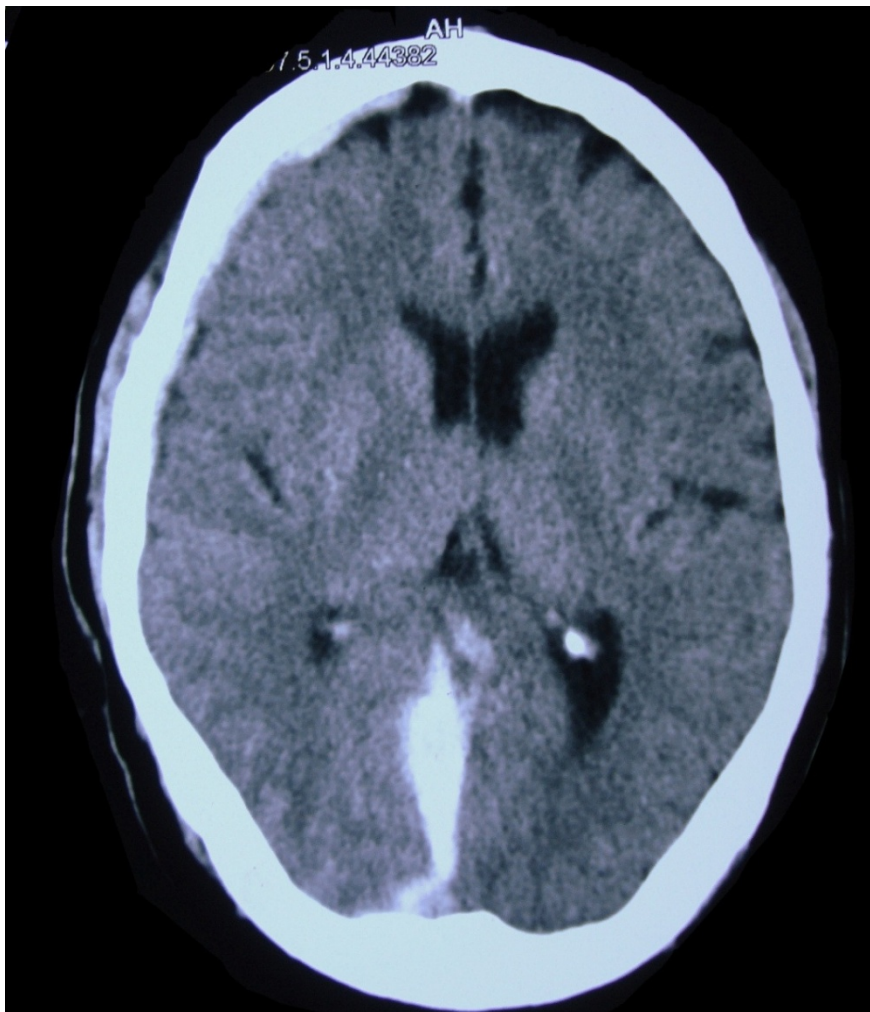
hypertensive medications and a statin were prescribed. During the past 2 years, she received neither antiplatelet therapy nor warfarin. Her Glasgow Coma Scale was 6/15. Both planters were flexors. Her blood pressure was 190/130 mmHg, her pulse rate was 62 beats per minute, and her respiratory rate was 11 cycles per minute. She was a febrile. No signs of head trauma or physical abuse were detected. Her blood tests including prothrombin and thromboplastin times were within their normal reference range and her complete blood count was unremarkable. Her 12-lead ECG showed T-wave inversion leads I, II, aVL, V5 and V6 leads. The neurosurgery trainee recommended a non-operative medical treatment only. The patient was admitted to our intensive care unit and died the next day.



**Figure 2.** Non-contrast CT brain of patient 2. There is a left-sided acute inter-hemispheric subdural hematoma. Note the periventricular ischemia and the small lacune at the left centrum semiovale. In spite of the relatively benign appearance of the hemorrhage, the patient rapidly succumbed and died on day 2.

Patient 3 was 65-year-old Arabic merchant who was visiting our city for doing some business. The patient was brought to our A&E by his cousin who said that the patient suddenly collapsed, complained of severe headache, and vomited twice half an hour ago. They were at the hotel's lobby sitting. The patient's cousin stated that the patient was not hypertensive or diabetic as far as he knew and he denied any history of head trauma

or assault. He did not drink alcohol. He was drowsy and complaining of severe headache and nausea. An urgent non-contrast CT brain scan revealed an acute, right-sided, posteriorly situated interhemispheric subdural hematoma (figure 3). The patient cousin requested a discharge so that they will go back to Baghdad where they live. His blood tests and 12-lead ECG were unremarkable.



**Figure 3.** Non-contrast CT brain scan of patient 3. There is a right-sided acute inter-hemispheric subdural hematoma, which is posteriorly located. There is also a very small right-sided acute subdural hematoma at the right frontal pole.

## DISCUSSION

During the year 1940, Aring and Evans<sup>1</sup> reported on an aberrant location of an acute subdural hematoma. They found that the clot covered the cerebral cortex from the tip of the frontal lobe to the tip of the occipital lobe. The clot was limited mesially by the superior longitudinal sinus; inferiorly, it rarely extended for any distance over the temporal lobe, the inferior border of the hemorrhage corresponding roughly to a line parallel with the sylvian fissure. Since then, several researcher have worked on this subject and contributed a lot to our current understanding of the now so-called inter-hemispheric subdural hematoma (ISH)<sup>2-12</sup>.

According to Takeda and coworkers<sup>4</sup> 48 cases of acute subdural hematomas were admitted to their hospital between 1977 and 1986; only 3 patients (6%) of them had subdural hematomas within the inter-hemispheric fissure. In 2009, Schilder and Weisfelt<sup>11</sup> found that the pertinent medical literature has reported 100 cases since the publication of Aring's paper. Although the inter-hemispheric localization of subdural hematomas is more common in children (as part of shaken children syndrome), it is considered rare in adults<sup>7</sup>. Head trauma is responsible for 80-90% of ISHs<sup>7,12,13</sup>. Coagulopathy, thrombocytopenia, and ruptured intracranial aneurysms may result in ISHs as well<sup>6,8,10,12</sup>.

According to Ishikawa and colleagues<sup>8</sup> spontaneous non-traumatic ISHs are extremely rare. Spontaneous subdural hematoma refers to a hemorrhage occurring in the absence of provoking factors, such as diffuse cerebral atrophy, head trauma, or anticoagulation therapy/bleeding tendency.

In 1988, Houtteville and colleagues<sup>5</sup> found that only 3 cases of spontaneous ISHs were reported in the medical literature since the

publication of Aring's paper in 1940. They also reported on 7 cases; 2 of them were spontaneous. According to Depreitere<sup>14</sup>, rotational acceleration in the sagittal plane and in a forward direction is most likely to produce acute subdural hematomas due to bridging vein rupture. Fruin and coworkers<sup>3</sup> concluded that the majority of traumatic cases were due to direct occipital trauma because of the anatomy of the bridging veins; therefore, chronic inter-hemispheric hematomas are rare since the natural history of these lesions is to spread out over the cerebral convexity. An arterial source has also been documented. In one of the cases reported by Houtteville and colleagues<sup>5</sup> a bleeding peri-callosal artery was found. A ruptured internal carotid artery aneurysm was the etiology behind the formation of ISH reported by Ishikawa and colleagues<sup>8</sup>. Fein and Rovit<sup>15</sup> reported on an inter-hemispheric subdural hematoma secondary a hemorrhage from a rupture of callosomarginal arterial aneurysm.

According to Glista et al<sup>2</sup> hemiparesis, worse in the lower than the upper extremity, or lower extremity monoparesis is characteristic of these ISHs. A variable constellation of altered consciousness (ranging from drowsiness to deep coma), focal/lateralizing signs, headache, nausea, and vomiting is usually encountered, depending on the localization and the amount of the hemorrhage<sup>4</sup>

Depending on the overall clinical picture, the treatment of ISH has to be decided between conservative management or surgical intervention. Whereas conservative treatment may be followed in those who are neurologically stable, surgical intervention is often reserved for patients with pronounced symptoms or neurological deficits<sup>6,11,15</sup>.

These ISHs carry a relatively high mortality rate; Houtteville and colleagues<sup>5</sup> found a 35% case fatality rate among victims.

## CONCLUSION

Patients 1 and 2 did not undergo any surgical intervention and they succumbed rapidly and died; the outcome might well have been different if those 2 patients underwent a surgical evacuation. In spite of the relatively benign presentation of patient 3, we were unable to follow-up the patient, as his cousin discharged him 3 hours after admission and they went back to Baghdad. Although the initial investigations had pointed out to the spontaneous development of those hematomas in our patients, a further search for an underlying etiology was supposed to be done, but the early death of 2 patients and the premature discharge of the 3<sup>rd</sup> patient had intersected with this work-up.

## REFERENCES

1. Aring CD, Evans JP. Aberrant location of subdural hematoma. *Arch Neurol Psychiatry* 1940;44:1296-306.
2. Glista GG, Reichman OH, Brumlik J, Fine M. Interhemispheric subdural hematoma. *Surg Neurol* 1978;10:119-22.
3. Fruin AH, Juhl GL, Taylon C. Interhemispheric subdural hematoma. Case report. *J Neurosurg* 1984;60:1300-2.
4. Takeda N, Kurihara E, Matsuoka H, Kose S, Tamaki N, Matsumoto S. [Three cases of acute interhemispheric subdural hematoma]. *No Shinkei Geka* 1988;16:87-92.
5. Houtteville JP, Toumi K, Theron J, Derlon JM, Benazza A, Hubert P. Interhemispheric subdural haematomas: seven cases and review of the literature. *Br J Neurosurg*. 1988;2:357-67.
6. Iplikçioğlu AC, Bayar MA, Kökes F, Doğanay S, Gökçek C. Interhemispheric subdural haematomas. *Br J Neurosurg*. 1994;8:627-31.
7. Rapanà A, Lamaida E, Pizza V, Lepore P, Caputi F, Graziussi G. Inter-hemispheric scissure, a rare location for a traumatic subdural hematoma, case report and review of the literature. *Clin Neurol Neurosurg*. 1997;99:124-9.
8. Ishikawa E, Sugimoto K, Yanaka K, Ayuzawa S, Iguchi M, Moritake T, et al. Interhemispheric subdural hematoma caused by a ruptured internal carotid artery aneurysm: case report. *Surg Neurol*. 2000;54:82-6.
9. Senel A, Cokluk C, Onder A, Iyigün O, Incesu L. Acute interhemispheric subdural hematomas. Report of nine cases. *J Neurosurg Sci*. 2001;45(2):97-102.
10. Shankar A, Joseph M, Chandy M J. Interhemispheric subdural hematoma: An uncommon sequel of trauma. *Neurol India*. 2003;51:63-4.
11. Schilder JC, Weisfelt M. Ataxia associated with an interhemispheric subdural hematoma: a case report. *Cases Journal*. 2009;2:8876.
12. Kawoosa NN, Bhat AR, Rashid B. Interhemispheric Acute Subdural Hematomas. *Iran Red Crescent Med J*. 2011;13:289-90.
13. Sadrolhefazi A, Bloomfield SM. Interhemispheric and bilateral chronic subdural hematoma. *Neurosurg Clin N Am*. 2000;11:455-63.
14. Depreitere B, Van Lierde C, Sloten JV, Van Audekercke R, Van der Perre G, Plets C, et al. Mechanics of acute subdural hematomas resulting from bridging vein rupture. *J Neurosurg*. 2006;104:950-6.
15. Fein JM, Rovit RL. Interhemispheric subdural hematoma secondary hemorrhage from a callosomarginal artery aneurysm. *Neuroradiology*. 1970;1:183-6.
16. Bartels RH, Verhagen WI, Prick MJ, Dalman JE. Interhemispheric subdural hematoma in adults: case reports and a review of the literature. *Neurosurgery*. 1995;36:1210-4.

## Yazışma Adresi / Address for Correspondence:

Osama Shukir Muhammed Amin  
Sulaimaniya City Post-Office, PO BOX 196,  
Sulaimaniya City, IRAQ  
e-mail: dr.osama.amin@gmail.com

geliş tarihi/received :28.08.2012  
kabul tarihi/accepted:25.09.2012