



The Importance of Electrocardiographic Screening in Cardiac Contusion after Blunt Chest Trauma: Case Reports

Künt Göğüs Travmasından Sonra Kardiyak Kontüzyonda Elektrokardiyografik Görüntülemenin Önemi: Olgu Sunumları

Keziban Uçar Karabulut¹, Hüseyin Narcı¹, Başar Cander², Mehmet Gül², Çetin Duman³

¹Baskent University Medical Faculty, Department of Emergency Medicine, KONYA

²Necmettin Erbakan University Meram Medical Faculty, Department of Emergency Medicine, ³Department of Cardiology Medicine, KONYA

Cukurova Medical Journal 2013; 38 (4): 754-758.

ABSTRACT

Tracking and monitoring of patients with blunt chest trauma, especially blunt trauma is very important. As in all kinds of trauma, cardiac contusion in isolated chest trauma may result in acute coronary syndromes. We describe two patients who present with acute coronary syndrome after blunt chest trauma. Their ECG confirmed ST elevations in the inferior derivations, medical therapies and coronary angiography were carried out. Coronary angiographies have revealed no pathology in the coronary arteries. Their conditions were considered to be related to cardiac contusion due to trauma and stress. Cardiac contusion may occur in isolated chest traumas; however, it should be remembered that acute coronary syndrome may develop along with stress after any kind of trauma.

Key Words: Blunt chest trauma, cardiac contusion, ECG screening

ÖZET

Künt göğüs travması geçiren hastaların takip ve monitorizasyonu önemlidir. İzole künt göğüs travmasına bağlı kardiyak kontüzyon takiben akut koroner sendrom gelişebileceği unutulmamalıdır. Künt göğüs travması sonucu akut koroner sendrom gelişen iki hasta tanımlamaya çalıştık. Hastaların EKG lerinde inferior derivasyonlarda ST elevasyonu tespit ettik, hastalar medikal tedavi ve koroner anjiyografi yapıldı. koroner anjiyografi sonucu koroner arterlerde herhangi bir patoloji saptanmadı. Onların durumu, travma ve stres nedeniyle kardiyak kontüzyona bağlandı. Kardiyak kontüzyon izole künt göğüs travmalarında oluşabilir, bununla birlikte hertürlü travma ve stres sonucu akut koroner sendromu gelişebileceği unutulmamalıdır.

Anahtar Kelimeler: Künt göğüs travması, kardiyak kontüzyon, EKG görüntüleme

INTRODUCTION

The number of blunt traumas is increasing in the world due to the increase in road accidents. Cardiac contusion is usually caused by blunt chest trauma and therefore, is frequently suspected in patients involved in car or motorcycle accidents. It is the leading and the most neglected cause of mortality after trauma¹.

The prevalence of cardiac contusion which occurs following blunt chest trauma due to road accident, sports injury, compression, etc., varies between 7% to 71%^{2,3}.

Retrospective studies have shown dissections in coronary angiograms and circulation defects in LAD on thoracic computerized tomography scans (CT)⁴. Cardiac herniation with pericardial rupture is

a very fatal complication, which has been reported in the literature⁵.

In this paper, we have reported two cases which had no cardiac symptoms in the early period following blunt chest trauma, and which presented with signs after some hours.

Case Report 1

A 52-year-old male patient was brought to the Emergency Department after a road accident. His medical history was unremarkable, except for being a smoker for 25 years, 1 packet/day. The physical examination revealed: good general condition, conscious, blood pressure: 130/90 mmHg, heart rate: 95/minutes, ecchymosis and edema in the left palpebra, a 3 cm cut over the left eyebrow and tenderness with palpation on the whole anterior chest wall. Other systems were unremarkable. Bi-directional X-Rays of the head and the cervical vertebral column, in addition to posteroanterior chest X-Rays were performed, which revealed fractures in the left third, fourth and fifth ribs. Abdominal ultrasound showed no

pathology. ECG was unremarkable. The patient was observed with the diagnosis of general body trauma at the Emergency Department Observation Room. At the fourth hour of observation, he had a sudden decrease in blood pressure. He was transferred to the Intensive Care Unit. The blood pressure was 80/50 mmHg. Rapid saline infusion was commenced. The new ECG revealed ST elevations in D2, D3 and aVF (inferior derivations) (figure 1). A blood sample was obtained to study cardiac enzyme levels.

The patient's condition underwent the consultation of the Cardiology Department. Bed-side echocardiography revealed inferior wall and right ventricular dysfunction and aortic insufficiency of grade II. Coronary angiography was planned and the patient was hospitalized at the Cardiology Clinic. Coronary angiography revealed no pathology in the coronary arteries. The patient completely recovered on day three after trauma. ECG and cardiac enzymes were normal. The patient was discharged with relief from the hospital.

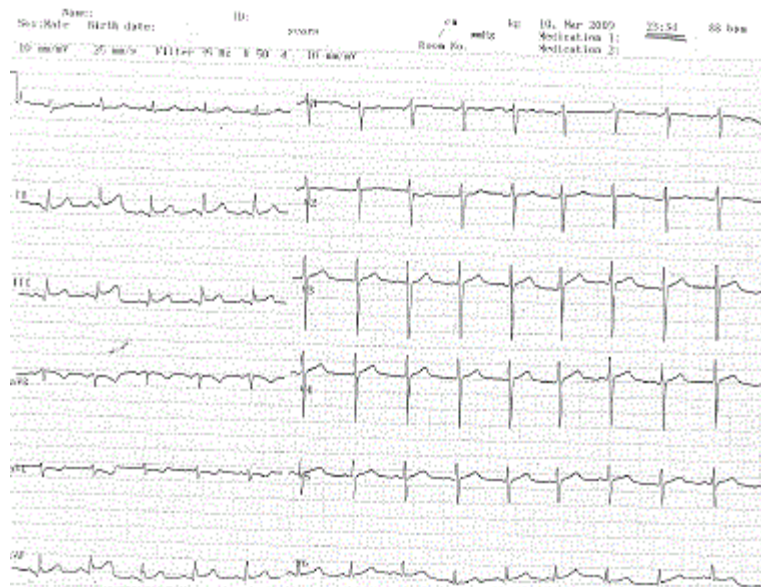


Figure 1. ECG revealed ST elevations in D2, D3 and aVF

Case Report 2

A 48-years-old female patient presented to the ED after having suffered a fall from a grapevine tree of approximately two meters height. Her medical history revealed hypertension with irregular use of medication. The findings of physical examination at the time of admission were as follows: General condition was moderate; she was conscious, blood pressure: 180/90 mmHg, heart rate: 90/minute, a scalp laceration of approximately 10 cm on the occipital area, tenderness increasing with palpation and breathing all over the anterior chest wall. Other system findings were normal. A sternum fracture was seen on direct radiograms. Abdominal ultrasound was normal. The patient who had severe pain in the anterior chest wall underwent a thoracic CT, which revealed no pathology. ECG was normal. The

patient was transferred to the Intensive Care Unit for monitoring. She was given oxygen. In the new ECG at the 70th minute, there were ST elevations in the inferior derivations (D2, D3 and aVF) (figure 2).

The patient's condition underwent a consultation of the Cardiology Department. Bed-side echocardiography was normal. She was administered Coraspin 100 mg, hydration and nitroglycerine. Coronary angiography was performed due to continuing chest pain. All coronary vessels were seen to be normal. Her complaints regressed during the follow-up. Her condition was considered to be related to cardiac contusion due to trauma and stress. As her general condition was good, she was discharged from the hospital 72 hours after trauma.

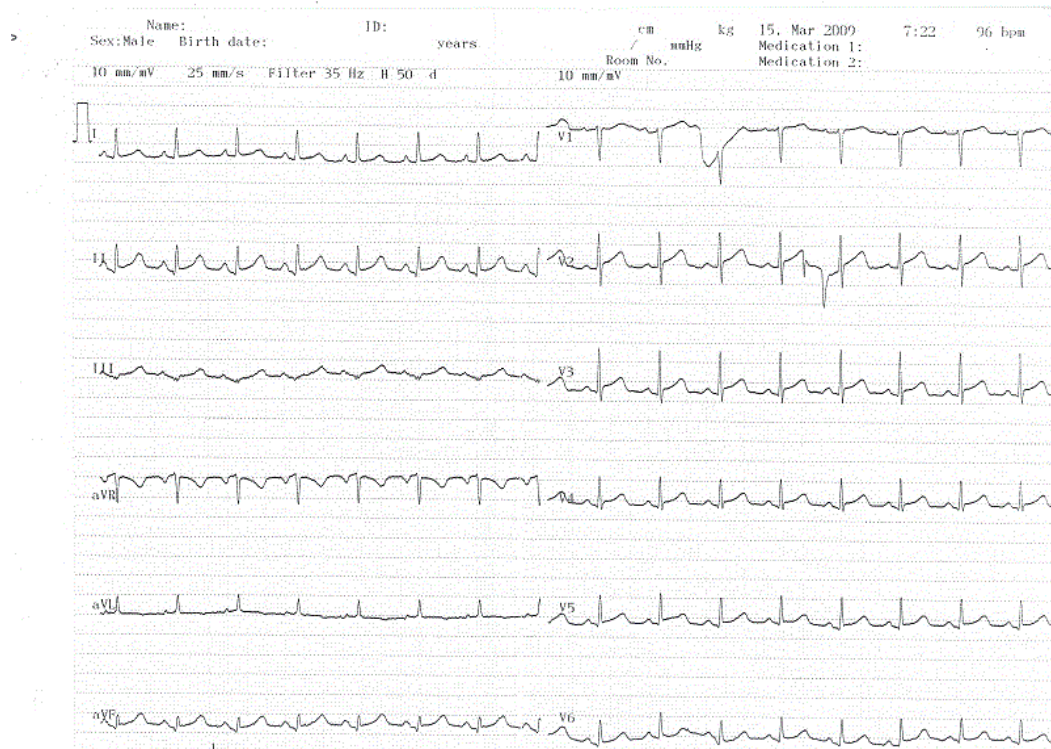


Figure 2. ECG revealed ST elevations in D2, D3 and aVF

DISCUSSION

It has been suggested that severe traumas are associated with neurohormonal, hemodynamic and clotting changes. These changes may cause cracking in weak atheromatous plaques, thrombocyte activation and vasoconstriction in coronary vessels.

Cardiac contusion due to blunt chest trauma is a life-threatening complication because of the late onset of clinical findings and difficulty in diagnosis^{6,7}.

Many diagnostic methods such as ECG, biochemical cardiac markers, transthoracic and transoesophageal echocardiography, and radionuclide imaging studies with multi-detector CT are frequently used in the diagnosis. However, it is reported that none is adequate alone in the diagnosis and the definitive diagnosis can only be made by histological examination of the heart⁸. Utilizing a non-invasive method, transthoracic echocardiography, which is moderately sensitive in the diagnosis of cardiac contusion, may detect valvular dysfunction, right and left ventricular enlargement, intracardiac thrombus, pericardial effusion and dyskinetic movements in cases of severe contusion. ECG changes in blunt chest trauma are usually considered to be related to other causes, and cases of mild cardiac contusion cannot be diagnosed. ECG changes generally occur within the first hours after trauma. It has been reported that although ECG and echocardiography findings may be normal in the early periods, fatal cardiac arrhythmias may occur after 48 hours^{9,10,11}.

In our cases, although the findings of physical examination and ECG at the time of first admission were normal, changes occurred during the follow-up.

CONCLUSIONS

In spite of the normal ECG findings and stable clinical condition on admission in patients with

blunt chest trauma, cardiac contusion may develop and may cause life-threatening cardiac arrhythmias; thus, such patients should be continuously monitored with ECG. Follow-up and monitoring is vital in patients with blunt traumas, especially in blunt chest traumas. Cardiac contusion may occur in isolated chest traumas; however, it should be remembered that acute coronary syndrome may develop along with stress in any kind of trauma. We believe that every patient with blunt thoracic trauma should be monitored for at least 24 hours.

REFERENCES

1. Girişgin AS, Cander B, Gederet YT, Ağralı Y. The role of cTnI in detection of etiological factors of cardiac contusion. *Turkish Journal of Trauma and Emergency Surgery*. 2002;8:82-5
2. Vougiouklakis T, Peschos D, Doulis A, Batistatou A, Mitselou A, Agnantis NJ. Sudden death from contusion of the right atrium after blunt chest trauma: case report and review of the literature. *Injury*. 2005; 36:213-7.
3. Rudusky BM. Classification of myocardial contusion and blunt cardiac trauma. *Angiology*. 2007;58:610-3
4. Gerard O, Pierre M, Edo K, Muhamed S. Acute myocardial infarction due to left anterior descending coronary artery dissection after blunt chest trauma. *J Emerg Radiol*. 2010; 2:149-51
5. Nakamura T, Maloney JD, Osaki S. Traumatic pericardial rupture without cardiac injury. *Gen Thorac Cardiovasc Surg*. 2008; 56:602-5.
6. Bertinchant JP, Polge A, Mohty D, Nguyen-Ngoc-Lam R, Estorc J, Cohendy R et al. Evaluation of incidence, clinical significance, and prognostic value of circulating cardiac troponin I and T elevation in hemodynamically stable patients with suspected myocardial contusion after blunt chest trauma. *J Trauma*. 2000; 48:924-31.
7. Peter J, Kirchner A, Kuhlisch E, Menschikowski M, Neef B, Dressler J. The relevance of the detection of

- troponins to the forensic diagnosis of cardiac contusion. *Forensic Sci Int.* 2006; 160:127-33.
8. Seval İzdeş, Erdal Özcan, Serpil Taştan, Orhan Kanbak. Kardiyak Kontüzyon. *Türk Anest Rean Der Dergisi.* 2008; 36:261-65.
 9. Sybrandy KC, Cramer MJ, Burgersdijk C. Diagnosing cardiac contusion: old wisdom and new insights. *Heart.* 2003; 89:485-9.
 10. Sakka SG, Huettemann E, Giebe W, Reinhart K. Late cardiac arrhythmias after blunt chest trauma. *Intensive Care Med.* 2000; 26:792-5.
 11. Ghersin E, Khoury A, Litmanovich D, Lorber A, Halberthal M, Engel A. Comprehensive multidetector computed tomography assessment of severe cardiac contusion in a pediatric patient: correlation with echocardiography. *J Comput Assist Tomogr.* 2005; 29:739-41.

Yazışma Adresi / Address for Correspondence:

Dr. Keziban Uçar Karabulut
Baskent University Medical Faculty,
Emergency Department
Hocacihan Mah. Saray Cad. No 1
Selçuklu/ KONYA
e-mail: hsnarci@gmail.com

geliş tarihi/received :25.12.2012
kabul tarihi/accepted:21.01.2013