



### Ultrasound Review of Metastatic Lymphadenopathy

#### Metastatik Lenfadenopatilerin Ultrasonografik Değerlendirmesi

Sushil Ghanshyam Kachewar<sup>1</sup>, Smita Balwant Sankaye<sup>1</sup>

<sup>1</sup>Rural Medical College, PIMS(DU), Loni, Maharashtra, INDIA

*Cukurova Üniversitesi Tıp Fakültesi Dergisi (Cukurova Medical Journal) 2013; 38 (2):196-201.*

#### ABSTRACT

Metastatic Lymphadenopathy is a common occurrence now with the earlier detection possible due to advances in imaging sciences. Although, at times the site of original malignancy is known; there are instances when the primary source of malignancy remains unknown. Ultrasound has the potential to non invasively evaluate the affected lymph nodes. Hence we reviewed the ultrasound findings in all fine needle aspiration cytology proven cases of metastatic lymphadenopathy that presented in the imaging department in the last 12 months. Multiple criteria on Grey Scale ultrasound imaging and on Color Doppler ultrasound imaging were used to label metastatic lymphadenopathy. Round nodes without any matting, presence of intranodal necrosis, intranodal calcifications, increased vascularity and elevated Doppler Pulsatility and Resistivity Indices were the hallmarks of metastatic lymphadenopathy which enabled correct diagnosis with a sensitivity of 85.25% and a specificity of 98.36 %. In our review, the most sensitive and specific criteria was the Roundness Index on Gray scale imaging and Resistance to Perfusion on Color Doppler imaging. This review shows how, ultrasound can satisfactorily diagnose metastatic lymphadenopathy and can therefore be used in the diagnosis as well as follow up of such cases.

**Key Words:** Lymph node metastases; Ultrasound; Gray Scale, Colour Doppler, Imaging.

#### ÖZET

Metastatik lenfadenopatiler görüntüleme tekniklerindeki gelişmeler sayesinde daha yaygın olarak görülmektedir. Her ne kadar malign bölge çoğu kez bilinsede malign dokunun temel kökeninin belirlenemediği durumlarda vardır. Ultrasonografi hastalıklı lenf nodlarının noninvaziv olarak değerlendirme potansiyeline sahiptir. Bu bağlamda, bizde görüntüleme bölümümüze son 12 ayda gelmiş iğne aspirasyon sitolojisi ile metastatik lenfadenopatileri doğrulanmış vakaların ultrasonografik bulguları değerlendirdik. Metastatik lenfadenopatilerin işaretlenmesinde birçok kriter gözönünde bulundurulmak suretiyle gri skala ve renkli doppler ultrasonografik görüntüleme metodları kullanılarak değerlendirilmiştir. Sertleşme göstermeyen yuvarlak nodlar, nodüler nekroz oluşumu, nodüler kalsifikasyon, artan vaskularizasyon, artan Doppler pulsallitesi ve rezistans indeksleri metastatik lenfadenopatilerin karakterizasyonunun temelini oluşturmakla beraber doğru teşhisi oranını yaklaşık %85.25 ile %98.36 arasındadır. Derlememizdeki en duyarlı ve spesifik kriterler gri skala görüntülemesindeki yuvarlaklık indeksi ve renkli doppler görüntülemesindeki perfüzyon rezistansıdır. Bu derleme ayrıca ultrasonografinin metastatik lenfadenopatilerin teşhisindeki doğruluğu ve dolayısıyla bu tip vakaların teşhis ve takibindeki faydalarını vurgulamaktadır.

**Anahtar Kelimeler:** Lenf nodu metastazları; Ultrasonografi; Gri Skala, Renkli Doppler Görüntülemesi

## INTRODUCTION

To assess the enlarged lymph nodes with ultrasound alone is a daunting task and an everyday affair for the Sonologist<sup>1</sup>. Functionally the lymph nodes clear the lymph and mount immune response<sup>2,3,4</sup>. Host of infective, inflammatory as well as neoplastic pathologies therefore dwell in these lymph nodes. Metastatic Lymphadenopathy is one such entity, which should not be missed on ultrasound.

Clinical examination alone cannot determine the exact cause of lymph node enlargement<sup>5,6,7</sup>. As the treatment options are different for different pathologies, it is essential that the exact cause be known<sup>8</sup>. This review therefore focusses on identifying features of lymph nodes on ultrasound examination that will enable to label them as Metastatic Lymphadenopathy (ML).

## MATERIALS and METHODS

Ultrasound features of enlarged lymph nodes proved as metastatic nodes on fine needle aspiration cytology (FNAC) were reviewed for the last 12 months. Following ultrasound features were used:

### A) Grey scale criteria:

- Long by Short axis ratio or the Roundness Index – in which the maximum lymph node diameter is bisected by the perpendicular transverse diameter.
- Gross appearance - Whether they looked homogenous or heterogeneous.
- Hilus - whether present or absent.

$$\text{Pourcelot's Resistivity Index [9]} = \frac{\text{Peak systolic velocity} - \text{End diastolic velocity}}{\text{Peak systolic velocity}}$$

$$\text{Gosling's Pulsatility Index [9]} = \frac{\text{Peak systolic velocity} - \text{End diastolic velocity}}{\text{Time averaged maximum velocity}}$$

- Necrosis - Inside the node is seen as anechoic, irregular areas. Its presence or absence was noted.
- Calcification - Seen as echogenic areas in the node. Its presence or absence was noted.
- Borders- Whether they are sharp or not is noted. If sharp, there is well-defined boundary between lymph node and surrounding soft tissue.
- Matting - is the clumping of nodes or adherence to each other such that there is no normal echogenic connective tissue in between. Its presence or absence was noted.
- Edema - of the surrounding tissue is seen as diffuse decrease in the echogenicity of adjacent tissues, with loss of facial planes and thickening of skin. Its presence or absence was noted.
- Posterior enhancement- Structures posterior to the node are more echogenic than neighboring structures.

### B) Perfusion pattern:

Nodes were assessed for the pattern of vascular perfusion using the color Doppler mode.

**C) Perfusion Intensity:** Using color Doppler was assessed and subjectively classified as -

1. Hypo perfusion -Minimal perfusion compared to adjacent fat and soft tissue.
2. Iso perfusion -Perfusion similar to adjacent fat and soft tissue.
3. Hyper perfusion -Perfusion more than adjacent fat and soft tissue.

**D) Resistance to Perfusion:** Assessed by calculating Resistivity (RI) and Pulsatility (PI) indices which are given as:

## RESULTS

On FNAC, total 61 patients were diagnosed to have ML.

**Assessment by Gray Scale criteria:** The Roundness Index was less than two in 53 patients (86.88%). On gross appearance, nodes in 35 (57.37%) of ML cases were homogenous and 26(42.62%) were heterogeneous. There was absence of hilus in 40 (65.57%), central in 8 (13.11%) and displaced or distorted in 13(21.31%). Intranodal necrosis was seen in 24 (39.34%), Intranodal calcification was seen in 3(10%), posterior enhancement was seen in 13(43.33%), sharp borders were present in 23(76.66%), surrounding edema was seen in 1(1.63%) and matting was seen in 1 (1.63%) cases of ML.

**Assessment by Color Doppler criteria:** Out of 61 patients who were diagnosed to have ML, only 4 (6.66%) showed hilar vascularity. Majority (93.44%) showed predominantly peripheral pattern of vascularity or a combination of peripheral with central or hilar variety and it was hypointense in 34.42% and isointense in 13.11; 76.66% had Pulsatility Index more than 1.4 and Resistance Index % was more than 0.7 in 76.66 % cases of ML.

The sensitivity and specificity of each parameter is shown in Table 1 that shows the statistical co-relation of all observations for differentiating between benign and malignant lymphadenopathy. Thus Gray Scale as well as Color Doppler criteria could diagnose the ML with high sensitivity and specificity.

**Table 1- Statistical Co-relation of all Observations for differentiating between Benign and Malignant Lymphadenopathy**

Sr. #	Ultrasound Criteria	Sensitivity	Specificity
1	Grey Scale	85.25	97.54
2	Perfusion Pattern	93.44	66.80
3	Perfusion Intensity	75.41	80.33
4	Resistance to Perfusion	83.61	99.18
5	All of the above Combined	85.25	98.36

## DISCUSSION

No sooner is the clinical examination of enlarged lymph nodes is done; inadvertently the patient is referred for ultrasound. Diagnostic ultrasound often rises to the occasion and provides the necessary and sought for information non-invasively. It is thus an important armamentarium in assessing ML<sup>10</sup>. Color Doppler Sonography further adds to the details of this examination<sup>11</sup>. In this review the ultrasound

features of enlarged nodes in FNAC proved 61 patients of ML were compiled to come out with the statistical data on the utility of ultrasound in evaluating ML.

The roundness index has been the most important Grey Scale criteria in our study. The value of less than two was seen in 86.66% of metastases, thereby implying that lymph nodes which are normally oval become round if they are involved by metastatic process as shown in Figure 1a. Studies done elsewhere have also reported

the ratio to be less than two in 97% of infraclavicular carcinomas<sup>6,8</sup>, in 25 % of metastatic lymph nodes<sup>11,12</sup>, 95% of metastatic nodes<sup>7</sup>.

Hence it has been stated that the ratio less than two suggests malignant nature of the node<sup>1,13</sup>. Nodes appear heterogenous in 70% of ML. All normal nodes are homogenous, 38.3% of metastases from pharyngeal, laryngeal and esophageal carcinomas and 9.4% of metastases from infraclavicular carcinomas have been reported to be heterogeneous<sup>8</sup>. Other studies have shown variable results -21.5<sup>7</sup>, ML from squamous cell carcinomas has been found to be inhomogeneous<sup>10,14,15</sup>.

In our study, central well defined hilum was seen in 13.11% of malignant nodes. It was deformed or distorted in 21.31% of malignant nodes. The hilum was not at all visualized in 65.57% of malignant nodes (Figure 1a). Although the linear echogenic hilum is a manifestation of the normal internal anatomy of the node, it may still be possible to see the echogenic line in early malignancy. As the malignant infiltration progresses the node increases in size and the likelihood of seeing the echogenic line decreases<sup>13,16</sup>. Other studies have found various results with absence of hilum being reported in 70-87 % of metastatic nodes<sup>6,7,8,11</sup> as well as 40-48% of malignant nodes<sup>17</sup>.

Intranodal necrosis was seen in 39.34% of ML cases as shown in Figure 1a. It has also been reported by other researchers<sup>7,8</sup>.

Intranodal calcific deposits were seen in 4.9 % of ML cases (Figure 1a). Although, metastatic tumoral calcifications are uncommon<sup>1</sup>, reported incidence range from only 1%<sup>8</sup> to none<sup>7</sup>.

Posterior enhancement has been reported in 10-45% of ML cases<sup>6,7,8</sup>. In our study it was seen in 52.45% of cases of ML.

In our study the nodal borders were sharp and intact in 85.25% of malignant nodes. It has been suggested that benign nodes have smooth, uniform walls. Unsharp or poorly defined borders suggest extranodal spread<sup>1</sup>. Sharp borders in ML

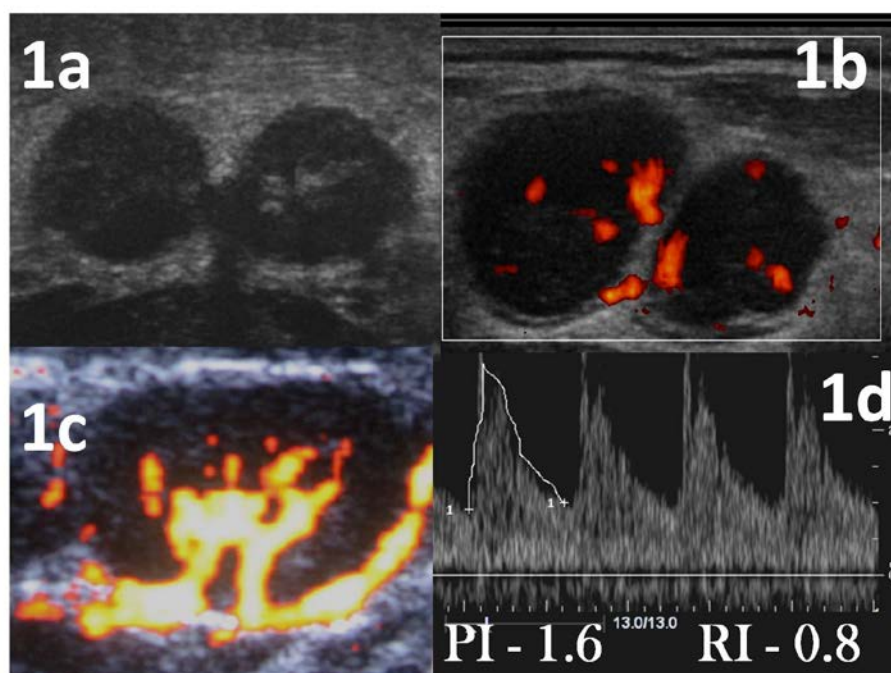
have been reported in 74 - 98.35 %<sup>6,7</sup>. Extranodal nodal extension is seen as irregular border with infiltration of adjacent fat plane<sup>12</sup>. The extranodal spread of metastatic lymph node diseases is seen as poorly defined borders, and irregularity of the nodal rim and infiltration of adjacent fat planes. One should look for tumor extension to the adjacent vessels, soft tissues and bones.

Surrounding edema was seen in 1.6% of malignant cases and has been reported in around 4% of metastatic nodes<sup>7</sup>.

**The Perfusion Pattern:** Metastases show peripheral (63.33%) and only central (13.33%) pattern more commonly as demonstrated in Figure 1b and 1c. A predominant peripheral perfusion has been reported in ML<sup>9,15</sup> and both central and peripheral pattern was seen in only 12% of cases. It has been observed that 90% of metastatic nodes showed vascularity which was spotted (26%), peripheral (11%) or mixed (53%) by other researchers<sup>14</sup>.

**The Perfusion Intensity:** In the present study ML showed hypointense perfusion intensity in 70% and isointense in 30%. It has been quoted that 68.29 of metastases showed hypointense pattern and 21.95% showed isointense pattern in other studies<sup>9,15</sup>. Thus there appears to be a clear correlation between tumor angiogenesis and nodal metastases.

**The Resistance to Perfusion :-**In our study most of the ML had the mean PI value of > 1.4 (? 30%), and the mean RI value of the > 0.7 (73.33 %) as shown in Figure 1d. It has been found by using a PI threshold of 1.6 and RI of 0.8, differentiation between reactive nodal enlargement and metastases was possible with an accuracy of 96% [9, 15]. A PI > 1.1 and RI >0.7 was 89% sensitive and 87% specific in differentiating between Metastatic and Benign lymphadenopathy<sup>14</sup>. It has been found that nodes involved with metastases showed a characteristic high (>1) RI and a high (>1.5) PI<sup>18</sup>.



**Figure 1.** **1a-** Gray Scale appearance of metastatic lymph node. Round shape suggestive of Roundness Index <2, sharp borders, No hilum and intranodal calcification.

**1b-**Color Doppler showing central and peripheral vascularity pattern

**1c-** Doppler ultrasound showing central pattern in a metastatic node.

**1d-** Spectral Doppler pattern showing increased PI and RI in a metastatic node.

Thus a systematic evaluation of enlarged lymph nodes with the above described ultrasound criteria can correctly diagnose ML with a sensitivity of 85.25 % and a specificity of 98.36%. Apart from this diagnostic accuracy, non invasive, radiation free and portable attributes of ultrasound ensure that it remains a highly acceptable imaging tool in the hands of the experts involved in managing the ML.

## REFERENCES

1. Som P. Lymph Nodes of the Neck. Radiology. 1987;165:593-600.
2. Stevens A, Lowe J. Human Histology-Immune System. 1997; 2: 117-35.
3. Arey LB. Human Histology-The Lymph Nodes. 1974; 41: 148-51.
4. Ross MM, Romrell LJ, Kaye GI. Histology –A text and Atlas-Lymph Nodes. 1995; 3: 342-6.
5. DePena CA, Tassel PV, Lee YA. Lymphoma of Head and Neck. Radiologic Clinics of North America.1990; 28:723-43.
6. Ahuja A, Ying M, Yang T et al. The Use of Sonography in Differentiating Cervical Lymphomatous Lymph Nodes from Cervical Metastatic Lymph Nodes. Clinical Radiology. 1996; 51:186-90.
7. Ying M, Ahuja AT, Evans R et al. Cervical Lymphadenopathy: Sonographic Differentiation between Tuberculous Nodes and Nodal Metastases from Non-Head and Neck Carcinomas. Journal of Clinical Ultrasound. 1998; 8: 383-89.

8. Ahuja A, Ying M., Evans R et al. The Application of Ultrasound Criteria for Malignancy in Differentiating Tuberculous Cervical Adenitis from Metastatic Nasopharyngeal Carcinoma. *Clinical Radiology*. 1995;50: 391-5.
9. Steinkemp HJ, Maurer J, Cornebl M, Recurrent Cervical Lymphadenopathy: Differential diagnosis with color-duplex sonography. *Eur Arch Otorhinolaryngol*. 1994; 251: 404-9.
10. Koischwitz D, Gritzmann D. Ultrasound Of The Neck. *Radiologic Clinics Of North America*. 2000;38: 1029-45.
11. Na CG, Lim AK, Byun GS et al. Differential diagnosis of Cervical Lymphadenopathy: Usefulness of Color Doppler Sonography. *The American Journal of Radiology*. 1997;168:1311-6.
12. Sakai O, Curtin H, Romo LV et al. Lymph Node Pathology Benign Proliferative, Lymphoma, And Metastatic Disease. *Radiological Clinics of North America*. 2000;38:979-98.
13. Gritzmann N, Hollerweger A, Macheiner P et al. Sonography of Soft Tissue Masses of the Neck. *Journal of Clinical Ultrasound*. 2002;30:356-73.
14. Wu, Chang, Hsu et al. Usefulness of Doppler Spectral Analysis and Power Doppler Sonography in the differentiation of cervical Lymphadenopathies. *American Journal of Roentgenology*. 1998; 171:503-9.
15. Steinkemp HJ, Mueffelmann M, Bock JC et al. Differential diagnosis of lymph node lesions: a semi quantitative approach with color Doppler ultrasound. *The British Journal of Radiology*. 1998;71: 828-33.
16. Evans RM, Ahuja A, Meterweli C. The Linear Echogenic Hilus in Cervical Lymphadenopathy- A Sign of Benignity or Malignancy. *Clinical Radiology*. 1993; 47: 262-4.
17. Vassallo P, Wernecke K, Roos N et al. Differentiation of Benign from Malignant Superficial Lymphadenopathy: The Role of High -Resolution US. *Radiology*. 1992;183: 215-20.
18. Choi M Y ,Lee JW,Jang KJ. Distinction between Benign and Malignant causes of Cervical, Axillary and Inguinal Lymphadenopathy: Value of Doppler Spectral Waveform Analysis. 1995;165: 981-4

**Yazışma Adresi / Address for Correspondence:**

Dr. Sushil Ghanshyam Kachewar  
Rural Medical College  
PIMS (DU), Loni,  
Maharashtra, INDIA-413 736

geliş tarihi/received :24.10.2012

kabul tarihi/accepted:20.11.2012