



Interpretation of Chest Radiographs in Both Cancer and Other Critical Care Patients with Acute Respiratory Distress Syndrome

Akut Solunum Sıkıntısı Sendromlu Kanser ve Diğer Yoğun Bakım Hastalarında Akciğer Grafilerinin Yorumlanması

Sema Yılmaz¹, Özden Ozgür Horoz², Süreyya Soyupak³, Fatih Erbey⁴, Ibrahim Bayram⁵, Dincer Yildizdas²

¹Ondokuz Mayıs University Faculty of Medicine, Department of Pediatric Hematology/Oncology, SAMSUN
²Cukurova University Faculty of Medicine, Department of Pediatric Intensive Care Unit, ³Department of Radiology, ⁵Department of Pediatric Hematology/Oncology, ADANA
⁴Medical Park, Bone Marrow Transplantation Unit, ISTANBUL

Çukurova Üniversitesi Tıp Fakültesi Dergisi (Cukurova Medical Journal) 2013; 38 (2):270-273.

ABSTRACT

Acute respiratory distress syndrome is a clinical, pathophysiological and radiographic pattern that has signs of pulmonary edema occur without elevated pulmonary venous pressures. Clinical presentation and progression of acute respiratory distress syndrome are followed by frequently ordered portable chest radiography in critically ill patients. We evaluated chest radiographs of ten cancer and other six critical care pediatric patients. The parenchymal imaging of lung in patients with cancer was reported the same as that of other critically ill children despite underlying pathophysiological variations in our investigation.

Key Words: Acute respiratory distress syndrome, chest X-Ray, cancer, critically care patient

ÖZET

Akut solunum sıkıntısı sendromu pulmoner venöz basınç artmaksızın pulmoner ödem bulgularına sahip klinik, patofizyolojik ve radyolojik paterni olan bir durumdur. Kritik hastalarda akut solunum sıkıntısı sendromunun klinik sunumu ve gidişi sıklıkla taşınabilir akciğer grafi istenerek takip edilir. Biz 10 kanser ve diğer 6 yoğun bakım çocuk hastalarının akciğer grafilerini inceledik. Araştırmamızda altta yatan patofizyolojik farklılıklara rağmen, kanser hastalarında akciğerin parankimal görüntülemesi diğer kritik hastalarinki ile aynı olarak rapor edildi.

Anahtar Kelimeler: Akut solunum sıkıntısı sendromu, göğüs grafisi, kanser, kritik olarak bakım hastası

INTRODUCTION

The acute respiratory distress syndrome (ARDS) is characterized by diffuse inflammation of the lung's alveolar-capillary membrane in response to various pulmonary and extrapulmonary insults. Pulmonary injury is

occured by directly gastric aspiration, pneumonia, inhalational injury, pulmonary contusion or indirectly sepsis, trauma, pancreatitis, multiple transfusions of blood products mechanisms¹. Clinical presentation and progression of ARDS are followed by frequently ordered portable chest radiography in the intensive care unit². The chest

X-ray (CXR) may initially appear normal. Interstitial perihilar edema is presented within 24 to 36 hours. Over the next 24 to 48 hours, the typical patchy alveolar opacities with air bronchogram then to more confluent, diffuse bilateral airspace opacities are seen on CXR³. In the following graphs, the opacities tend to modify little over time, the doubt of a complication such as aspiration, pneumonia, fluid overload, or a superimposed cardiogenic pulmonary edema are raised. ARDS represents a form of noncardiogenic pulmonary edema⁴. Although clinical and pathophysiological findings are common to all various origins of the syndrome, the question can come to mind whether the sequence of radiological events could be more different in pediatric cancer patients than that of other critically ill children.

Chest radiographs of ten cancer (6 boys and 4 girls) and other six critical care pediatric patients (5 boys and 1 girl) were evaluated. Underlying diseases in ten patients (non-Hodgkin lymphoma

(NHL) in three, leukemia in four, histiocytosis in one, osteosarcoma in one and rabdomyosarcoma in one) were associated with sepsis or pneumonia leading to ARDS. Only that of two patients (rabdomyosarcoma and one of NHL patients) survived. Six patients diagnosed with sepsis, gastroenteritis, metabolic disease, pneumonia and immunodeficiency. One of them survived. The pediatric radiologist did not know which diseases were responsible for radiographic findings in patients. The time of onset and duration of diffuse pulmonary changes of ARDS were interpreted on chest radiographs of all patients. Bilateral pulmonary infiltrates were seen on CXRs in patients with ARDS. After evaluation of CXRs by a pediatric radiologist, parenchymal imaging of lung are reported the same as that of other critically ill children. Underlying diseases and radiological appearance after 24 to 48 hours were shown in some of patients with ARDS (Figure 1).

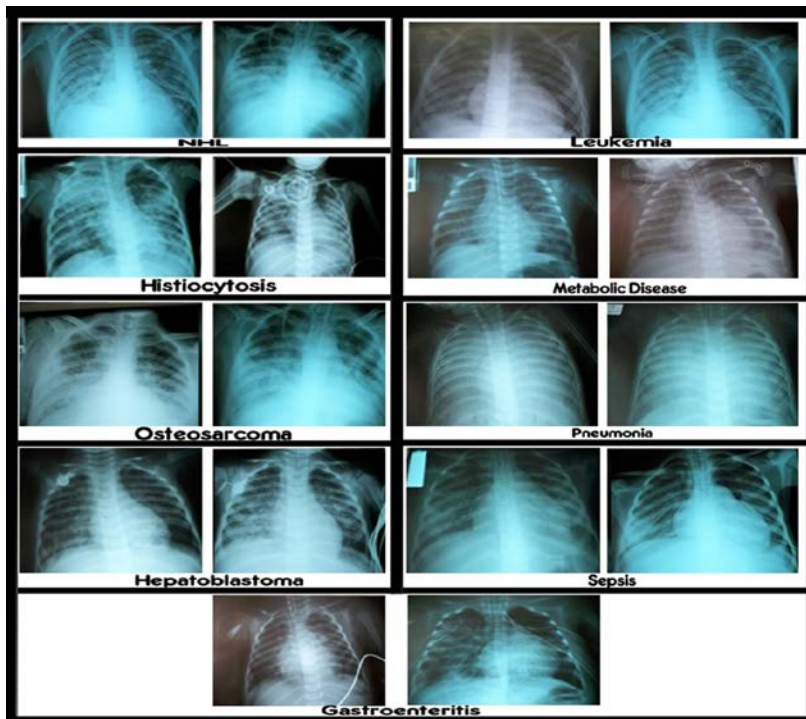


Figure 1. Underlying diseases and radiological appearance of some patients at the beginning of respiratory distress and after 24 to 48 hours.

Bedside portable chest radiography is extremely valuable in helping detect pulmonary abnormalities, particularly pneumonia in cancer and critically ill children in the pediatric intensive care unit. The common appearance of chest radiograph is diffuse bilateral and confluent air-space opacification involving the whole lung reflecting of increasing permeability of the endothelial and epithelial barriers in ARDS patients⁽³⁾. The point of origin in our investigation is to detect any difference in terms of pulmonary findings between cancer and other critically ill children with ARDS on chest radiographs. The same radiologic findings were reported in our children irrespective of underlying disease. Interpreting chest radiographs of leukemia patients with ARDS are presented in some studies, Not only pulmonary infiltration of leukemic cells but also chemotherapy can cause ARDS due to hemorrhage or alveolar damage related to leukemic cell lysis^{5,6}. The radiographic appearance of pulmonary leukemic infiltrates are normal in appearance, focal homogeneous opacities, diffuse reticulonodular infiltration, or ground glass like alveolar type filling opacities⁷. Winer-Murram et al. revealed that diffuse opacification was seen in radiographs of leukemia patients².

Different radiologic features were not detected significantly in both patient group despite underlying pathophysiological variations in our investigation. Yet we found no data about primary malignancy itself, myelosuppressive chemotherapy and radiotherapy create more complex pulmonary radiographic abnormalities in cancer children with ARDS in literatures. Besides we had few patient series, the other limitation of this investigation is to exist only one pediatric radiologist in our hospital. Even the specific radiographic appearance of ARDS did not change

in both patient group, the first occurring time of symptoms, severity of disease, monitoring of a response to therapy and identification of the development of pulmonary complications could be different in cancer patients. Some clues of imaging on chest radiograph would help the management of cancer children with ARDS. Therefore radiologists should guide physicians effectively in the following up the cancer children with ARDS in the pediatric intensive care unit.

Meeting presentation: This study was presented as a poster presentation in TPOG, 18-22 Mayıs, 2010, Samsun and SIOP, 22-24 Ekim, 2010, Boston.

REFERENCES

1. Ware LB, Matthay MA. The acute respiratory distress syndrome. *New Engl J Med.* 2000; 342: 1334-49.
2. Winer-Muram HT, Rubin SA, Fletcher BD, Kauffman WM, Jennings SG, Arheart KL, et al. Childhood leukemia: diagnostic accuracy of bedside chest radiography for severe pulmonary complications. *Radiology.* 1994; 193:127-33.
3. Henschke CI, Yankelevitz DF, Wand A, Davis SD, Shiao M. Chest radiography in the ICU. *Clin Imaging.* 1997; 21:90-3.
4. Maffessanti M, Berlot G, Bortolotto P. Chest roentgenology in the intensive care unit: an overview. *Eur Radiol.* 1998; 8:69-8.
5. Hewlett RI, Wilson AF. Adult respiratory distress syndrome (ARDS) following aggressive management of extensive acute lymphoblastic leukemia. *Cancer.* 1977; 39:2422-5.
6. Tryka AF, Godleski JJ, Fanta CH. Leukemic cell lysis pneumonopathy. A complication of treated myeloblastic leukemia. *Cancer.* 1982; 50:2763-70.
7. Wu YK, Huang YC, Huang SF, Huang CC, Tsai YH. Acute respiratory distress syndrome caused by leukemic infiltration of the lung. *J Formos Med Assoc.* 2008; 107:419-23

Yazışma Adresi / Address for Correspondence:

Dr. Sema Yılmaz

Ondokuzmayıs University Faculty of Medicine

Department of Pediatric Hematology/Oncology

55220 Atakum/ SAMSUN

Tel: 0362 457 6070

Fax: 0362 457 6041

geliş tarihi/received : 24.10.2012

kabul tarihi/accepted:21.08.2012