



### Footdrop: An Unexpected Complication After Anterior Cervical Discectomy and Fusion Operation

Anterior Servikal Diskektomi ve Füzyon Ameliyatı Sonrası Beklenmeyen Bir Komplikasyon: Düşük Ayak

Nuri Eralp Çetinalp<sup>1</sup>, Kerem Mazhar Özsoy<sup>1</sup>, Sibel Çetinalp<sup>2</sup>, Rafet Özyay<sup>3</sup>

<sup>1</sup>Çukurova University Faculty of Medicine Department of Neurosurgery, ADANA

<sup>2</sup>Adana Numune Training and Research Hospital Department of Anaesthesiology and Reanimation. ADANA

<sup>3</sup>Ankara Dışkapı Training and Research Hospital Department of Neurosurgery. ANKARA

*Cukurova Medical Journal 2015;40(1):147-150.*

#### ABSTRACT

Among the various postoperative complications of anterior cervical discectomy and fusion (ACDF) operation, common peroneal nerve (CPN) palsy is a rare one. In this report we present a 47 years old, female patient who suffered from foot drop postoperatively after an ACDF operation performed in supine position and discuss the medicolegal implications of intraoperative nerve injuries in the light of the foregoing literature. CPN palsy due to intraoperative positioning in neurosurgical practice is very seldomly reported. CPN palsy occurrence should be anticipated and prevented especially in the presence of the risk factors. There is still a serious need for a more comprehensive understanding of these risk factors. On the other hand intraoperative nerve injuries are becoming a subject of litigation more frequently. The interdisciplinary responsibilities concerning the positioning must be clearly defined and it is essential that the documentation of positioning is carried out as accurately as possible.

**Key words:** Anterior cervical discectomy, common peroneal nerve, palsy, intraoperative positioning

#### ÖZET

Ameliyat pozisyonuna bağlı peroneal sinir hasarı, nöroşirürji pratiğinde nadir olarak bildirilmiştir. Özellikle risk faktörlerinin varlığında, intraoperatif sinir hasarı gelişebileceği öngörülmeli ve gerekli önlemler alınmalıdır. Hastanın ameliyat pozisyonu ile ilgili disiplinler arası sorumluluk paylaşımının net olarak belirlenmesi ve ameliyat öncesi hazırlıklar dahil olmak üzere, ameliyathanede yapılan her işlemin detaylı olarak dokümanite edilmesi çok önemlidir. Bu makalede, supin pozisyonda gerçekleştirilen ASDF ameliyatından sonra düşük ayak gelişen, 47 yaşında bir kadın hastayı sunuyor ve intraoperatif sinir yaralanmalarının medikolegal yönlerini güncel literatür eşliğinde tartışıyoruz.

**Anahtar kelimeler:** Anterior servikal diskektomi, peroneal sinir, paralizi, intraoperatif pozisyon

#### INTRODUCTION

Anterior cervical discectomy and fusion (ACDF) operations are commonly performed in daily spinal surgical practice. It's reported that between 1990 and 1999, more than 500 000 ASDF operations were performed in USA<sup>1</sup>. Among the

various postoperative complications of ACDF operation, peripheral nerve injuries related to the intraoperative positioning have been reported very rarely in neurosurgical practice so the true incidence remains unclear. A review of the literature found just one case report describing

common peroneal nerve palsy due to surgical positioning after ACDF operation<sup>2</sup>. In this report we describe a common peroneal nerve (CPN) palsy, in our opinion which is facilitated by dislipidemia, after an anterior cervical discectomy operation and discuss the medicolegal implications of intraoperative nerve injuries in the light of the foregoing literature.

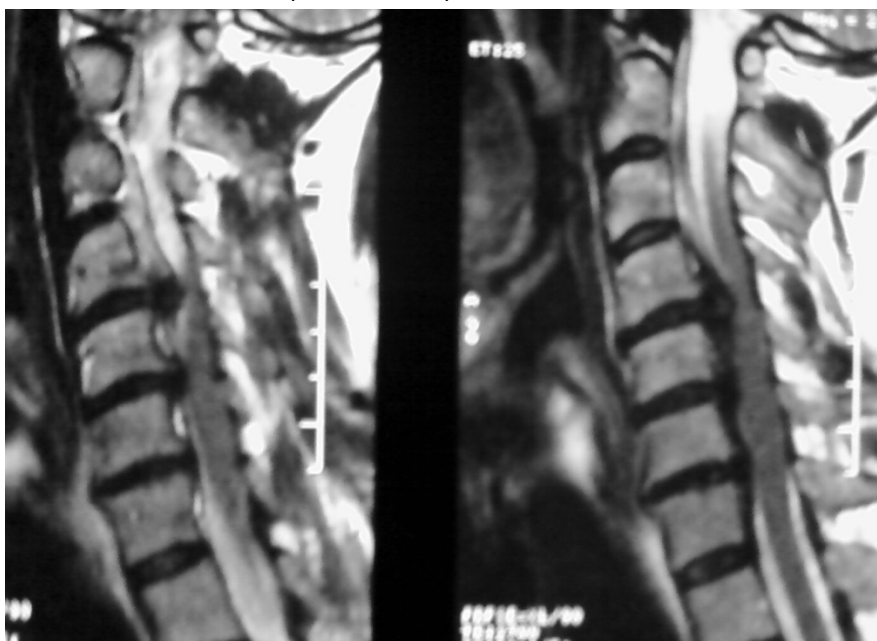### CASE REPORT

A 47 years old female and obese patient presented with neck and radiating left arm pain also complained about deterioration in fine motor skills in her both hands such as difficulty in handwriting and buttoning her shirts.

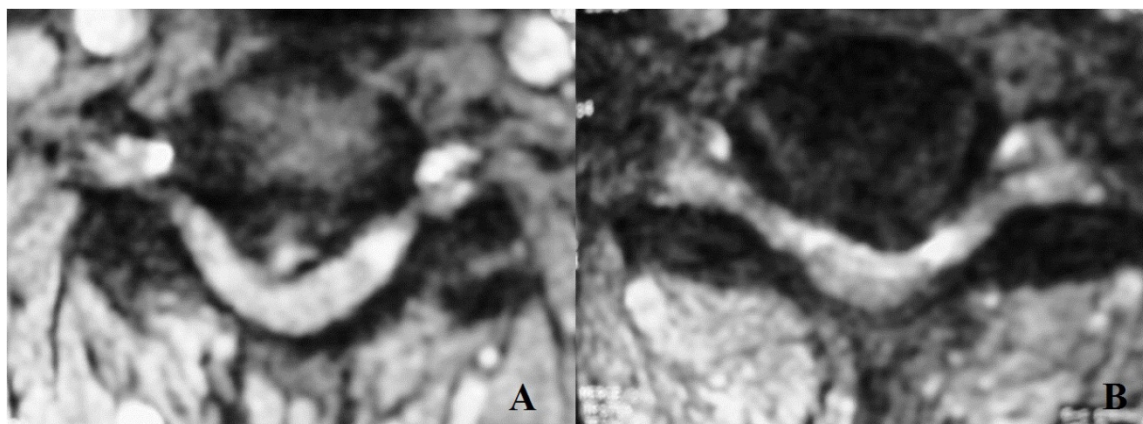
Her neurologic examination revealed a 20 % loss of biceps and deltoid muscle strengths. Hoffmann's signs were positive bilaterally. Her cervical MRI revealed multilevel disc herniations at C4-5 , C5-6 and C6-7 and multiple spondylotic cord compression (Fig 1 and Fig 2A and B). Her body mass index was within the obesity levels and triglyceride levels were above 320 mg/dl. The patient underwent an ACDF operation with peak

cages and plate fixation in supine position under general anaesthesia and 3 levels anterior discectomy was performed. In the postoperative checks a left foot drop was diagnosed. She had no back or leg pain. On detailed neurological examination she had no pathological reflexes or upper motor neuron signs so a left CPN palsy due to the operation positioning was suspected. She had no recovery during her hospitalization course and discharged after 3 days with a foot orthosis and referred to a physical therapy and rehabilitation clinique.

Electromyographic test, performed 3 weeks after discharge, revealed a delay in distal latency of left CPN and denervation potentials of tibialis anterior and peroneus longus muscles were recorded. The test confirmed a CPN injury at fibular head. The EMG at 3 months check showed similar results. After continuous physical therapies and exercises during 6 months, dorsiflexion of the left foot was improved to 3/5 strength. Her motor strength recovered totally 1 year after the operation except the sensation loss of the foot dorsum.



**Figure 1.** Sagittal T2-weighted MR image revealed a hypo intense signal posterior to vertebral body margin and disc herniations at C4-5 and C5-6 levels



**Figure 2.** (A) Axial T2 weighted MR image at the level of C4-5 revealed a right paracentral disc herniation. (B) Axial T2 weighted MR image revealed a C5-6 left paracentral disc herniation and cord compression can be seen in both images

## DISCUSSION

Common peroneal nerve palsy is a well described complication following surgeries performed in lithotomy position like gynecologic and colorectal procedures<sup>3</sup>. Though CPN palsies are reported after the neurosurgical operations performed in sitting position, it is very rare in supine positioned procedures especially after ACDF operations.<sup>[4]</sup> In the literature we could find just one case of a CPN palsy after anterior cervical discectomy operation which is reported by Yi et al<sup>2</sup>.

The pathophysiological mechanisms of CPN palsy include stretch, ischemia and/or compression of the nerve which causes an interruption of the blood supply of the nerve or tear in the intraneural connective tissue. Although we don't know the exact mechanism of the injury, some facilitating factors can be blamed in our case. Albeit CPN compression in the supine position is not anticipated, the tilting of the operating table sideways for better visualization of the foramina may cause a CPN compression at the fibular head. Besides, even though our patient did not have a slender body shape, the other factors that Johnson et al depicted, such as immobilization during external rotation of the knee and operation time about more than 3,5 hours may have played a role in producing CPN palsy<sup>5</sup>. Entrapment of the nerve mostly occurs on the lateral side of the knee where the nerve traverses the fibular head and runs more

superficially. Lack of the padding fat tissue in the slender body shaped patients is a facilitating factor for the nerve entrapment. Contrary to this, we believe that obesity and related diabetes may contribute to the process, as a predisposing factor in a different way. It is known that hyperglycemia due to insulin resistance triggers systemic and neuronal oxidative stress; and leads to peripheral nerve injury<sup>6</sup>. Although DM is not the case in our patient, dyslipidemia may be the point to be discussed. Some studies suggest that a high-fat diet produces neuropathy independent of hyperglycemia<sup>7</sup>. Development of neuropathy before hyperglycemia formation was shown with electrophysiological parameters in mice on a high-fat diet.<sup>[8]</sup> Furthermore in a prospective study with 6 patients, Mc Manis et al reported that increasing blood triglycerides are related with peripheral neuropathy.<sup>[9]</sup> Of course it is impossible to assert dyslipidemia as the primary cause, but we think that at least it can be speculated as a facilitating factor for the dysfunctionality of the entrapped nerve especially in such obese dyslipidemic patients.

Intraoperative positioning nerve injuries continue to occur despite adequate padding and preventive measures and, as a result, place the physician at risk for litigation. In a closed claim analysis, nerve injuries comprise 15-16 % of the claims.<sup>[10]</sup> Although, these incidents seem to be

anesthesia related injuries, as neurosurgeons, the point that we have to be aware of is, medicolegally, the surgeons, anesthesiologists, and nursing staff share responsibility for these injuries. Informed consent may play an important role in such situations but as Yi et al's case, our preoperatively obtained informed consent did not cover such a complication regarding to the patient's positioning<sup>2</sup>. As a suggestion the operating team should obtain a detailed informed consent and not just take standart precautions in the operating room but also document all on the operation files. After all there is still a serious need for a more comprehensive understanding of risk factors for intraoperative nerve injuries.

### REFERENCES

1. Angevine PD, Arons RR, McCormick PC. National and regional rates and variation of cervical discectomy with and without anterior fusion, 1990-1999. *Spine (Phila Pa 1976)*. 2003;28:931-9.
2. Yi HJ, Oh SH, Hong HJ, Lee KS. Common peroneal nerve palsy as a complication of anterior cervical operation: A case report. *Surg Neurol*. 2004;61:379-83.
3. Warner MA, Martin JT, Schroeder DR, Offord KP, Chute CG. Lower-extremity motor neuropathy associated with surgery performed on patients in a lithotomy position. *Anesthesiology*. 1994;81:6-12.
4. Keykha MM, Rosenberg H. Bilateral footdrop after craniotomy in the sitting position. *Anesthesiology*. 1979;51:163-4.
5. Johnson DS, Sharma DP, Bangash IH. Common peroneal nerve palsy following knee arthroscopy. *Arthroscopy*. 1999;15:773-4.
6. Tomlinson DR, Gardiner NJ. Glucose neurotoxicity. *Nat Rev Neurosci*. 2008;9:36-45.
7. Obrosova IG, Ilytska O, Lyzogubov VV, Pavlov IA, Mashtalir N, Nadler JL, et al. High-fat diet induced neuropathy of pre-diabetes and obesity: Effects of "healthy" diet and aldose reductase inhibition. *Diabetes*. 2007;56:2598-608.
8. Vincent AM, Hayes JM, McLean LL, Vivekanandan-Giri A, Pennathur S, Feldman EL. Dyslipidemia-induced neuropathy in mice: The role of oxldl/lox-1. *Diabetes*. 2009;58:2376-85.
9. McManis PG, Windebank AJ, Kiziltan M. Neuropathy associated with hyperlipidemia. *Neurology*. 1994;44:2185-6.
10. Cheney FW, Domino KB, Caplan RA, Posner KL. Nerve injury associated with anesthesia: A closed claims analysis. *Anesthesiology*. 1999;90:1062-9.

### Yazışma Adresi / Address for Correspondence:

Dr. Nuri Eralp Cetinalp  
Cukurova University Faculty of Medicine  
Department of Neurosurgery  
Email: necetinalp@cu.edu.tr

Geliş tarihi/Received on : 19.03.2014

Kabul tarihi/Accepted on : 21.04.2014