



Diffuse Large B Cell Lymphoma of the Breast

Memenin Diffüz Büyük B Hücreli Lenfoması

Feryal Karaca¹, Vehbi Erçolak², Çiğdem Usul Afşar², Meral Günaldı²

¹Cukurova University Medical Faculty, Department of Radiation Oncology, ²Medical Oncology, ADANA

Cukurova Medical Journal 2015;40(1):151-157.

ABSTRACT

Primary breast lymphoma is rarely encountered in Non-Hodgkin Lymphomas. However, if early diagnosis is made, and treatment is started immediately in patients with low grade and stage, patient survival is increased. 39-year old female patient applied us due to a palpable mass. She was diagnosed with the Non-Hodgkin Lymphoma Diffuse Large B Cell Lymphoma after the investigations. Curative external radiotherapy was applied after 6 courses of CHOP-R chemotherapy to the patient with Stage-IIE favorable, and B symptoms. After 48-month follow up, patient follow up is being continued without any progression, or recurrence or metastasis.

Key words: Breast lymphoma, Non-Hodgkin Lymphoma, Extranodal lymphoma, Diffuse Large B Cell Lymphoma

ÖZET

Primer meme lenfoması, Non Hodgkin Lenfomalar içinde nadir görülür. Ancak erken tanı konduğunda, grade ve evresi düşük olan hastalarda tedaviye zaman kaybetmeden başlandığında hastaların sürvisi artmaktadır. 39 yaşındaki bayan hastamız eline kitle gelmesi üzerine başvuruyor. Yapılan tetkikler sonucunda Non Hodgkin Lenfoma Diffüz Büyük B Hücreli Lenfoma olarak değerlendiriliyor. Evre-IIE favorabl, B semptomları olmayan hastaya 6 kür CHOP-R kemoterapi sonrasında küratif eksternal radyoterapi uygulanıyor. 48 aylık takipleri sonucunda hastada progresyon, nüks, metaztaz saptanmamış olarak takibe devam edilmektedir.

Anahtar kelimeler: Meme Lenfoma, Hodgkin Dışı Lenfoma, Ekstranodal Lenfoma, Difüz Büyük B Hücreli Lenfoma

INTRODUCTION

Breast lymphomas are generally not differentiated from primary breast cancer and benign fibroadenoma of the breast. Extranodal involvement is encountered commonly in 40% of lymphoma cases¹. Primary Breast Lymphomas (PBL) should be differentiated from secondarily metastasized, disseminated extranodal lymphomas. The differential diagnosis from extranodal disease is performed by being bulky and disseminated lymph nodes. Wiseman and Liao reported that four criteria were required for PML; performance of adequate and closely related pathological evaluation between breast tissue and

lymphomatous infiltrates; widespread disease or no evidence of previous extramammarian lymphoma evidence; and the breast tissue being the main region². Majority of them are B cell lymphoma; T cell lymphoma is rare, but more aggressive^{2,3}. Primary Diffuse Large B Cell Lymphoma (PDLBCL) is the most common type histologically among all breast lymphomas (approximately half of them).(1,4) PML constitutes only 1.7-2.2% of extranodal lymphomas^{2,4}. However, it constitutes only 0.04-0.5% of breast malignancies^{3,4}. PML is commonly encountered in women of 60-65 years of age. Breast lymphoma is probably originated from mucosa related lymphoid

cells (MALT), and it is spread to breast ducts, lobules, and intramammary lymph nodes from here^{1,2,4,5}. As there are small series related to PML, it's difficult to differentially diagnose the primary. Frequently, there is a tendency to be mixed with breast cancer in clinical and radiological diagnostic methods. The most common sign is enlargement and mass in the breast⁴. Patients are presented generally with unilateral, painless, breast masses, and the right breast is more commonly involved than the left breast. Approximately 5-13% of them are bilateral. Ipsilateral axillary lymph nodes have been encountered in 30-40% of the cases^{1-3,6}. Systemic B symptoms are not common^{1,7}. Giardini et al. showed that 5-year survival of patients were only 43%⁷. Surgery, radiotherapy, and chemotherapy alone or combined treatments can be tried as treatment modalities. However, validity of surgery is not more than for tissue diagnosis currently⁴.

CASE

39-year old female patient palpated a mass in her right breast, and she applied to the doctor. In her physical examination, no symptom other than a mass with the diameter of Original Manuscript (Anonymised) 3-4 cm in the right breast and lymphadenomas in the right axilla were defined. As the result of breast USG, a lesion with the diameter of 38x20 mm, hypoechoic, with indefinite borders was localized in the outer half middle/lower portion of the right breast; and a lesion with the diameter of 24x11 mm, which was primarily consistent with fibroadenoma, was detected in the left breast. A mass with the diameter of 3.5 cm, which had sparsely irregular, and microlobulated borders, and located in the lower part of the midline, was detected in the outer half of the right breast. After the contrast, type III, intense and rapid staining

was noted in the dynamic sequences. The right axillary lymphadenomas were graded as BI-RADS 5, and the lesion in the right breast was evaluated as BI-RADS 4; and then tru-cut biopsy was performed (Fig. 1). No additional pathology was detected in the upper-lower abdomen and thoracic CT examinations. It was reported in the first breast biopsy that malignant epithelial tumor was consistent with ductal carcinoma. However, the second biopsy sample from the mass was reported as NHL DGBCL. (Fig. 2). The results of immunohistochemical method were reported as CD20 (+), LCA (+) MUM(+), CK14(-), CD3 reactive T lymphocytes (+), CD5 reactive T lymphocytes (+).(Fig. 3,4). Intensely increased F-18 FDG involvement with the diameter of 4x4 cm and which was in favor of malignancy was observed in the outer quadrant of the right breast in PET CT examination (SUV max=19.5). Hypermetabolic lymph node was observed at the level of malignancy in the right axilla (SUV max=6.1). The bone marrow aspiration result was reported as normal hematopoiesis, and bone marrow biopsy was reported as normocellular. The patient without B symptoms was evaluated as stage IIE favorable primary breast lymphoma, and received 6 courses of CHOP-R chemotherapy. After the chemotherapy, curative radiotherapy at the dose of 17fxX180cGy=3060cGy was applied at two areas, to the right supraclavicular area and axilla via AP/PA. Curative radiotherapy at the dose of 17fxX180cGy=3060cGy was applied to a total of 4 areas, to medial/lateral and their segmental areas, in the right breast via IMRT treatment technique. After the treatment, no sign in favor of malignancy with F-18 FDG affinity was detected. After 48-month follow up, patient follow up is being continued without any progression, or recurrence or metastasis.

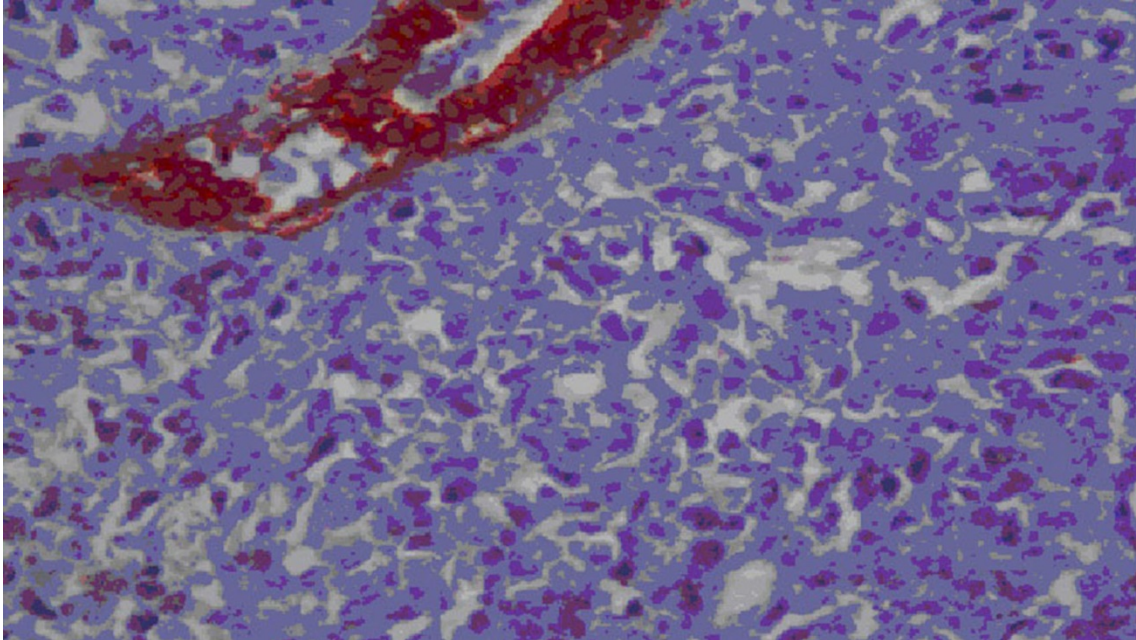


Figure 1. The mass with diameter of 3.5 cm and irregular microlobulated mass in the breast lymphoma observed in the breast MRI.

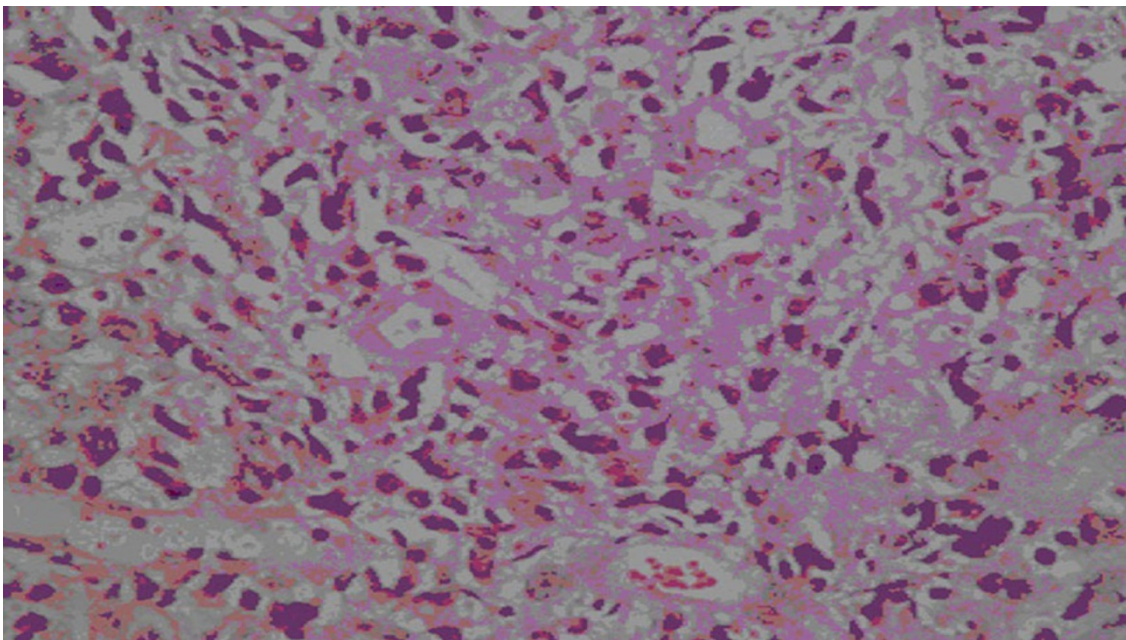


Figure 2. Cells with atypical monomorphic appearance, and with giant vesiculated nucleus are observed within the breast tissue. HE X 40.

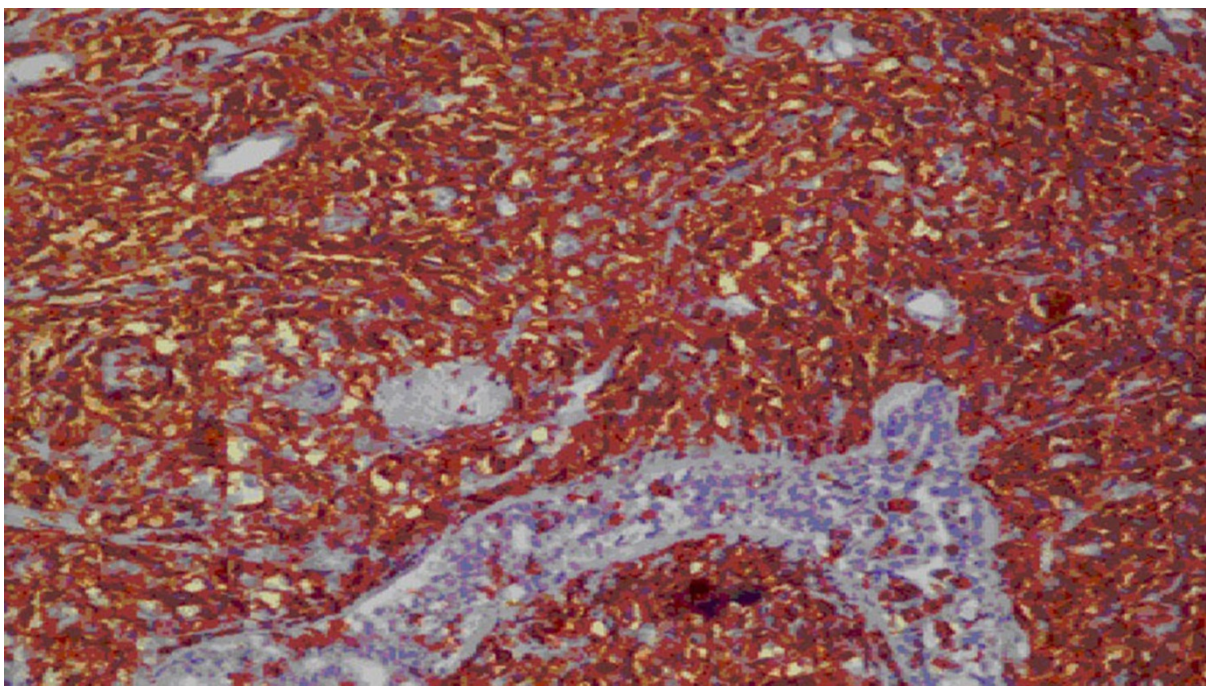


Figure 3. CD20 positivity (+) applied by immunohistochemical method. IHK CD 20 X20.

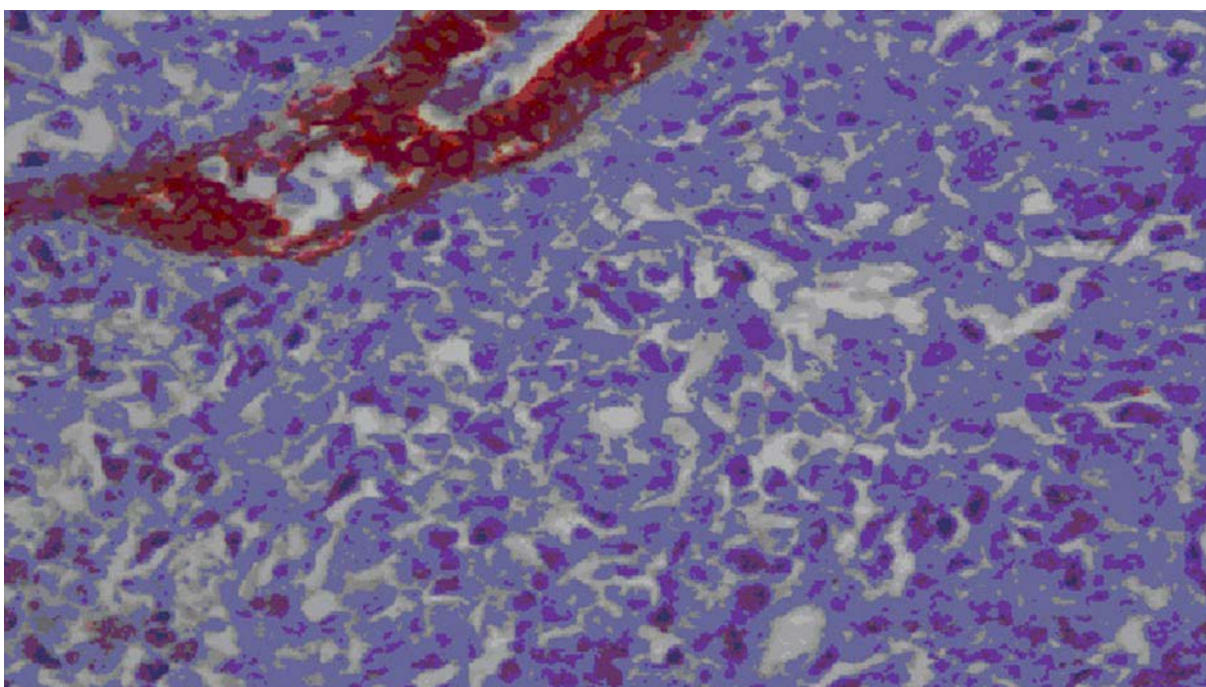


Figure 4. Keratin negative (-) applied by immunohistochemical method. IHK Keratin x 40.

DISCUSSION

Primary breast lymphomas are rarely encountered. Wiseman and Liao first defined the primary breast lymphoma in 1972. However, primary extranodal lymphoma criteria are defined according to local lymph node status and extranodal lesion at the time of diagnosis, which have been identified by International Extranodal Lymphoma Working Group^{1,2}. There is no radiological diagnostic sign. However, absence of desmoplastic reaction or calcification; diffusely increased density in the parenchyma with skin thickening indicate it. Differential diagnosis of NHL may also be performed by presence of miliary densities in the mammography⁸. Primary breast lymphomas present themselves generally by rapidly enlarging, painless masses^{4,9}. Chemotherapy and radiotherapy are the treatment approaches. In previous years, mastectomy ended up in good results primarily in patients with localized stage breast lymphomas, but distant metastasis rates were increased. As a result, surgery decreased only patient progression^{5,10}. Although mastectomy was very rarely performed, some papers reported that it decreased patient overall survival rate, whereas some other reported that it was of no use^{5,10,11}. Jennings et al. investigated treatments and survivals of 465 patients with primary breast lymphoma, of whom 53% had DGBCL, and the mean age of 54 (17-95) years. Patients were followed up for a mean duration of 48 (1-288) months. No benefit was provided in survival in patients treated by mastectomy. It was reported that radiotherapy was beneficial for both survival and recurrence in Stage I-node negative patients; and that chemotherapy was beneficial for both survival and recurrence in Stage II-node positive patients. Disease free survival is approximately 44.5% in all patients. As a result, it was predicted that mastectomy had no benefit in treatment; and radiotherapy and chemotherapy should be performed according to

nodal involvement for patients¹¹. Jeanneret-Sozzi et al. examined 84 patients with breast lymphoma. Of them, 21 patients had mastectomy; 39 had conservative surgery; and 23 patients were biopsied. Adjuvant treatments were applied in the majority of patients. Of patients, 37 received combined radiochemotherapy; 22 had only chemotherapy; and 14 had only radiotherapy. Only 11 patients did not receive adjuvant treatment after they were operated. While median radiotherapy dose was 40 Gy (12-55 Gy), CHOP or similar treatment regimen was given in 59 out of 84 patients (70%). The result of this treatment was local relapse in 12%; systemic relapse in 55%; and cranial relapse in 14% of patients. When 12 patients with cranial relapse were histologically examined, they were diagnosed with high grade lymphoma. While occurrence of systemic relapse developed with the mean of 22 (4-140) months; 5-year overall survival, lymphoma specific survival, disease free survival, and local control values were 53%, 59%, 41%, and 87% in the same order. According to this, Jeanneret-Sozzi et al. concluded that local control with radiotherapy or combined treatments caused excellent outcomes. They also decided that similar to cranial relapses systemic relapses were fewer⁴. Rayan et al. showed that cranial nervous system relapse was quite rare. Relapse was shown only in 5% of patients. This ratio was less than that of in primary testicular diffuse B cell lymphoma, so CNS prophylaxis is still debatable¹. Absence of prospective studies in this field, and CNS recurrence rate of around 12-27% suggested CNS prophylaxis strongly⁹. Aviles et al. gave radiotherapy at the dose of 45 Gy to 30 patients out of 96 breast lymphoma patients in a prospective study. They gave only chemotherapy (6x CHOP-21) to 32 patients. After they gave 6 courses of CHOP chemotherapy to 34 patients, they gave radiotherapy at the dose of 30 Gy. All patients were stage I or II according to Ann Arbor criteria. These early stage patients were followed up for 10 years, and 50 of patients had the overall

survival of 50-76%. Aviles et al. showed that the best response was given to the combined treatment. Complete response was reported in two patients who received the combined treatment⁹. The most commonly given chemotherapy regimen in the primary breast lymphoma is CHOP. When adjuvant radiotherapy is applied to patients, who have received doxorubicin, the cardiotoxicity rate is increased. Inclusion of rituximab into anthracycline based chemotherapy in DGBCL affected the survival in breast lymphoma with this histology as it was in the systemic lymphoma^{12,13}. Majority of patients with primary breast lymphoma have been presented in the Stage-I in Lin's study. Prognoses of Stage II patients were reported better when they received aggressive chemotherapy and radiotherapy¹⁴. According to Ann Arbor staging system, extranodal lymphoma determines reliably the patient prognosis. In different sources, it has been reported that evaluation of grade, staging should be performed to define the disease prognosis. Age, LDH level, tumor size, and bulky disease are also important for prognostic factors^{11,15}.

CONCLUSION

Primary breast lymphoma is rarely encountered. Treatment consensus related to primary breast lymphoma has not been clear yet. Combined chemotherapy regimens are being used alone or with radiotherapy according to histological type, prevalence and stage of the disease. Treatment response and disease prognosis as the result of individualized treatments are being estimated according to other extranodal lymphomas. Central nervous system prophylaxis is beneficial in cases with aggressively progressing lymphoma. Combined therapies are the best treatment options in early stage breast lymphoma cases. However, mastectomy is not recommended as it does not have positive effects on the survival or recurrence. Surgery should be preferred only for tissue diagnosis. There is no need for sentinel lymph node sampling; USG is adequate to define

lymph nodes in the axilla. However, sentinel lymph node sampling may be performed in patients with suspicious clinical examination and USG examination for better definition of the stage and also the treatment.

Conflict of Interest: None

Conflict of Interest Statement

We declare that we have no conflicts of interest.

REFERENCES

1. Ryan G, Martinelli G, Kuper-Hommel M, et al. Primary diffuse large B-cell lymphoma of the breast: prognostic factors and outcomes of a study by the International Extranodal Lymphoma Study Group. *Ann Oncol.* 2008;19:233-41.
2. Topalovski M, Crisan D, Mattson JC. Lymphoma of the breast. A clinicopathologic study of primary and secondary cases. *Arch Pathol Lab Med.* 1999;123:1208-18.
3. Aguilera NS, Tavassoli FA, Chu WS, Abbondanzo SL. T-cell lymphoma presenting in the breast: a histologic, immunophenotypic and molecular genetic study of four cases. *Mod Pathol;* 2000;13:599.
4. Jeanneret-Sozzi W, Taghian A, Epelbaum R, et al. Primary breast lymphoma: patient profile, outcome and prognostic factors. A multicentre Rare Cancer Network study. *BMC Cancer.* 2008;8:86.
5. Jennings WC, Baker RS, Murray SS et al. Primary breast lymphoma: the role of mastectomy and the importance of lymph node status. *Ann Surg.* 2007;245:784-9.
6. Schouten JT, Weese JL, Carbone PP. Lymphoma of the breast. *Ann Surg.* 1981;194:749.
7. Giardini R, Piccolo C, Rilke F. Primary non-Hodgkin's lymphomas of the female breast. *Cancer.* 1992;69:725-35.
8. Pameijer FA, Beijerinck D, Hoogenboom HH et al. Non-Hodgkin's lymphoma of the breast causing miliary densities on mammography. *AJR Am J Roentgenol.* 1995;164:609-10.
9. Avile's A, Delgado S, Nambo MJ, Neri N, Murillo E, Cleto S. Primary breast lymphoma: results of a controlled clinical trial. *Oncology.* 2005;69:256-60.

10. Vignot S, Ledoussal V, Nodiot P et al. Non-Hodgkin's lymphoma of the breast: a report of 19 cases and a review of the literature. *Clin Lymphoma*. 2005;6:37-42.
11. Talwalkar SS, Miranda RN, Valbuena JR, Routbort MJ, Martin AW, Medeiros LJ. (2008). Lymphomas involving the breast: a study of 106 cases comparing localized and disseminated neoplasms. *Am J Surg Pathol*. 2008;32:1299-309.
12. Miller TP, Dahlberg S, Cassady JR, et al. Chemotherapy alone compared with chemotherapy plus radiotherapy for localized intermediate- and high-grade non-Hodgkin's lymphoma. *N Engl J Med*. 1998;339:21-6.
13. Yhim HY, Kim JS, Kang HJ, Kim SJ, Kim WS, Choi CW, Eom HS, Kim JA, Lee JH, Won JH, Shim H, Huh J, Lee DH, Suh C, Kwak JY. Matched-pair analysis comparing the outcomes of primary breast and nodal diffuse large B-cell lymphoma in patients treated with rituximab plus chemotherapy. *Int J Cancer*. 2012;131:235-43.
14. Lin YC, Tsai CH, Wu JS, et al. Clinicopathologic features and treatment outcome of non-Hodgkin lymphoma of the breast—a review of 42 primary and secondary cases in Taiwanese patients. *Leuk Lymphoma*. 2009;50:918-24.
15. Lin Y, Guo XM, Shen KW, Wang JL, Jiang GL. Primary breast lymphoma: long-term treatment outcome and prognosis. *Leuk Lymphoma*. 2006;47:2102-9.

Yazışma Adresi / Address for Correspondence:

Dr. Vehbi Erçolak
Cukurova University Medical Faculty
Department of Medical Oncology,
ADANA
Email: vehbiercolak@hotmail.com

Geliş tarihi/Received on : 06.01.2014

Kabul tarihi/Accepted on: 14.02.2014