



### Infected Complex Odontoma: A Case Report

#### Enfekte Kompleks Odontoma: Olgu Sunumu

Shanthala Damodar<sup>1</sup>, Veena KM<sup>1</sup>, Laxmikanth Chatra<sup>1</sup>, Prashanth Shenai<sup>1</sup>, Prasanna Kumar Rao<sup>1</sup>, Rachana V Prabhu<sup>1</sup>, Tashika Kushraj<sup>1</sup>, Prathima Shetty<sup>1</sup>, Shaul Hameed<sup>1</sup>

<sup>1</sup>Department of Oral Medicine and Radiology, Yenepoya Dental College, Yenepoya University, Mangalore, Karnataka, India.

*Cukurova Medical Journal 2015;40(2):379-383.*

#### ABSTRACT

Odontoma represent a hamartomatous malformation. They are usually asymptomatic and are diagnosed on routine radiological examination. Infection of an odontome is very uncommon. Few cases of infected odontoma are reported in the literature. We report a special case of infected complex odontoma and perforation of the cheeks with a tooth impacted upon along with computed tomographic (CT) image. Thus, making the present case unusual.

**Key words:** Odontoma, hamartoma, computed tomography (CT).

#### ÖZET

Odontoma, hamartomatöz bir malformasyonu yansıtmaktadır. Bunlar genellikle asemptomatik olup, rutin radyolojik muayenede teşhis edilir. Odontoma enfeksiyonu çok nadirdir. Literatürde birkaç odontoma enfeksiyonu rapor edilmiştir. Kompleks odontoma enfeksiyonu ve yanaklarda gömülü olan diş perforasyonu bilgisayarlı tomografik görüntüyle rapor edilmiştir. Dolayısıyla bu durum sunulan vakanın sıradışı olmasına yol açmaktadır.

**Anahtar kelimeler:** Odontoma, Hamartomatöz, Bilgisayarlı Tomografi (BT)

#### INTRODUCTION

Odontomas are hamartomatous malformation. They are usually incidental radiographic findings in most of the cases. In 2005, World Health Organization (WHO) has classified odontomes into compound, complex & compound-complex odontomes. The WHO defines complex odontoma as malformation in which all dental tissues like enamel, dentin, cementum, and pulp arranged in a more or less disorderly pattern<sup>1</sup>. Complex odontoma formation arises from abnormalities occurring in the bud stage of development where excessive initiation leads to formation of uncoordinated cells crowded into one area.

Odontomes can also be: Intraosseous wherein odontomas occur inside the bone and may erupt into the oral cavity. Few cases of the erupted variety have been described in the literature<sup>2,3</sup>. Extraosseous or peripheral variety includes those in the soft tissue covering the tooth-bearing areas of the jaw. Odontomes can be of any size and rarely gets infected. When they are large & are in close proximity with vital structures imaging modality like Computed tomography (CT) plays an important role in diagnosis & management.

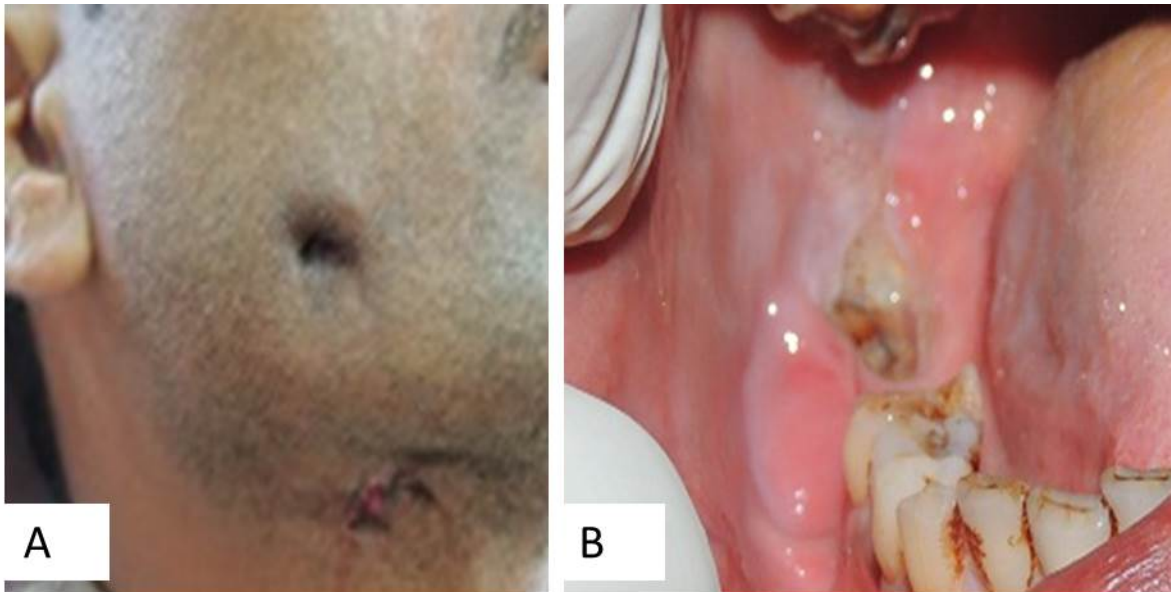
Thus we report a unique case of a large, infected complex odontome affecting mandibular ramus region.

**CASE REPORT**

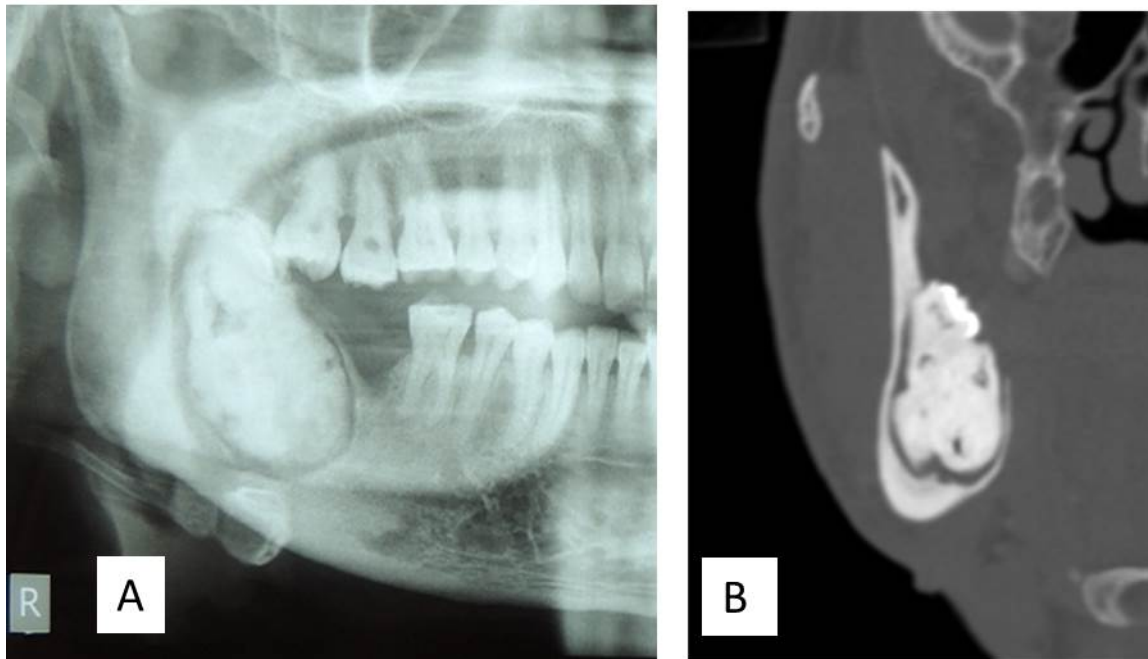
A 42 year old male patient reported to department with complaint of bleeding and pus discharge on right side of face associated with foul smell since 6 months. History of dull, intermittent, non-radiating pain along with low grade fever was reported thrice in 2 months associated with cough and throat infection. Patient also gave history of uneventful extraction of teeth on same side 5 years ago. On examination, multiple extra oral sinuses opening were seen on cheek and submandibular region along with bleeding and pus [Figure-1A]. Paresthesia was noticed around sinus opening. Submandibular and upper jugulo-digatric group of lymph nodes were palpable which was soft in consistency mobile and not fixed to underlying structures. Intraorally, diffuse solitary swelling was seen on buccal vestibule in relation to mandibular right molars. Impacted right mandibular molar with pus discharge and mild expansion of lingual cortical plate was noticed [Figure-1B]. Based on

history & clinical examination provisional diagnosis of chronic suppurative osteomyelitis and impacted right mandibular molar was given. Differential diagnosis of actinomycosis, dentoalveolar abscess and tubercular abscess was considered. Thereafter pus from sinus opening was sent for culture and sensitivity test. Pus culture showed coagulase negative staphylococci organisms. Panoramic radiograph [Figure-2A] was taken along with CT image [Figure-2B] which showed Hounsfield units equal to dental hard tissues.

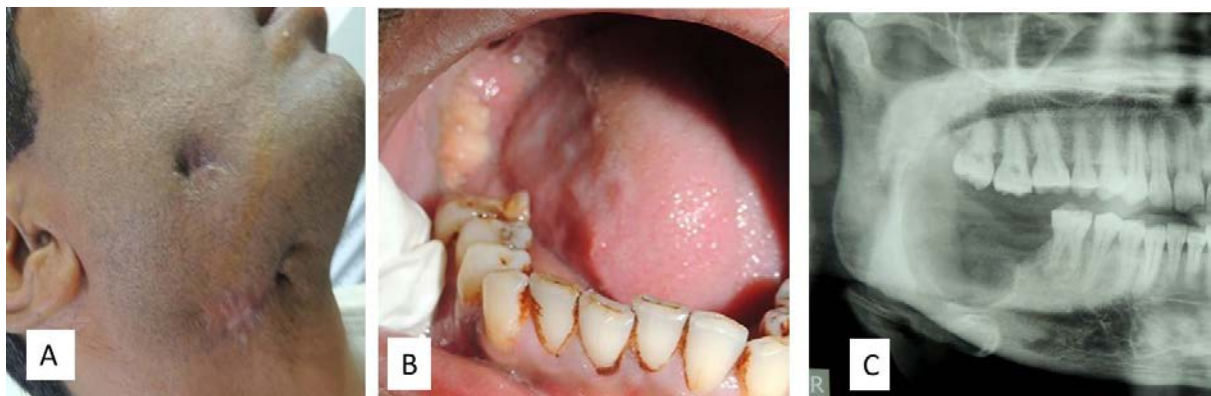Based on history and radiological findings, a diagnosis of infected complex odontome was given. Impacted tooth along with hard tissue was surgically excised and sent for histopathological investigation. Report showed varying proportions of enamel, dentin, cementum, and pulp tissue in a disorganized arrangement which confirmed our diagnosis. After 1 month, follow up showed healing of extra oral sinus & completely excised region in posterior mandible [Figure 3A, 3B & 3C].



**Figure 1. A-** Pre op showing extra oral sinus opening in relation to right side of face. **B-** Intra oral picture showing diffuse swelling in relation to buccal vestibule along with hard tissue distal to swelling which mimics bone.



**Figure 2.** **A-** Panoramic radiograph showing well- defined radio opacity seen in relation to right mandibular molar ramus region surrounded by radiolucent rim. **B-** Computed tomographic image in coronal section showing hyperdense areas seen mixed with few areas of hypodensity with Hounsfield units equal to dental hard tissues.



**Figure 3.** **A-** Post-operative extra oral picture showing healing of sinus opening. **B-** Post - operative intra oral picture. **C-** Post- operative radiograph showing complete removal of the radio opaque mass.

## DISCUSSION

The term odontoma was coined by Paul Broca in 1867. Odontomas are by definition hamartomas of odontogenic origin & are usually considered developmental anomalies and not neoplasms<sup>3</sup>. They are due to budding of extra odontogenic epithelial cells from the dental lamina. Etiology of occurrence of complex odontome after

induction of trauma to 1<sup>st</sup> molars has been reported<sup>4</sup>. Infections like rubella, treponema pallidum, pyogenic infection (splitting of tooth germ) can also be aetiology. Extraneous odontogenic epithelial cells wherein buds divide into various dental tissue based on transition in morphodifferentiation or histodifferentiation, detachment of portion of tooth germ from

hertwings epithelium or enamel organ is also considered<sup>5</sup>. Genetic changes like mutation in concerned gene, inheritance of abnormal gene, interference in mechanism of gene control tooth formation have been reported. Hitchin stated that the capacity of epithelium to go to cap stage and bell stage gets altered<sup>6</sup>.

Odontomes are asymptomatic. They are discovered at any age, although less than 10% are found in males over 40 years of age. Complex odontomas are less common than the compound variety in the ratio 1:2. They tend to occur in the posterior region, first and second permanent mandibular molars (70%). Our case did show male predilection and also mandibular posterior region. Clinical indicators of odontoma may include retention of deciduous teeth, non- eruption of permanent teeth, pain, expansion of the cortical bone and tooth displacement. The above mentioned features along with paraesthesia around sinus opening & pus discharge were present in our case. Severe cases of infection and regional lymphadenopathies have also been reported in many of the literature<sup>7</sup>. Our case also showed lymphadenopathy and infection. Case of erupting odontome attributes to only 3%<sup>8</sup>. The mechanism of odontome eruption is different from tooth eruption, which is mainly due to the lack of periodontal ligament in odontome. Therefore, the force required to move an odontoma is not linked to the contractility of fibroblasts. Although there is no root formation in odontoma, its increasing size may lead to the sequestration of the overlying bone and, hence, occlusal movement or eruption. The increase in the size of the odontoma over time produces a force sufficient to cause bone resorption. Erupting complex odontoma coronal to impacted second molar associated with dentigerous cyst<sup>9</sup>. However features of erupting odontome were not seen in our case. The eruption and infection of odontoma are uncommon. Few cases of erupted odontoma have been reported in the literature<sup>10,11</sup>. Two cases of complex odontomes with extra oral sinus, clinical

edentulous space & impacted permanent and deciduous teeth have also been reported<sup>12</sup>. In 2012, a case of a young female with recurrent infection associated with erupted odontoma in the second quadrant was reported<sup>13</sup>. All the above mentioned features of an infected complex odontomes were present in our patient along with paresthesia around the sinus opening and pus discharge due to which provisional diagnosis of chronic suppurative osteomyelitis was considered.

Well-defined radio opacity within the bone, calcified mass with the radiodensity of tooth structure which is also surrounded by a narrow radiolucent rim is its characteristic feature. The radiolucent zone is the connective tissue capsule of a normal tooth follicle. The thin sclerotic line resembles the corticated border seen in a normal tooth crypt. First, there is a resorption of bone, so the lesion is radiolucent. An intermediate stage then follows; because of the partial calcification of the odontogenic tissues, this stage is characterized by a radiolucent radiopaque image. This process continues to the most radiopaque stage, in which the calcification of the dental tissues is completed<sup>14</sup>. Characteristic features were seen in panoramic radiograph in our patient. Axial & coronal sections in computed tomography also showed characteristic appearance along with Hounsfield units of a tooth structure within hyperdense areas.

Surgical excision with regular radiological follow ups is the treatment of choice. Thus, mass was surgically excised along with impacted tooth and regular follow up was done.

## CONCLUSION

Although odontomes are asymptomatic and incidental radiographic finding, it can show signs of eruption into oral cavity associated with pain and infection which can lead to extra oral sinus opening. Even though it is a benign condition, a thorough clinical examination along with appropriate imaging modalities can provide us exact dimension and its proximity to surrounding

vital structures will help in complete surgical excision. Prognosis is excellent but regular follow up is also equally important.

### REFERENCES

1. Text book of differential diagnosis of oral and maxillofacial lesions, Norman K Wood and Paul W Goaz, 5<sup>th</sup> edition.
2. J Luis, Intraosseous odontoma erupted into the oral cavity: an unusual pathology. *Med Oral Patol Oral Cir Bucal*. 2005;10:248–51.
3. M Vengal et al. Large erupting complex odontoma. *JCDA*. 2007;73:169-73.
4. SE Shekar et al. Erupted compound odontome. *J Oral Maxillofac Pathol*. 2009;13:47–50.
5. Gokkulakrishnan et al, A rare case of complex odontome in 65year old lady. *Natl J of maxillofac surg* 2010;1: 67-70.
6. R M Kodali et al, An Unusual Complex Odontoma. *J of Maxillofac and Oral Surg*. 2010;9:314-7.
7. Gaurav Solanki et al, A case reporting odontoma. *Intern J of Biomed Research*. 2012;3:364-5.
8. BS Santosh, V Anuradha, MC Dayanand, Erupting Complex Odontoma: Coronal to Impacted Second Molar Associated with Dentigerous Cyst. *J Oral Health Comm Dent*. 2011;5:100-2.
9. Agrawal B, Gharote H, Nair P, Shrivastav S. Infected complex odontoma: an unusual presentation. *BMJ Case Reports*. 2012; doi: 10.1136/bcr-2012-006493.
10. Dua Nisha et al. An unusual case of erupted composite complex odontoma. *Journal of Dental Sciences and Research*. Vol. 2, (2): 1-5
11. Ferrer Ramírez MJ, Recurrent infection of a complex odontoma following eruption in the mouth. *Med Oral*. 2001;6:269-75.
12. Santosh P, D.N.S.V Ramesh, A. R Kalla, Complex odontoma: report of two unusual cases. *Braz J Oral Sci*. 2012;11:4.
13. Sulabha et al, Complex Odontoma Fused to Lower Wisdom Tooth an Unusual Case. *Journal of dental sciences and research*. 2012; 3:34-6.
14. Kulkarni VK, Odontomas--silent tormentors of teeth eruption, shedding and occlusion. *BMJ Case Rep*. 2012;14; pii: bcr2012007666, doi: 10.1136/bcr-2012-007666.

### Yazışma Adresi / Address for Correspondence:

Dr. Dr. Veena K M  
 Department of Oral Medicine and Radiology  
 Yenepoya Dental College  
 Yenepoya University  
 Deralakatte, Mangalore  
 Karnataka, INDIA  
 E-mail : veenaomr@rediffmail.com

Geliş tarihi/Received on : 19.03.2014

Kabul tarihi/Accepted on: 21.04.2014