



Cough Syncope due to ACE Inhibitor

ACE İnhibitörüne Bağlı Öksürük Senkopu

Filiz Koç¹, Mehmet Taylan Peköz², Hacer Bozdemir¹

¹Cukurova University Faculty of Medicine, Department of Neurology,-ADANA

²Adana Numune Education and Research Hospital, Department of Neurology, ADANA

Cukurova Medical Journal 2015;40(3):619-622.

ABSTRACT

Syncope is defined as a transient loss of consciousness due to sudden temporary decline in cerebral perfusion. Cough syncope is classically seen in middle aged obese men with obstructive pulmonary disease. In patients that use Angiotensin converting enzyme (ACE) inhibitors, a dry persistent cough can emerge due to the side effects of this medication. Seventy years old male patient that use ACE inhibitor for hypertension accepted to the clinic with the complaint of syncope. A bout of coughing has developed during electroencephalography recording and 10 seconds in duration of subcortical like epileptiform discharges were viewed. The ACE inhibitor the patient was receiving was replaced with calcium channel blocker and no complaint was observed during the follow up period.

Key words: ACE inhibitor, cough, syncope.

ÖZET

Senkop, serebral perfüzyonun aniden geçici olarak düşmesiyle ortaya çıkan geçici bilinç kaybı olarak tanımlanır. Obstrüktif akciğer hastalığı olan orta yaşlı obez erkeklerde öksürüğe bağlı senkop klasik olarak görülmektedir. Anjiyotensin konverting enzim (ACE) inhibitörü kullanan hastalarda bu ilacın yan etkisi olarak kalıcı kuru öksürük görülebilmektedir. Hipertansiyon tedavisi için ACE inhibitörü kullanan yetmiş yaşındaki erkek hasta senkop şikayeti ile kliniğe kabul edildi. Elektroensefalografi kaydı sırasında bir öksürük nöbeti gelişti ve süresi 10 saniye olan subkortikal benzeri epileptiform deşarjlar görüldü. Hastanın kullandığı ACE inhibitörü kalsiyum kanal blokörleri ile değiştirildiğinde takip periyodunda herhangi bir komplikasyona rastlanmadı.

Anahtar kelimeler: ACE inhibitörü, öksürük, senkop.

INTRODUCTION

Syncope is defined as a transient loss of consciousness due to sudden temporary decline in cerebral perfusion¹. Although dizziness, temporary blindness, aphasia or paralysis can be seen when there is local perfusion impairment in any area of the brain, syncope doesn't develop. The other two main features of syncope are its sudden onset and short duration. Cough syncope is classically seen in middle aged obese men with obstructive pulmonary disease. Syndrome is first defined by M.

Charcot in 1879 and is recognized as a type of epilepsy. However in 1940s it is concluded that in fact the syndrome is in nature of syncope².

One of the side effects of angiotensin converting enzyme (ACE) inhibitors that are commonly preferred in antihypertensive treatment recently is dry persistent chronic cough. It is seen as an average of 5-10%³. Non-dose dependent cough is more common in women. Neurokinin and prostaglandins play role in the etiopathogenesis. Cough complaint improves within 4 weeks of discontinuation of ACE inhibitor. In this article a

case with cough syncope due to ACE inhibitor use has been presented.

CASE

70 years old male patient accepted to our clinic with contractions in arms and legs and unconsciousness developed after bouts of coughing. From his medical history; he had complaints of numbness in the hands and arms, loss of consciousness and convulsions in whole body triggered with bouts of coughing, mean 4-5 times per week, sometimes bouts of coughing repeated for 2-3 times in a day approximately for four months, have been learned. It is reported that, he had hypertension for 3 years and has been using ACE inhibitors for 10 months; complaint of weakness of left side has developed five month ago and totally recovered in one week.

Neurologic examination; Cranial nerves are intact. There isn't any motor deficit. Sensorial and cerebellar findings are natural. Deep tendon reflexes are normoactive. Babinski is indifferent at

left. In the case that bouts of coughing developed during EEG monitoring, loss of consciousness and whole body generalized tonic convulsions were observed at this time. In simultaneous EEG recordings; subcortical epileptiform discharges with duration of 10 seconds were observed. Tracings were normal again after the when coughing attack recovered (Figure 1a-d). In cerebral magnetic resonance imaging; periventricular focal ischemia and atherosclerotic changes in cerebral angiography were detected. Electrocardiography was normal. Hypertensive changes were detected in Echocardiography. Holter ECG was normal.

Was accepted as cough syncope as the result of the performed tests and characteristics of the history. During the period that the case was followed in the clinic ACE inhibitor was replaced with calcium channel blocker. In the follow up period, coughing complaints of the case was decreased. In the polyclinic control performed one month later, coughing and the complaints due to coughing weren't existing.

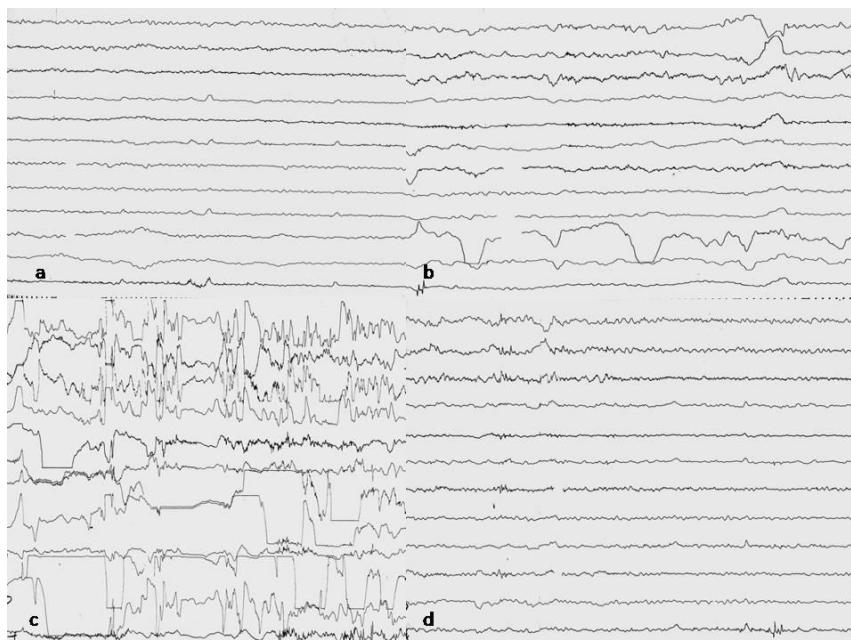


Figure 1a. before cough, b. during cough c. cough syncope d. after senkop

DISCUSSION

Syncope is a common symptom, its life-time prevalence is between 3% and 37% and consists 3% of emergency polyclinic admissions and 1% of other polyclinic admissions. It is seen in 40% of the population at least once in their lives⁴⁻⁸.

It can be difficult sometimes to distinguish syncope and the reasons of other transient unconsciousness. Etiologic evaluations can be categorized in three stages⁹. First stage performed during the attacks within the available facilities and includes history, detailed physical examination, electro physiologic and electro encephalic evaluations. Second stage includes head-up tilt test and provocative tests such as electro physiologic evaluations to produce a new attack. Third stage includes electro physiologic evaluations with long recordings to compare before and after attack periods.

The causes of syncope can be grouped in two main headings as cardiovascular and non-cardiovascular causes. Among the cardiovascular causes; arrhythmias such as sinus bradycardia, atrial-ventricular block, supraventricular and ventricular tachycardias; obstructive cardiac lesions such as aortic stenosis, hypertrophic cardiomyopathy, subvalvular web and mitral stenosis and vasomotor factors such as neural-cardiogenic (vasovagal), postural tachycardia syndrome, postural hypotension, carotid sinus hypersensitivity, situational syncope (urination, coughing, swallowing, etc.) can be counted. Among the non-cardiovascular causes; epilepsy, stroke, autonomic neuropathies and endocrinopathies such as hypoglycemia exist⁴⁻⁸.

Cough syncope which is one of the syncope causes; is almost always present following in the form of recurrent seizures of coughing, sometimes it can be seen after a strong cough^{4,5}. Although several theories are reported for the pathogenesis of cough syncope, the most commonly accepted one is that; insufficient amount of return of the venous blood to heart as a result of increase of intra thoracic pressure during

the coughing, decrease of cardiac output and systemic blood pressure. Thus the cerebral perfusion diminishes and results with syncope. In some cases, impairment of cerebral venous return causes cerebral hypo perfusion without decrease of systemic blood pressure. Hypoxia due to temporary airway obstruction, acute increase of cerebrovascular resistance during cough seizures and increase of cerebrospinal fluid pressure and reflex cardiac arrhythmias are the other causes proposed for physiopathology⁸⁻¹³. Syncope generally develops a few seconds after the start of coughing seizures. Unless the patient fall after 1-2 seconds and injured during fainting, can return to conscious state without any trace. Cough syncope is generally seen in middle aged obese men with obstructive pulmonary disease⁹⁻¹³.

There are many causes of chronic cough. The most common causes in non-smokers are; postnasal drip, gastro esophageal reflux, asthma, non-asthmatic eosinophilic bronchitis, viral infections, aspirin, beta blockers and medications such as ACE inhibitors. Treatment is the treatment of the etiological factors or discontinuation of the medication if it is due to drugs¹³. In our case, cough and syncope attacks after coughing have been developed following ACE inhibitor use for the medical treatment of hypertension and the attack has been confirmed both visually and electro physiologically during the electro encephalographic evaluation. Although cough syncope associated with ACE inhibitor, the other cardiac and non-cardiac concomitant causes were excluded by both clinic and laboratory findings including electro physiologic tests. In the case that ACE inhibitor was replaced with another group antihypertensive agent, calcium channel blocker, syncope attacks were observed not repeated in the follow up period.

Consequently, cough syncope is one of the rare clinical states. While the etiology of syncope was questioned, a detailed history should be taken, other causes of syncope should be ruled out and the medical treatment of the patient

particularly presence of ACE inhibitors should be questioned.

REFERENCES

1. Chung CP, Cheng CY, Zivadinov R, Chen WC, Sheng WY, Lee YC, Hu HH, Hsu HY, Yang KY. Jugular venous reflux and plasma endothelin-1 are associated with cough syncope: a case control pilot study; *BMC Neurol.* 2013;16;13:9.
2. Krediet CT, Wieling W, Edward P. Sharpey Schafer was right: evidence for systemic vasodilatation as a mechanism of hypotension incough syncope; *Eurpace.* 2008;10:486-8.
3. Omboni S, Borghi C. Zofenopril and incidence of cough: a review of published and unpublished data. *Ther Clin Risk Manag;* 2011;7:459–71.
4. Kułakowski P. Syncope update 2013: diagnosis and treatment; *Kardiol Pol.* 2013;71:215-23.
5. Gould PA, Krahn AD, Klein GJ, Yee R, Skanes AC, Gula LC. Syncope: A review. *Current Opinion in Cardiology.* 2006;21:34–41.
6. Soteriades ES, Evans JC, Larson MG, Chen MH, Chen L, Benjamin EJ, Levy D. Incidence and prognosis of syncope. *N Engl J Med.* 2002;347:878-85.
7. Brignole M, Alboni P, Benditt DG, Bergfeldt L, Blanc JJ, Thomsen PE, Gert van Dijk J, et al. Task Force on Syncope, European Society of Cardiology. Guidelines on management (diagnosis and treatment) of syncope –update 2004. *Eur Heart J.* 2004;25:2054-72.
8. Krahn AD, Klein GJ, Yee R, Skanes AC. The use of monitoring strategies in patients with unexplained syncope role of the external and implantable loop recorder. *Clin Auton Res.* 2004;14:55-61.
9. Chao AC, Lin RT, Liu CK, Wang PY, Hsu HY. Mechanisms of cough syncope as evaluated by valsalva maneuver; *Kaohsiung J Med Sci.* 2007;23:55-62.
10. El-Osta H, Ashfaq S. Cough-Induced Syncope as an Unusual Manifestation of Pericardial Effusion; *Kansas Journal of Medicine.* 2008;1:53-5.
11. Benditt DG, Samniah N, Pham S, Sakaguchi S, Lu F, Lurie KG, Ermis C. Effect of cough on heart rate and blood pressure in patients with "cough syncope"; *Heart Rhythm.* 2005;2:807-13.
12. Ariturk Z, Alici H, Cakici M, Davutoglu V. A rare cause of syncope: cough. *Eur Rev Med Pharmacol Sci.* 2012;16uppl 1:71-2.
13. Stec S, Dabrowska M, Zaborska B, Bielicki P, Maskey-Warzechowska M, Tamowski W, et al. Premature ventricular complex-induced chronic cough and cough syncope; *Eur Respir J.* 2007; 30:391-4.

Yazışma Adresi / Address for Correspondence:

Dr. Filiz Koç
Cukurova University School of Medicine
Department of Neurology
ADANA
E-mail: koc.filiz@gmail.com

Geliş tarihi/Received on : 22.01.2015

Kabul tarihi/Accepted on: 27.02.2015