



OLGU SUNUMU / CASE REPORT

Primary leiomyosarcoma of the ovary

Primer ovaryan leiomyosarkom

Gökmen Sukgen¹, Adem Altunkol²

¹Özel Metro Hastanesi, Kadın Hastalıkları ve Doğum Kliniği, Adana, Turkey

²Sağlık Bilimleri Üniversitesi, Adana Şehir Eğitim ve Araştırma Hastanesi, Üroloji Kliniği, Adana, Turkey

Cukurova Medical Journal 2018;43(4):1038-1041

Abstract

Ovarian leiomyosarcoma is a rare aggressive tumor with a very bad prognosis. Contrary to their uterine counterparts, ovarian smooth muscle tumors are extremely rare comprising only 1% of ovarian tumors. Ovarian leiomyosarcoma is generally seen in the postmenopausal period. Here we report a 59-year old patient diagnosed as as ovarian primary leiomyosarcoma.

Key words: Ovarian neoplasm, sarcoma, leiomyosarcoma

Öz

Over leiomyosarkomu çok kötü prognozlu agresif nadir bir tümördür. Uterin tümörlerin aksine ovaryan düz kas tümörleri, yumurtalık tümörlerinin sadece% 1'ini içeren çok nadir tümörlerdir. Ovaryan leiomyosarkom genellikle postmenapozal periyotta görülür. Burada primer ovaryan leiomyosarkom tanısı konan 59 yaşında bir hasta sunulmuştur.

Anahtar kelimeler: Ovaryan neoplasm, sarkom, leiomyosarkom.

INTRODUCTION

Ovarian leiomyosarcoma (LMS) is extremely rare among genital tumors. Primary leiomyosarcomas of the ovary are exceptionally rare comprising less than 1% of ovarian sarcomas¹. These tumors, whose origins are not fully known and which are usually seen in postmenopausal period, have quite aggressive clinical behavior and generally are diagnosed in advanced stages. Patients' survival time is limited with 1 to 2 years in many cases².

Leiomyosarcoma is the most common soft tissue sarcoma in children. It is mainly seen in head, neck, retroperitoneum and extremities. In the female genital tract, vulva and vagina are the most common areas where embryonal and botryoid sarcomas are seen³. It can be seen in 20% of the genitourinary localization patients. The affected organ in the genital system is generally vagina, but it can also be detected in cervix. Most of the leiomyosarcomas in the genital system have embryonal variants; ovary is a very rare location for leiomyosarcoma. It is usually seen as a component of complex tumors such as

heterologous type malignant mixed mullerian tumor, adenosarcoma, immature teratoma and Sertoli-Leydig cell tumor^{2,3}. To the best of our knowledge, only 73 examples of POLMS (including the present case) have been reported⁴. This paper aims to present a case diagnosed with LMS.

CASE

The 59-year-old patient applied to our hospital with swelling and severe pain in the abdominal area which developed in a short time. Gravida-0 and Parity-0 patient, there was no chronic illness or drug story. Physical examination indicated that the abdomen was extremely stretched; and advanced stage distension was identified; palpation was painful, and no acid was observed. Radiological examination indicated that uterus was normal, a heterogeneous solid tumor mass was identified in the right and left ovary, filling the pelvis area of the uterus and extending to the upper quadrant of abdomen. On magnetic resonance imaging, partially cystic and partially solid ovarian mass was observed. The mass filling the entire abdomen was observed

Yazışma Adresi/Address for Correspondence: Dr. Adem Altunkol, Sağlık Bilimleri Üniversitesi, Adana Şehir Eğitim ve Araştırma Hastanesi, Üroloji Kliniği, Adana, Türkiye E-mail: ademaltunkol@hotmail.com
Geliş tarihi/Received: 26.02.2018 Kabul tarihi/Accepted: 28.03.2018

which was extending from the left adnexal region and the masses size was approximately 35 cm (Fig. 1). No intraabdominal free liquid was observed. Tumor indicators of CA125,CA19-9,CEA were normal. Laparotomic observation indicated left ovary. During exploratory laparotomy, no other sign of malignancy was observed in other pelvic and abdominal structures. Total hysterectomy (TAH), bilateral salpingo-oophorectomy (BSO), omentectomy, appendectomy, bilateral pelvic and paraaortic lymph node dissection (BPPLND), and peritoneal washing were performed.

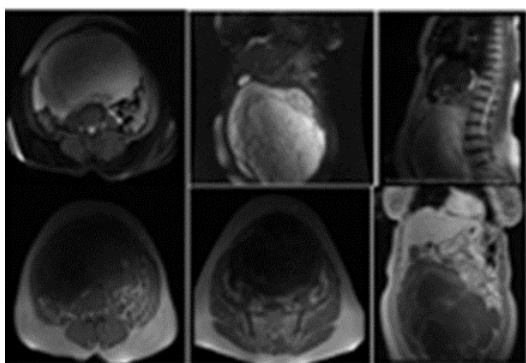


Figure 1. The MRI of adnexal mass.

No palpable lymph node or metastatic tissues were observed. On the macroscopic examination, right ovary was normal. Right tubal uterine and uterus was clearly visible, but left tubal uterine was indistinguishable. The tumor was not invasive in the surrounding tissues including omentum. It was limited in the ovarian capsule. Stage was evaluated as IA according to FIGO. Minimal adhesion was observed in the surrounding tissues. The adhesions were surgically dissected (Figure 2).

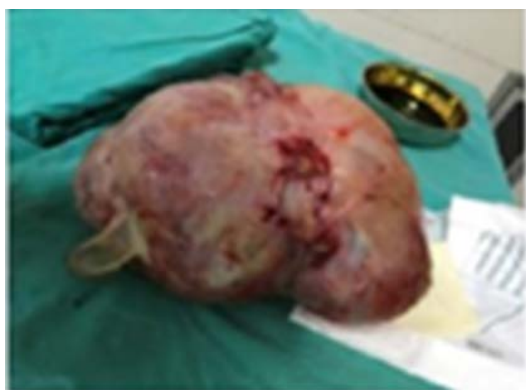

Figure 2. Intraoperative view of the adnexal mass.

Left ovary tumor, increased hyper cellularity, nuclear atypia, pleomorphism, high mitotic activity with atypical mitosis and coagulation necrosis were observed on the microscopic examination (Figure3).

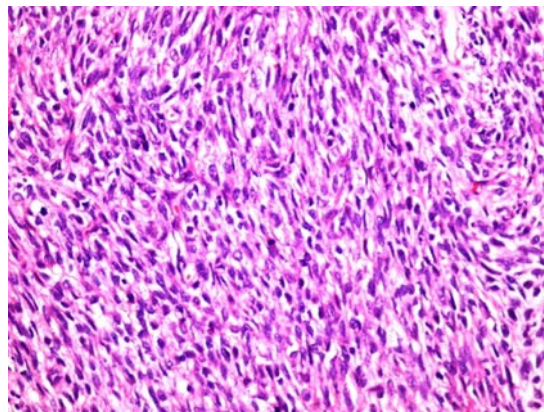


Figure 3. Higher magnification of tumor. Note mitotic activity and cellular and nuclear pleomorphism (Hematoxylin and eosin 400).

Immunohistochemical examination revealed Vimentin-Caldesmon-positive, SMA focal-positive, Panck-Desmin-CD34-EMA-CD117-S100-CD99-NEGATIVE. Ki-67 proliferation index was 30-40%. The patient was referred to the medical oncology clinic in the postoperative period. No adjuvant chemotherapy was given. The patient was given PET (Positron Emission Tomography) in the 1st and the 6th month after surgery. No lesions indicating metastatic suspicion were observed; therefore, the patient was monitored in routine clinical follow-up. No recurrence was indicated in the 6th month follow up when this paper was written.

DISCUSSION

Primary ovarian sarcoma represents a heterogeneous group of ovarian tumors and is classified as teratoid, mesenchymal, and mullerian type according to the source of origin⁵. Ovarian smooth muscle cell tumors (SMT) are extremely rare, comprising only 1% of ovarian tumors³. Smooth muscle present in the walls of the blood vessels in the cortical stroma, in the corpus luteum, and in the attachment points of ovarian ligaments has been postulated to be the site of origin⁶. Additionally, smooth muscle metaplasia of endometriotic stroma, smooth muscle present in mature cystic teratomas, and in the walls of mucinous cystic tumors were also considered due

to the association of leiomyosarcoma with these tumors in some anecdotal cases³. Malignant transformation of ovarian leiomyoma and migration of uterine leiomyoma are other proposed mechanisms of histogenesis².

Approximately 400 ovarian primary sarcoma cases have been reported since 1998. Of these cases, 300 were carcino sarcoma, 50 were LMS, and 30 were endometrial stromal sarcoma or other histological types⁷. Ovarian LMS cases are generally in the postmenopausal period. However, as reported in one case, it can be diagnosed in the premenopausal period as well^{8,9}. These tumors are typically solitary, lobular hemorrhagic, and cystic degenerative masses. They are generally unilateral lesions above 1 cm. Extra ovarian spread happens mainly during surgery. However, this spread is local and peritoneal in many cases. On the other hand, distant metastases were identified in a few cases. No diagnostic criteria could have been identified for primary ovarian LMS so far⁷.

Histological criteria in primary ovarian LMS include increased hyper cellularity, nuclear atypia, pleomorphism, high mitotic activity with atypical mitosis, and coagulation necrosis⁸. Leiomyoma, fibrotecoma, fibrosarcoma, endometrial stromal sarcoma, mixed mullerian tumor, carcinoid carcinoma of the stomach, and metastatic gastrointestinal stromal tumor should be considered in the differential diagnosis¹⁰.

Primary ovarian leiomyoma or LMSs are probably rooted from muscle smooth cells or ovarian ligaments in cortical stroma and corpus luteum. Besides, they could develop from the Wolf's canal wastes, totipotent ovarian mesenchyme^{7,11,12}. In addition, ovarian LMS is considered to develop as a result of malignant degeneration of ovarian leiomyoma.

The major prognostic factor is the stage of the disease². The prognosis of POLMS is extremely poor, and survival may be related to tumor stage, tumor size, grade, and mitotic index³. Some authors have suggested that stage at diagnosis is a more important prognostic variable¹¹. However, residue tumor after surgery is considered to be as important as the stage in recurrence and survival time.

Muntz et al.¹³ found that 2-year survival time was 14% in suboptimal surgery patients, and 52% in optimal ones. On the other hand, Barakat et al.¹⁴

found that residue tumor size did not have direct effects on survival time.

Primary ovarian LMSs usually have bad prognosis. In most cases, the disease shows recurrence about one year after the initial surgery, and patients usually die within 2 years². In their series Monkve et al. reported that 21 patients, except for three, who received the diagnosis of ovarian LMS lost their lives within 2 years¹⁵. The longest survival time in this series was found 68 months. In a case reported by Nasu et al.¹⁶, peritoneal and hepatic recurrence were detected 18 months after the initial surgery, and the patient died 2 years after the recurrence.

Nicotina et al.¹⁷ reported acid, lung, and liver recurrence in the IIA primary ovarian LMS case 18 months after the initial surgery. The patient died 6 months after metastases. One of the cases presented in this article was stage IA and was monitored for 13 months; the other was stage IIIC and was monitored for 48 months; but no recurrence was observed. On the other hand, Dai et al.¹⁸ reported in their series that two LMS cases, which were considered as stage III, died within 5 months.

POLMS mostly recurs in abdomen and pelvis, and less frequently in lung, bone, liver, mediastinum, brain, preauricular lymph node, and scalp⁹. Ovarian LMS is a rare tumor with bad prognosis which is usually seen at advanced ages. It is evident that the surgical procedure should be optimal cytoreductive. Anthracycline-based chemotherapy should be administered as adjuvant treatment. However, there is still not enough evidence to show that postoperative adjuvant chemotherapy is effective. Standardization of treatment is not possible with insufficient data due to the low number of cases. Hence, a 59-year-old patient with ovarian leiomyosarcoma has been presented here.

Ovarian leiomyosarcomas are extremely rare tumors which have bad prognosis, low survival rates, and a lot of question marks in its diagnosis and treatment. A long-term collection of well-documented cases is needed to clarify the disease and to develop treatment options.

REFERENCES

1. Vijaya Kumar J, Khurana A, Kaur P, Chuahan AK, Singh S. A rare presentation of primary leiomyosarcoma of ovary in a young woman. *Ecancermedalscience*. 2015;21:524.

2. Bouie SM, Cracchiolo B, Heller D. Epithelioid leiomyosarcoma of the ovary. *Gynecol Oncol.* 2005;97:697-9.
3. Lerwill MF, Sung R, Oliva E, Prat J, Young RH. Smooth muscle tumors of the ovary. A clinicopathologic study of 54 cases emphasizing prognostic criteria, histologic variants, and differential diagnosis. *Am J Surg Pathol.* 2004;28:1436-51.
4. He M, Deng YJ, Zhao DY, Zhang Y, Wu T. Synchronous leiomyosarcoma and fibroma in a single ovary: A case report and review of the literature. *Oncol Lett.* 2016;11:2510-4.
5. Azoury AS, Woodruff JD. Primary ovarian sarcomas: report of 43 cases from the Emil Novak Tumor Registry. *Obstet Gynecol.* 1971;37:920-91.
6. Rasmussen CC, Skilling JS, Sorosky JI, Lager DJ, Buller RE. Stage IIIC ovarian leiomyosarcoma in a premenopausal woman with multiple recurrences: prolonged survival with surgical therapy. *Gynecol Oncol.* 1997;66:519-25.
7. Piura B, Rabinovich A, Yanai-Inbar I, Glezerman M. Primary sarcoma of the ovary: report of five cases and review of the literature. *Eur J Gynaecol Oncol.* 1998;19:257-61.
8. O'Sullivan SG, Das Narla L, Ferraro E. Primary ovarian leiomyosarcoma in an adolescent following radiation for medulloblastoma. *Pediatr Radiol.* 1998;28:468-70.
9. Monk B, Nieberg R, Berek J. Primary leiomyosarcoma of the ovary in a perimenarchal female. *Gynecol Oncol.* 1993;48:389-93.
10. Young RH, Scully RE. Sarcomas metastatic to the ovary: a report of 21 cases. *Int J Gynecol Pathol.* 1990;9:231-52.
11. Friedman HD, Mazur M. Primary ovarian leiomyosarcoma. An immunohistochemical and ultrastructural study. *Arch Pathol Lab Med.* 1991;115:941-5.
12. Reddy S, Pui Poon T, Ramaswamy G, Tcherktkoff V. Leiomyosarcoma of the ovary. *N Y State J Med.* 1985;85:218-20.
13. Muntz HG, Jones MA, Goff BA, Fuller Jr AF, Nikrui N, Rice LW. Malignant mixed müllerian tumors of the ovary: experience with surgical cytoreduction and combination chemotherapy. *Cancer.* 1995;76:1209-13.
14. Barakat RR, Rubin SC, Wong G, Saigo PE, Markman M, Hoskins WJ. Mixed mesodermal tumor of the ovary: analysis of prognosis factors in 31 cases. *Obstet Gynecol.* 1990;80:660-4.
15. Nieminen U, von Numers C, Purola E. Primary sarcoma of the ovary. *Acta Obstet Gynecol Scand.* 1969;48:423-32.
16. Nasu M, Inuoe J, Matsui M, Minoura S, Matsubara O. Ovarian leiomyosarcoma: an autopsy case report. *Pathol Int.* 2000;50:162-5.
17. Nicotina PA, Antico F, Caruso C, Triolo O. Primary ovarian leiomyosarcoma. Proliferation rate and survival. *Eur J Gynaecol Oncol.* 2004;25:515-6.
18. Dai Y, Shen K, Lang JH, Huang HF, Pan LY, Wu M et al. Primary sarcoma of the ovary: Clinicopathological characteristics, prognostic factors and evaluation of therapy. *Chin Med J.* 2011;124:1316-21.