

Therapeutic effect of *Anethum graveolens* L. (Dill) seed extract for the treatment of dextran sodium sulfate (DSS) induced ulcerative colitis in Wistar rats

Karthick Kannan RAJENDRAN ^{1*} , INDUMATHY ² 

¹ Department of Pharmacology, Student of Pharmacy, Madras Medical College, Chennai, India.

² Department of Pharmacology, Faculty of Pharmacy, Madras Medical College, Chennai, India.

* Corresponding Author. E-mail: karthickdpm1999@gmail.com (K.R); Tel. +91-936-185 27 76.

Received: 28 June 2023 / Revised: 29 August 2023 / Accepted: 10 September 2023

ABSTRACT: The purpose of this study was to determine whether the *Anethum graveolens* L. seed (AGS) extract has any anti-oxidant, anti-inflammatory, or immune-modulatory activities against Ulcerative colitis (UC). AGS extract has found widespread use in folk medicine. Twenty seven (n=27) adult female Wistar albino rats were employed for the experiment involving Dextran Sodium Sulfate (DSS) induced UC. These rats were distributed randomly into five groups, each consisting of six animals (n=6), with the exception of group 1, which had three animals (n=3). Group 1 received 0.5% Carboxy methyl cellulose (CMC) (p.o.), Group 2 received 5% DSS (p.o.), Group 3 received 350 mg/kg b.w. mesalazine (p.o.), and Groups 4, 5, respectively, received 200 and 400 mg/kg AGS extract (p.o.). Along with administering DSS, the treatment lasted for 12 days. In comparison to the DSS-treated group, groups 4, and 5, there was a considerable weight gain. Comparing groups 4 and 5 to group 2, the groups 4 and 5 showed a substantial decrease in Disease Activity Index (DAI), colon damage (p<0.05), spleen weight (p<0.05), serum IL-6 (p<0.0001), TNF- α (p<0.01), and IL-17 (p<0.01) levels. Rats in groups 4 and 5 had significantly higher blood IL-10 levels (p<0.05) and longer colons than rats in group 2 (p<0.05). The good results, which showed an improvement in the state of the colon epithelium after AGS extract in treatment groups, were validated by a histopathological study. In summary, AGS extract may be able to control inflammatory reactions and safeguard the colon epithelium in UC. These results support the possible therapeutic application of AGS extract.

KEYWORDS: *Anethum graveolens* L.; ulcerative colitis; dextran sodium sulfate; antioxidant; anti-inflammatory.

1. INTRODUCTION

Globally, the incidence of immune-mediated inflammatory illnesses such as Ulcerative colitis (UC) and Crohn's disease (CD), sometimes known as inflammatory bowel diseases (IBDs), is rising quickly [1]. In the eastern globe, rapid urbanisation and industrialization were accompanied by an increase in the incidence and prevalence of IBD. IBD incidence rates of 1.37×10^5 in Asia and 3.4×10^5 in China have been observed in recent research [2].

Body weight loss, changed stools, bloody feces, and colonic shortening are common symptoms of UC along with colonic mucosal injuries and histological alterations in the intestines. Most people with UC are young or middle-aged, and up to 18% of patients have an active chronic illness that causes severe morbidity and productivity loss and typically requires lifelong therapy. The precise mechanisms underlying the pathophysiology of UC are, however, yet unknown. It is generally accepted that a confluence of environmental factors, genetic specificity, inflammation, oxidative stress, and intestinal flora imbalance is the pathophysiology of the disease. The pathophysiology of colitis has been linked to a number of variables, including the overproduction of inflammatory mediators such reactive oxygen species, pro-inflammatory cytokines, arachidonate metabolites, and neutrophil infiltration [3].

UC is typically treated with popular pharmaceutical medications such 5-aminosalicylate (5-ASA), corticosteroids, thiopurines, Tumor Necrosis Factor- α (TNF- α) inhibitors, calcineurin inhibitors, and anti-integrins. But a variety of harmful side effects are possible with these medications. One of the first medications prescribed for UC, sulfasalazine, for instance, can harm the liver and cause anaemia. Systemic corticosteroids, which are frequently used as first treatment, may cause a number of permanent side effects,

How to cite this article: Rajendran KK, Indumathy. Therapeutic effect of *Anethum graveolens* L. (Dill) seed extract for the treatment of Dextran Sodium Sulfate (DSS) induced Ulcerative colitis in Wistar rats. J Res Pharm. 2024; 28(3): 770-780.

including immune system impairment, weight gain, cataracts, hypothalamus pituitary axis suppression, and osteoporosis. Leukopenia, increased transaminases, and a higher risk of malignancy are just a few of the negative effects that thiopurines can cause [4]. Although most people tolerate TNF- α inhibitors well, they can occasionally cause unpleasant side effects such as headaches, injection site responses, infusion site reactions, rashes, anaemia, upper respiratory tract infections, and abdominal pain [5]. Calcineurin inhibitors have been linked to gastrointestinal problems, hypertension, neurotoxicity, altered metabolism, hepatotoxicity, and increased vulnerability to infections and cancer [6]. Similar findings have been reported with the anti-integrin medication vedolizumab [7].

There has been an increase in interest in herbal medicine as an alternative and supplementary treatment for UC because of the serious adverse drug reactions (ADRs) linked to several of the currently available UC medications. For the treatment of UC, a number of herbs have been investigated for their possible antioxidant and anti-inflammatory qualities. *Andrographis paniculata*, *Boswellia serrata*, *Jian Pi Ling*, *Xilei-san*, *Vaccinium myrtillus*, *Sophorae flavescens*, *Sanguisorba officinalis* L., *Indigo naturalis*, *Bletilla striata*, *Glycyrrhiza uralensis*, *Plantago ovata*, and *Oenothera biennis* are a few of them [8]. With the growing popularity of herbal medicine, research efforts have been concentrated on examining the bioactivities of these herbs from a bench to bedside perspective [9]. Despite the rarity of deaths or hospitalisations brought on by herbs, some people choose herbal medicines as an alternative to conventional pharmaceutical treatments for UC because of the risk of adverse drug reactions.

Dill (*Anethum graveolens* L.) from the Apiaceae family is a versatile plant used for its anti-inflammatory, diuretic, and carminative properties [10]. It contains phytochemicals like tannins, terpenoids, and flavonoids. Dill seeds are employed in Ayurveda for their carminative and diuretic effects [11]. Dill extract exhibits potent antioxidant activity [12], restoring enzyme activity in hepatotoxic rats [13]. It demonstrates anti-inflammatory action, reducing inflammatory proteins and protecting against esophageal damage [14]. Dill seed and aerial extracts have analgesic effects [15], and dill seed oil shows broad antibacterial activity against drug-resistant bacteria [16]. The primary constituents of dill seed oil, including carvone and dill-apiole, display concentration-dependent cytotoxic effects on liver cancer cells [17].

Despite the fact that several conventional medications are now being used to treat UC, they are unable to do so with sufficient efficacy and/or safety because of their numerous severe side effects and intolerance problems. However, it is imperative to look for a medication that is more adequately effective, more tolerable, or safer for the treatment of UC; this study's objective stems from this need.

2. RESULTS AND DISCUSSION

2.1 Gas Chromatography- Mass Spectrometry (GC-MS) Analysis

The GC-MS analysis of the AGS extract revealed a number of phytoconstituents including limonene, D-limonene, dihydrocarvone, carvone, apiol, which all contribute to its overall pharmacological activity.

Limonene and D-limonene are effective at reducing inflammation in a variety of tissues and organs because they have anti-inflammatory qualities that prevent the formation of inflammatory mediators. They also function as antioxidants, defending cells and tissues against oxidative stress and averting oxidative damage, especially in the colon. By preventing tumour growth, causing cell death, and demonstrating chemopreventive capabilities in breast, lung, and colon cancer, these substances also demonstrate potential anticancer benefits. Additionally, the antibacterial properties of limonene and D-limonene, which work against bacteria and fungus, can aid in the management of microbial illnesses [18].

The dill seed constituent's carvone and dihydrocarvone are involved in the pharmacological activity of the AGS extract. They may have antispasmodic characteristics that calm smooth muscle tissue and have been linked to gastrointestinal symptoms. The symptoms of gastrointestinal conditions including UC and irritable bowel syndrome may be lessened by this relaxation. Additionally, carvone and dihydrocarvone have shown potential analgesic and anti-inflammatory properties, relieving pain and lowering inflammation linked to illnesses like UC and arthritis [19].

The pharmacological activity of the AGS extract also benefits from apiol, a phenolic component present in celery, dill, and parsley. By preventing the synthesis of pro-inflammatory chemicals including prostaglandins and cytokines, apiol has anti-inflammatory capabilities. As an antioxidant, it lowers oxidative stress by scavenging damaging free radicals. These qualities are especially helpful in the case of UC, which is characterised by a high level of colonic inflammation and oxidative damage. Additionally, apiol has long been used to treat diarrhoea symptoms, potentially helping with this element of UC management [20].

2.2 Effect of AGS extract on Body weight and Disease Activity Index (DAI) of DSS treated rats

Body weight loss is frequently seen in animal models of UC, demonstrating the negative effects of inflammation on general health. In this investigation, disease control rats had considerably lower body weights than normal controls rats (Figure 1A). However, when compared to the disease control group, using a Standard drug caused weight gain. AGS extract was administered at a dose of 200 mg/Kg b.w., which is interesting because it caused a moderate increase in body weight but was not as effective as the standard drug. AGS extract restored body weight similarly to the standard drug at a greater dose of 400mg/Kg b.w.

An important indicator of the severity of UC is the DAI which take into account rectal bleeding, body weight loss, and stool consistency [21]. Rats given DSS had considerably greater DAI levels than normal control rats (Figure 1B). Comparing the standard drug treatment group to the disease control group, DAI was dramatically reduced. While the DAI did reduce slightly after taking the AGS extract at a dose of 200 mg/Kg body weight, it was not as effective as the standard drug. The AGS extract was comparable to the standard drug in lowering UC disease activity at a dose of 400mg/Kg b.w., though. These results demonstrate that AGS extract, especially at larger doses, has the ability to alter the DAI and reduce the severity of UC.

2.3 Effect of AGS extract on Colon length and damage of DSS treated rats

Changes in the colon's length can result from inflammation and damage in UC. The degree of colon destruction can be used to gauge the severity of UC [22].

Colon length changes reflect inflammation and damage in UC, correlating with disease severity. Disease control rats showed significantly reduced colon length compared to normal controls ($P<0.0001$) (Figure 1C). Standard drug and AGS extract (400mg/Kg) increased colon length relative to disease control ($P<0.0001$). At the lower dose (200mg/Kg), colon length was significant increased ($P<0.05$) when compared to disease control rats. Higher AGS extract dose exhibited the most significant lengthening effect ($P<0.0001$). These results suggest therapeutic potential for both treatments in promoting colon tissue healing in UC.

In the disease control group, there was a significant increase ($P<0.0001$) in macroscopic colonic damage compared to the normal control rats (Figure 1D). Treatment with the standard drug significantly reduced colonic damage compared to the disease control group ($P<0.001$). At a lower dose (200mg/Kg) of the AGS extract, there was a significant reduction ($P<0.05$) in macroscopic colonic damage compared to the disease control rats. At a higher dose (400mg/Kg) of the AGS extract, there was a notable decrease ($P<0.01$) in colonic damage compared to the disease control rats. Remarkably, the higher dose of the AGS extract was more effective than the lower dose in reducing colon damage. The AGS extract, particularly at higher doses, demonstrated potential in promoting colon tissue regeneration and reducing colon damage.

2.4 Effect of AGS extract on Spleen weight of DSS treated rats

Organ weights can change as a result of UC, among other systemic consequences. The spleen, one of the afflicted organs in this illness, is essential to the immunological response. Understanding how the weight of the spleen changes in an animal model of UC will help us understand how the condition develops as well as what potential therapeutic impact treatments might have [23].

From the data obtained (Figure 1E), there was a significant increased ($P<0.0001$) spleen weight of disease control rats when compared to normal control rats. When compared to disease control rats (DSS), there was significant reduced ($P<0.05$) spleen weight of standard drug treated rats. At both the doses of 200 mg/kg b.w and 400 mg/kg b.w, the scores showed that there was significant reduced ($P<0.05$) spleen weight when compared to disease control rats.

In the experimental model of UC, disease control rats showed a significant increase in spleen weight compared to normal control rats, indicating systemic immune activation and inflammation. Treatment with the standard drug reduced spleen weight significantly, indicating its potential to regulate immune response and inflammation. At the dose of 200mg/Kg, the AGS extract also decreased spleen weight compared to the disease control rats, albeit less effectively than the standard drug. At the dose of 400mg/Kg of the AGS extract further decreased spleen weight, highlighting its immune-modulating and anti-inflammatory potential. These findings suggest that the AGS extract may offer therapeutic benefits in modulating immune response and inflammation in UC.

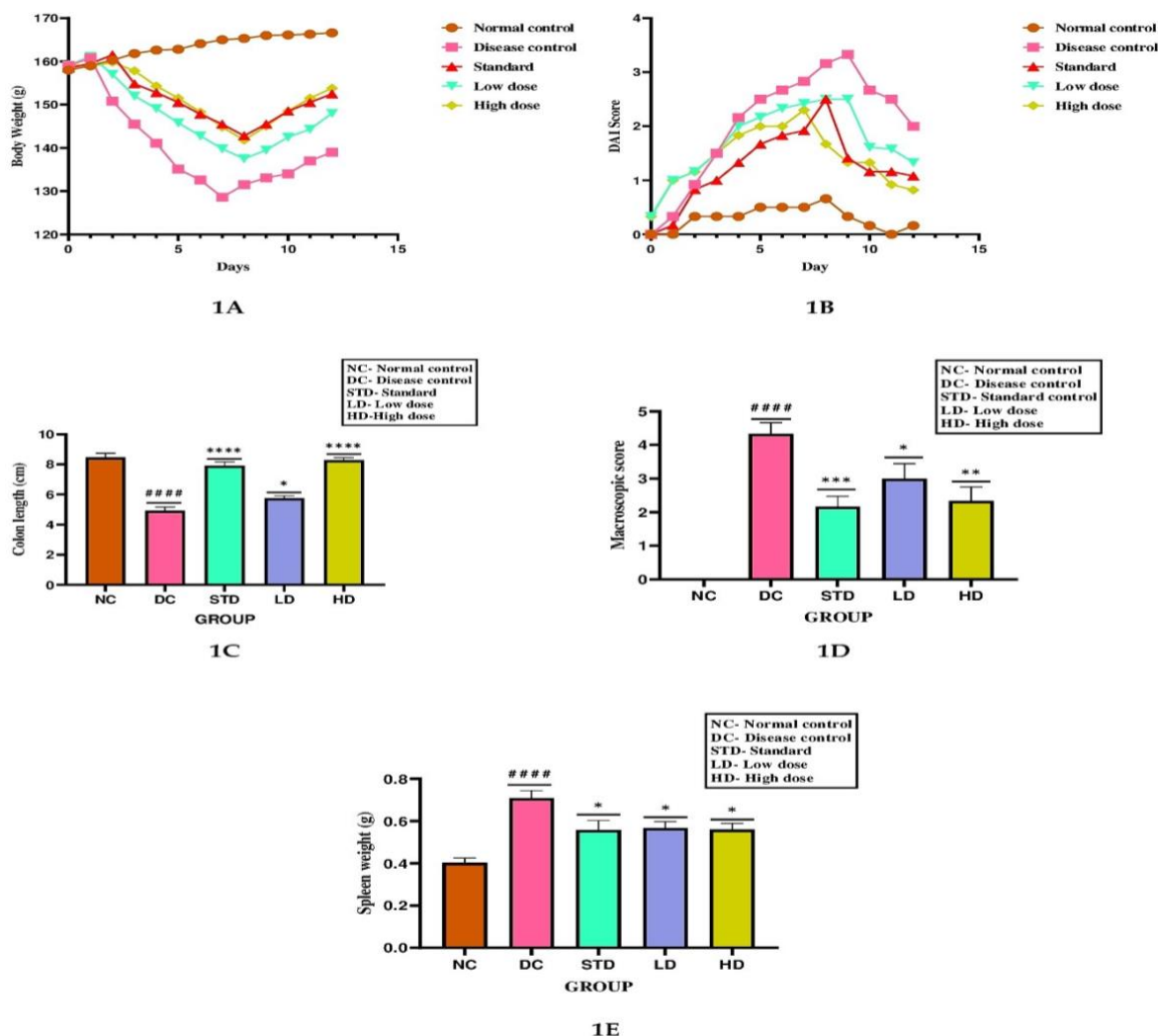


Figure 1

Figure 1. Effect of AGS extract on DSS induced UC Wistar albino rats. 1A: Body weight change was recorded during the experiment. 1B: DAI scores were recorded at certain time points. 1C: Colon length in different groups (#### $P < 0.0001$ compared to normal control group, **** $P < 0.0001$ compared to disease control group, * $P < 0.05$ compared to disease control group). 1D: Colon damage of different groups (#### $P < 0.0001$ compared to normal control group, *** $P < 0.001$ compared to disease control group, ** $P < 0.01$ compared to disease control group, * $P < 0.05$ compared to disease control group). 1E: Spleen weight in different groups (#### $P < 0.0001$ compared to normal control group, * $P < 0.05$ compared to disease control group).

2.5 Effect of AGS extract on Serum interleukins (ILs) and TNF- α level of DSS treated rats

UC is a chronic inflammatory bowel disease characterized by excessive immune activation and inflammation in the colon. Interleukins (ILs) play a critical role in mediating the immune response and inflammatory processes associated with UC. Assessing the levels of different ILs can provide valuable insights into the disease pathogenesis and the potential therapeutic effects of interventions [24].

According to the data gathered for this study (Figure 2A), there was a significant increased ($P < 0.0001$) serum IL-6 level of disease control rats when compared to normal control rats. When compared to disease control rats (DSS), there was significant reduction ($P < 0.0001$) in serum IL-6 level of standard, low dose and high dose treated rats. The lowered IL-6 levels indicate a potential therapeutic impact of the standard drug in regulating the immune response and lowering inflammation. Similar to the disease control rats, a dose of 200 mg/kg b.w and 400 mg/kg b.w displayed a significant decrease in serum IL-6 levels. Although both dosages were almost as effective as the standard drug in reducing inflammation, the high dose group had a somewhat more dramatic effect on IL-6 levels.

From the data obtained (Figure 2B), there was a significant increase ($P<0.0001$) in serum TNF- α levels in disease control rats compared to normal control rats. However, treatment with the standard drug resulted in a significant reduction ($P<0.0001$) in serum TNF- α levels compared to the disease control group. At a dose of 200mg/Kg b.w of AGS extract, there was a significant reduction ($P<0.01$) in serum TNF- α levels compared to the disease control rats. Similarly, at a dose of 400mg/Kg b.w of AGS extract, there was a significant reduction ($P<0.001$) in serum TNF- α levels compared to the disease control rats. These results indicate that both the standard drug and the AGS extract have the potential to effectively reduce TNF- α levels.

From the data obtained (Figure 2C), disease control rats exhibited a significant increase ($P<0.0001$) in serum IL-17 levels compared to normal control rats. However, treatment with the standard drug led to a significant reduction ($P<0.0001$) in serum IL-17 levels compared to the disease control group. At a dose of 200mg/Kg b.w of AGS extract, there was a significant decrease ($P<0.01$) in serum IL-17 levels compared to the disease control rats. Similarly, at a dose of 400mg/Kg b.w of AGS extract, there was a significant decrease ($P<0.001$) in serum IL-17 levels. However, neither dosage of the AGS extract showed a significant anti-inflammatory response comparable to the standard drug. These findings suggest that the standard drug has a stronger capacity to reduce the pro-inflammatory cytokine IL-17 compared to the AGS extract.

From the data obtained (Figure 2D), disease control rats showed a significant reduction ($P<0.0001$) in serum IL-10 levels compared to normal control rats. However, treatment with the standard drug resulted in a significant increase ($P<0.001$) in serum IL-10 levels compared to the disease control group. At a dose of 200mg/Kg b.w of AGS extract, there was a significant increase ($P<0.05$) in serum IL-10 levels compared to the disease control rats. Similarly, at a dose of 400mg/Kg b.w of AGS extract, there was a significant increase in serum IL-10 levels. However, neither dosage of the AGS extract demonstrated a significant anti-inflammatory response comparable to the standard drug. These findings suggest that the standard drug has a stronger capacity to enhance the anti-inflammatory signaling through IL-10 compared to the AGS extract.

Overall, the results showed that the UC animal model exhibits dysregulation of pro-inflammatory and anti-inflammatory cytokines. At various doses, both the regular medication and the AGS extract modulated these cytokine levels to differing degrees of efficiency. Although the AGS extract's benefits on elevating IL-10 and decreasing IL-17 levels were more obvious at larger doses, it was still less effective than the usual medication. However, the AGS extract showed encouraging results in lowering TNF- α and IL-6 levels, demonstrating its potential as an anti-inflammatory drug.

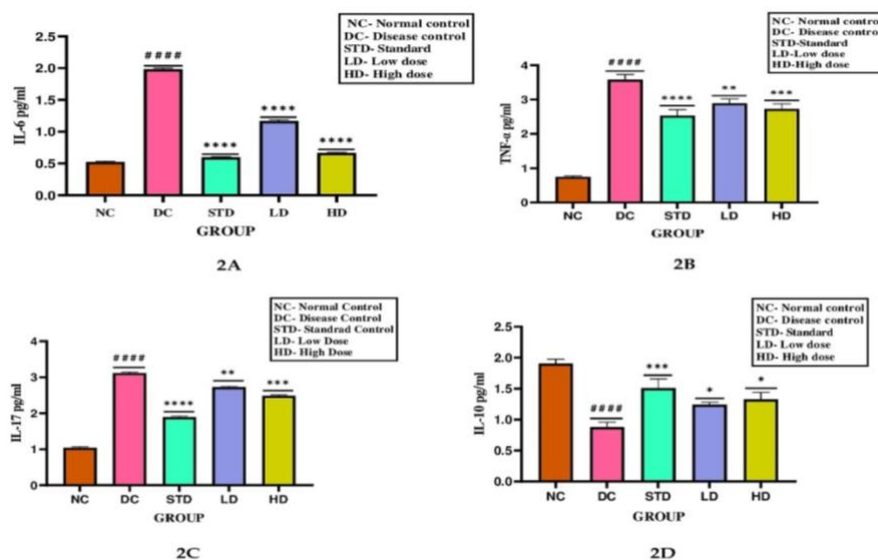


Figure 2. Effect of AGS extract on Serum ILs and TNF- α level of DSS induced UC Wistar albino rats. 2A: IL-6 serum level (#### $P<0.0001$ compared to normal control group, **** $P<0.0001$ compared to disease control group). 2B: TNF- α serum level (#### $P<0.0001$ compared to normal control group, **** $P<0.0001$ compared to disease control group, ** $P<0.01$ compared to disease control group, *** $P<0.001$ compared to disease control group). 2C: IL-17 serum level (#### $P<0.0001$ compared to normal control group, **** $P<0.0001$ compared to disease control group, ** $P<0.01$ compared to disease control group, *** $P<0.001$ compared to disease control group). 2D: IL-10 serum level (#### $P<0.0001$ compared to normal control group, *** $P<0.001$ compared to disease control group, * $P<0.05$ compared to disease control group).

2.6 Effect of AGS extract on histopathology of colon tissue of DSS treated rats

The histopathological analysis of the rat colon in this study provides valuable insights into the impact of UC and the potential therapeutic effects of the standard drug and AGS extract [21].

The impact of UC and the potential therapeutic effects of the usual medication and AGS extract are clarified by the histological examination (Figure 3) of the rat colon in this study. The inflammatory cells (lymphocytes, plasma cells, neutrophils, and eosinophils), goblet cells, and epithelial cells in the colon sections from normal control rats showed a normal architecture (Figure 3A). The other categories can be compared to this as a starting point.

The colon portions from the disease-control rats (Figure 3B), however, showed a number of UC-specific traits. Multiple foci of erosion and epithelial cell degeneration were seen (indicated in black arrow), pointing to damage to the colon's protective lining. Various inflammatory cells, including lymphocytes, plasma cells, neutrophils, and eosinophils, were also infiltrated in a moderate number of foci (indicated in red arrow). This infiltration indicates that inflammation and an active immune response are present. Mild goblet cell loss was also seen (indicated in blue arrow), which could indicate poor mucus function and colon epithelial defence.

The colon's histological characteristics significantly improved after receiving the standard drug (Figure 3C). Comparatively to the disease control group, the sections from the rats receiving standard drug treatment showed reduced epithelial cell erosion and degeneration (indicated in black arrow). Additionally, there was a slight reduction in the infiltration of inflammatory cells, pointing to a less inflammatory response. A slight restoration of normal goblet cell activity was also shown by the minor goblet cell depletion.

Similar to this, but to a lesser extent than the standard drug group, the sections from the rats treated with AGS extract (Figure 3D and 3E) shown improvements in colon histology. Epithelial cell erosion was barely noticeable (indicated in black arrow), pointing to a protective effect of the AGS extract. Mild inflammatory cell infiltration that was predominantly made up of lymphocytes and neutrophils (indicated in red arrow) was present. This shows that the AGS extract may have an anti-inflammatory effect. A partial retention of goblet cell activity was indicated by the low level of goblet cell depletion (indicated in blue arrow).

Overall, the histopathological examination confirms the usual medication's and AGS extract's therapeutic potential for easing UC's effects on the colon. Improvements in epithelial cell integrity, inflammatory cell infiltration, and goblet cell depletion were seen with both therapies. However, compared to the AGS extract, the regular medication displayed milder epithelial cell erosion and degeneration as well as a higher reduction in inflammatory cell infiltration, suggesting that it was more successful in reducing these histological abnormalities.

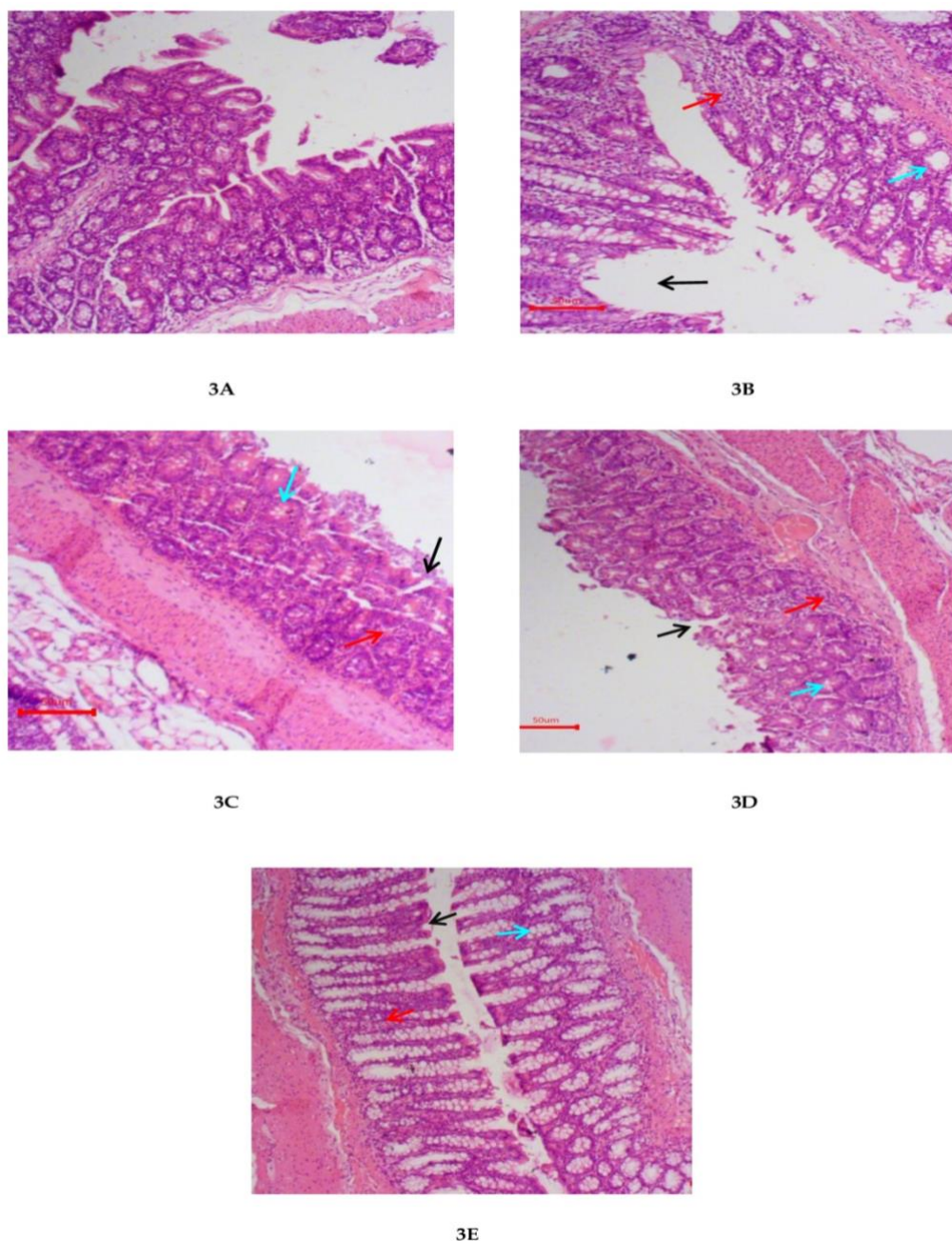


Figure 3. Effect of AGS extract on the colon histology of rat challenged with DSS. Sections of the colon presented in the various experimental groups showing the histo-architecture of the rats' colon, Black arrow represents epithelial cells, Red arrow represents inflammatory cells, and Blue arrow represents goblet cells.

3. CONCLUSION

Anethum graveolens L., a component of dill, has potential for treating UC. Its constituents have digestive, antibacterial, anticancer, anti-inflammatory, and antioxidant effects. High-dose dill extract improved UC parameters in an animal model on par with or better than conventional medicine. Extract taken in low doses had some effects. To further understand mechanisms and regulate dosage, more study is required. Clinical investigations are required to confirm these results in people. Dill extract has the potential to be a useful treatment for UC.

4. MATERIALS AND METHODS

4.1 Materials

4.1.1 Plant materials

Fresh samples of *Anethum graveolens* L., seeds were used for this study. The seeds of *Anethum graveolens* L., were purchased from local market, Chennai, Tamil Nadu. The seeds were authenticated by Dr.K.N. Sunil Kumar, Research officer and HOD of Pharmacognosy, Siddha Central Research Institute, Arumbakkam, Chennai.

4.1.2 Experimental animals

Twenty-seven (27) adult female Wistar albino rats (6 to 8 weeks old and the weight (150-200gm)) were used for this study. The present study was conducted after obtaining approval from the Institutional Animal Ethics Committee and this protocol met the requirements of national guidelines of CPCSEA/IAEC approval no: 03/IAEC/MMC/2022-2023, Dated 14.12.2022. Female Wistar albino rats used were procured from Animal house, Madras Medical College, Chennai. Animals were acclimatized for 7 days upon transfer to the work area under standard laboratory conditions with free access to standard pellets and water prior to the commencement of the experiment. All animal experiments were conducted in compliance with national guidelines of CPCSEA (Committee for the Purpose of Control and Supervision of Experiments on Animals).

4.1.3 Equipment and chemicals/kits

The equipment and chemicals used for this study were of analytical grade.

Equipment: Lyophilizer (BUCHI, India), Centrifuge (Cole-Parmer, India), Iodine flask, Volumetric flask, Beaker, test tubes and measuring cylinder (Star labs, Haryana, India), surgical blade (Jai surgicals, Haryana India), Weighing balance (Swastik systems and Services, New delhi, India), Dessicator (D and A collections, Ambala, India) and SHIMADZU GCMS-QP 2020 and AOC-20i autosampler (TRI- Biotech, Trichy, India)

Chemicals/Kits: Dextran Sodium Sulfate (Colitis Grade was obtained from Sisco Research Laboratories (SRL), India of Molecular weight- 35-50 kD.), Carboxy methyl cellulose (Labogens, India), Mesalazine (Cipla Pvt Ltd), Isoflurane (Baxter India Pvt Ltd, India) 99.9% v/v Ethanol (BRG biomedical, India), Distilled Water, Chemiluminescent immunoassay (Smitha diagnostics and Research center, Chennai) and Histological examination (Department of Pathology, Madras Veterinary College, Veppry, Chennai).

4.2 Methods

4.2.1 Preparation of AGS extract

Freshly collected seeds were dried, extraneous material was removed, the dried seeds were powdered, and the powdered seeds were passed through a 22 mesh sieve to extract and lyophilize the seeds. After that, the powder was macerated by immersing it in a 1:1 solution of ethanol and distilled water for 5 days while being stirred occasionally. After filtering, the filtrate was put through lyophilization by being put into a lyophilizer and being frozen at low temperatures. Following sublimation of the frozen solvent (ethanol and water) in a vacuum, a dry, solid residue was left behind. The acquired residue was weighed and kept dry by being stored in a desiccator.

4.2.2 GC-MS analysis

The study was carried out utilising a high-end single quadrupole mass analyzer in conjunction with a SHIMADZU GCMS-QP 2020 and AOC-20i autosampler and an SH-RXi-5Sil MS fused silica column (Crossbond 1, 4-bis (dimethylsiloxy) phenylene dimethyl polysiloxane). By searching and comparing the contents of the NIST and WILEY 8 libraries, a computer was able to determine the chemical components of AGS extract.

4.2.3 Experimental design and Induction of UC

A DSS-induced UC model, as described by Prakash et al. [25], was used in this work with a few minor adjustments. Twenty-seven (n = 27) female Wistar albino rats were used in the study. Included the normal group, which consisted of three animals (n=3), a total of five groups were formed. Each of the other four groups was comprised of six animals (n=6). Group 1- Normal control: Received 0.5% Carboxymethyl cellulose (CMC) (p.o) over the course of 12 days. Group 2- Disease Control: Treated with 5% DSS to induce

colitis for first 7 days (p.o), followed by 5 days of 0.5% CMC (p.o). Group 3- Standard control: Received 350 mg/Kg b.w., Mesalazine (p.o) [22] over the course of 12 days along with 5% DSS induction during the first 7 days. Group 4 (Low dose) and Group 5 (High dose): Received 200mg/kg b.w., and 400mg/kg b.w., of AGS extract [27] [28], respectively, over the course of 12 days along with 5% DSS administration during the first 7 days.

4.2.4 Disease Activity Index (DAI)

The DAI is a scoring system used to evaluate the clinical progression of colitis based on weight loss, stool consistency, and bleeding. The DAI scores range from 0 to 4 was given according to Chen *et al* with little modification [26]. The score is determined by weight loss (0: no weight loss, 1-5%: score 1, 5-10%: score 2, 10-15%: score 3, >15%: score 4), stool consistency (0: normal, 1: normal, 2: loose stools, 3: loose stools with visible pellet bleeding, 4: diarrhea), and bleeding (0: no bleeding, 1: occult blood present, 2: occult blood++, 3: occult blood+++ with visible pellet bleeding, 4: gross bleeding with blood around the anus). The higher the DAI score, the more severe the symptoms of colitis.

4.2.5 Assessment of Colon length, colon damage, spleen weight, serum interleukins level and histopathological changes

After completion of the experimental period (12 days), the rats were fasted overnight. On the 13th day, the rats were weighed and euthanized using light anaesthesia of Isoflurane (2%). For measurement of colon length, thickness, and damages, the entire colon was dissected. For measurement of spleen weight, spleen was isolated. For serum pro-inflammatory cytokines estimation, the blood was collected by cardiac puncture in non- heparinized tubes for serum separation, centrifuged at 1400 x g for 15 min using Remi C 854/8 centrifuge, and kept at - 20°C until assessing.

The entire colon was removed and length was measured. After the measurement of colon length, it was cut longitudinally along the mesentery, washed with ice cold saline, weighed and scores were given according to Zhu *et al* [22] (0: no ulcers and inflammation, 1: mucosal hyperemia and edema, 2: ulceration without mucosal hyperemia and edema, 3: single ulceration and mucosal inflammation, 4: more ulceration and mucosal inflammation, 5: severe ulceration extending >2 cm along the colon length with mucosal hyperemia and edema).

The entire spleen was removed and weighed from each rats in normal and disease control, standard drug and AGS treated groups. Increased spleen weights generally correlate with the extent of inflammation and anemia [21].

The peripheral blood was collected from each rat in normal and disease control, standard drug and AGS treated groups by cardiac puncture method. The serum was separated immediately and stored at -200C for further analysis. The level of pro-inflammatory mediators such as IL-6, TNF- α , IL-10 and IL-17 were measured by using CLIA kits using monoclonal antibodies according to manufacturer's instruction and expressed as pg/mL [21].

A colon was isolated from each rat in normal control, disease control, standard drug and AGS treated groups and then fixed in 10 % neutral buffered formalin for 24 h. The fixer was washed with running tap water overnight. The tissues were cleaned with methyl benzoate, after drying using a graded series of alcohols and embedded in wax with paraffin. At 6 mm thickness, colon tissue sections were cut, stained with hematoxylin and eosin dissolved in 95 % ethanol, was used to stain the counter. Colon tissue sections were observed under a microscope after dehydration and clearing.

4.3 Statistical analysis

All data were expressed as the mean \pm SEM. The difference between two groups was evaluated by the dunnett's multiple comparisons test. ANOVA was used to compare among five groups. P values of 0.05 or less was considered statistically significant. All statistical analysis was performed with GraphPad Prism software (9.5.1).

Acknowledgements: We would like to express our deep gratitude to Dean and Vice Principal for their support at Madras Medical College. We appreciate Principal of the College of Pharmacy for her support. Special thanks to Dr. M. Krishnaveni from Siddha Central Research Institute for her valuable support in selecting the plant for our research.

Author contributions: Concept – K.K.R.; Design – K.K.R.; I.R.; Supervision – I.R.; Resources – K.K.R.; Materials – K.K.R.; Data Collection and/or Processing – K.K.R.; Analysis and/or Interpretation – K.K.R.; I.R.; Literature Search – K.K.R.; Writing – K.R.; Critical Reviews – K.K.R.; I.R.;

Conflict of interest statement: The authors declared no conflict of interest

REFERENCES

- [1] Lin S, Lau LH, Chanchlani N, Kennedy NA, Ng SC. Recent advances in clinical practice: management of inflammatory bowel disease during the COVID-19 pandemic. *BMJ*. 2022; 71(7): 1426-1439. <http://doi.org/10.1136/gutjnl-2021-326784>
- [2] Actis GC, Pellicano R, Fagoonee S, Ribaldone DG. History of Inflammatory Bowel Diseases. *J Clin Med*. 2019; 8(11): 1970. <http://dx.doi.org/10.3390/jcm8111970>
- [3] Wang R, Luo Y, Lu Y, Wang D, Wang T, Pu W, Wang Y. Maggot Extracts Alleviate Inflammation and Oxidative Stress in Acute Experimental Colitis via the Activation of Nrf2. *Oxid Med Cell Longev*. 2019;2019:4703253. <https://doi.org/10.1155/2019/4703253>
- [4] Tripathi K, Feuerstein JD. New developments in ulcerative colitis: latest evidence on management, treatment, and maintenance. *Drugs Context*. 2019;8:212572. <https://doi.org/10.7573/dic.212572>
- [5] Gerriets V, Goyal A, Khaddour K. Tumor Necrosis Factor Inhibitors. *StatPearls* [Internet], Treasure Island (FL), 2022.
- [6] Safarini O, Keshavamurthy C et al. Calcineurin inhibitors. *StatPearls* [Internet], Treasure Island (FL), 2022.
- [7] Park SC, Jeon YT. Anti-integrin therapy for inflammatory bowel disease. *World J Gastroenterol*. 2018; 24(17): 1868-1880. <https://doi.org/10.3748/wjg.v24.i17.1868>
- [8] Triantafyllidi A, Xanthos T, Papalois A, Triantafyllidis JK. Herbal and plant therapy in patients with inflammatory bowel disease. *Ann Gastroenterol*. 2015; 28(2): 210-220.
- [9] Wan P, Chen H, Guo Y, Bai AP. Advances in treatment of ulcerative colitis with herbs: from bench to bedside. *World J Gastroenterol*. 2014; 20(39): 14099-14104. <https://doi.org/10.3748/wjg.v20.i39.14099>
- [10] Naseri M, Mojab F, Khodadoost M, Kamalinejad M, Davati A, Choopani R, Hasheminejad A, Bararpour Z, Shariatpanahi S, Emtiazy M. The study of anti-inflammatory activity of oil-based dill (*Anethum graveolens* L.) extract used topically in formalin-induced maggot extracts alleviate inflammation and oxidative stress in acute experimental colitis via the activation of Nrf2Inflammation male rat paw. *Iran J Pharm Res*. 2012; 11(4): 1169-1174.
- [11] Jana S, Shekhawat GS. *Anethum graveolens*: An Indian traditional medicinal herb and spice. *Pharmacogn Rev*. 2010; 4(8): 179-184. <https://doi.org/10.4103/0973-7847.70915>
- [12] Al-Oqail MM, Farshori NN. Antioxidant and anticancer efficacies of *Anethum graveolens* against human breast carcinoma cells through oxidative stress and caspase dependency. *Biomed Res Int*. 2021;2021:5535570. <https://doi.org/10.1155/2021/5535570>
- [13] Tamilarasi R, Sivanesan D, Kanimozhi P. Hepatoprotective and antioxidant efficacy of *Anethum graveolens* linn in carbon tetrachloride induced hepatotoxicity in albino rats. *J Chem Pharm Res*. 2012; 4(4): 1885-1888.
- [14] Nam HH, Nan L, Choo BK. Anti-Inflammation and protective effects of *Anethum graveolens* L. (dill seeds) on esophageal mucosa damages in reflux esophagitis-induced rats. *Foods*. 2021; 10(10): 2500. <https://doi.org/10.3390/foods10102500>
- [15] Rezaee-Asl M, Bakhtiarian A, Nikoui V, Sabour M, Ostadhadi S, Yadavar-Nikraves MS, Giorgi M. Antinociceptive properties of hydroalcoholic extracts of *Anethum graveolens* L. (dill) seed and aerial parts in mice. *Clin Exp Pharmacol*. 2013; 3:2. <https://doi.org/10.4172/2161-1459.1000122>
- [16] Dahiya P, Purkayastha S. Phytochemical analysis and antibacterial efficacy of dill seed oil against multi-drug resistant clinical isolates. *Asian J Pharm Clin Res*. 2012; 5(2): 62-64.
- [17] Al-Sheddi ES, Al-Zaid NA, Al-Oqail MM, Al-Massarani SM, El-Gamal AA, Farshori NN. Evaluation of cytotoxicity, cell cycle arrest and apoptosis induced by *Anethum graveolens* L. essential oil in human hepatocellular carcinoma cell line. *Saudi Pharm J*. 2019; 27(7): 1053-1060. <https://doi.org/10.1016/j.jsps.2019.09.001>
- [18] Anandakumar P, Kamaraj S, Vanitha MK. D-limonene: A multifunctional compound with potent therapeutic effects. *J Food Biochem*. 2021;45(1):e13566. <https://doi.org/10.1111/jfbc.13566>
- [19] Bouyahya A, Mechchate H, Benali T, Ghchime R, Charfi S, Balahbib A, Burkov P, Shariati MA, Lorenzo JM, Omari NE. Health benefits and pharmacological properties of carvone. *Biomolecules*. 2021; 11(12): 1803. <https://doi.org/10.3390/biom11121803>
- [20] Saleh-E-In MM, Sultana N, Rahim MM, Ahsan MA, Bhuiyan MN, Hossain MN, Rahman MM, Kumar Roy S, Islam MR. Chemical composition and pharmacological significance of *Anethum sowa* L. root. *BMC Complementary Altern Med* 2017; 17(1): 127. <https://doi.org/10.1186/s12906-016-1438-9>
- [21] Wang R, Wang D, Wang H, Wang T, Weng Y, Zhang Y, Luo Y, Lu Y, Wang Y. Therapeutic targeting of Nrf2 signaling by maggot extracts ameliorates inflammation-associated intestinal fibrosis in chronic DSS-Induced colitis. *Front Immunol*. 2021;12:670159. <https://doi.org/10.3389/fimmu.2021.670159>
- [22] Chen Z, Ni W, Yang C, Zhang T, Lu S, Zhao R, Mao X, Yu J. Therapeutic Effect of *Amomum villosum* on inflammatory bowel disease in rats. *Front Pharmacol*. 2018; 9: 639. <https://doi.org/10.3389/fphar.2018.00639>
- [23] Chassaing B, Aitken JD, Malleshappa M, Vijay-Kumar M. Dextran sulfate sodium (DSS)-induced colitis in mice. *Curr Protoc Immunol*. 2014;104:15.25.1-15.25.14. <https://doi.org/10.1002/0471142735.im1525s104>.

- [24] Chen L, Zhou Z, Yang Y, Chen N, Xiang H. Therapeutic effect of imiquimod on dextran sulfate sodium-induced ulcerative colitis in mice. PLoS One. 2017;12(10):e0186138. <https://doi.org/10.1371/journal.pone.0186138>
- [25] Prakash T, Janadri S. Anti-inflammatory effect of wedelolactone on DSS induced colitis in rats: IL-6/STAT3 signaling pathway. J Ayurveda Integr Med. 2023;14(2):100544. <https://doi.org/10.1016/j.jaim.2022.100544>
- [26] Yang N, Liang G, Lin J, Zhang S, Lin Q, Ji X, Chen H, Li N, Jin S. Ginsenoside Rd therapy improves histological and functional recovery in a rat model of inflammatory bowel disease. Phytother Res. 2020; 34(11): 3019-3028. <https://doi.org/10.1002/ptr.6734>
- [27] Bidgoli SA, Taheri E, Ziarati P. Safety evaluation of oral *Anethum graveolens* L total hydroalcoholic extract in mice. Asian J Pharm Health Sci. 2012; 1(2): 61-67.
- [28] Acute Oral Toxicity - Acute Toxic Class Method. OECD Guideline for Testing of Chemicals No. 423. www.oecd.org/env/testguidelines (accessed 2022 Oct 18).