

Euryale ferox Salisb ameliorates arthritis in experimental animals

Shradhanjali SINGH^{*1} , Varsha CHAUDHARY¹ , Shanti Bhushan MISHRA¹ , Anil Kumar SINGH¹ 

¹ United Institute of Pharmacy, A 31/1, UPSIDC, Industrial Area Naini, Prayagraj 211010, India

* Corresponding author. Email: singhshradhanjali@gmail.com (S.S.); Tel. +919651902926

Received: 2 November 2022 / Revised: 09 March 2022 / Accepted: 11 March 2022

ABSTRACT: The plant *Euryale ferox* salisb family (Nymphaeaceae) commonly known as prickly water lily have been traditionally used in the treatment of rheumatism hence in the present study, investigation of anti-arthritic activity was accomplished using 50% v/v unprocessed ethanolic extract of leaves & chloroform fraction in arthritic models. The 50% ethanolic extract (EFEE) was separated into four fractions including n-hexane (EFHF), chloroform (EFCF), ethyl acetate (EFEA) and methanol (EFMF). Preliminary phytochemical screening and TLC were carried out on extract and all four fractions. The induction was accomplished by intraplantar injection of formaldehyde (2%v/v), turpentine (10%v/v) and complete Freund's adjuvant (CFA) in left hind paw of wistar albino rats. Evaluation of anti-arthritic potential was been done by considering paw volume, body weight, joint diameter, arthritic score, serum enzymes, blood parameters and histopathological examination of rats blood and tissues. Extract and fraction were tested by phytochemical screening which signifies the existence of steroids, flavonoids, amino acid, alkaloid and phenolic compounds. In acute and chronic arthritic models, the plant had a dose-dependent anti-arthritic effect. The chloroform fraction (200mg/kg b.w) had a more significant effect than the 50% ethanolic extract. Hence, *Euryale ferox* ameliorates hematological indices, body weight, and histopathological alterations in a significant way.

KEYWORDS: Antiarthritic; Arthritic score; Complete Freund's adjuvant; *Euryale ferox* salisb; Histopathology.

1. INTRODUCTION

Chronic inflammatory autoimmune disease considering rheumatoid arthritis (RA) includes severe joint inflammation, synovial proliferation and destruction of articular cartilage which substantially impairs body's normal function [1]. Cartilage and bone substantially gets eroded due to immune complexes which are composed of activated protein complement. These activated complement releases cytokines considering TNF α and IL-1 which are chemotactic for neutrophils and release lysosomal enzymes. Initial treatment of patients treated with methotrexate (MTX) in addition to glucocorticoids, DMARDs, inhibitors of TNF α , or Janus kinases, ameliorates and prevents RA-related disability but shows major side effects such as oral ulceration, gastrointestinal upset and with prolonged drug therapy results in cirrhosis [2].

Traditional medicines are a form of a holistic health care system which treats symptoms and problems of certain given areas ultimately resulting in overall wellness whereas complementary and

How to cite this article: Singh, S., Chaudhary, V., Mishra, S.B., Singh, A.K. (2022). *Euryale ferox* Salisb ameliorates arthritis in experimental animals. *Journal of Research in pharmacy*, 23 (3), 753-769.

alternative medicines (CAM) systems focus on cause and prevention [3]. Hence, several medicinal plants molecules can be used to decrease the manifestation related to RA. The plant *Euryale ferox* salisb is commonly known as Phool makhana and gorgon nut throughout Asia. It is versatile and easy to enjoy in many different recipes, including snacks, Kheer, pudding and desserts as it possesses nutritional value considering the presence of numerous macronutrients, micronutrients and amino acids [4]. Several investigational approaches proved that *E. ferox* exhibits various pharmacological activities including anti-diabetic, anti-fatigue, ulcerprotective, anti-cancer, anti-oxidant, diabetic nephropathy [5], antihyperlipidemic, hepatoprotective [6], anti-melanogenic [7], cardioprotective [8] and gastro-retentive [9]. Chemically, the plant contains amino acids [10], butylated hydroxytoluene [11], (2S, 3R, 4E, 8E, 2'R)-1-O-(β -glucopyranosyl)-N-(2'-hydroxydocosanoyl)-4, 8-sphingadienine and (2S, 3R, 4E, 8E, 2'R)-1-O-(β -glucopyranosyl)-N-(2'-hydroxytetracosanoyl)-4,8-sphingadienine, ferotocotrimers C and D [12], euryalins A-C and N- α -hydroxyl-cis-octadecaenoyl-1- β -glucopyranosylsphingosine together with its trans isomer [13], 24-methylcholest5-enyl-3 β -O-pyranoglucoside, 24-ethylcholest5-enyl-3 β -O-pyranoglucoside, and 24-ethylcholesta5, 22E-dienyl-3 β -O-pyranoglucoside [14]. It also contains various components including carbohydrates, proteins, flavonoids, cyclic dipeptides, sterols, lipid, and vitamin E [11]. The leaves of *Euryale ferox* Salisb were traditionally claimed for rheumatism [15]. It is also found to be efficient in the treatment of pyoderma, hernia and leucorrhea [13]. Despite the above-mentioned pharmacological action, no antiarthritic activity has been explored for the plant, thus the current work aims to explore the antiarthritic potential of *Euryale ferox* Salisb leaf extracts and fractions in acute and chronic arthritic models.

2. RESULTS

2.1. Phytochemical analysis

Carbohydrates, steroids, flavonoids, alkaloids, amino acids, proteins and fixed oil were present in 50% *Euryale ferox* ethanolic extract and *Euryale ferox* chloroform fraction confirmed the presence of proteins, steroids, alkaloids and phenolic compounds.

2.2. Toxicity of the plant extract

EFEE and EFCF did not exhibit any toxicity and mortality when oral dosing was done up to 5000 mg/kg. Hence, two treatment doses were selected i.e., 100mg/kg and 200mg/kg b.w.

2.3. High-performance thin layer chromatography fingerprinting analysis

Qualitative HPTLC fingerprint analysis was performed for EFEE and EFCF using Ethyl acetate: toluene: formic acid (2:7:1v/v/v) at 254nm as shown in Figure 1. In HPTLC densitogram of EFEE, 7 spots were observed as shown in figure 1(a) at R_f values 0.09 (0.71%), 0.20 (1.55%), 0.40 (7.83%), 0.46 (8.19%), 0.50 (2.23%), 0.67 (3.26%) and 0.75 (2.78%). In HPTLC densitogram of EFCF, 04 spots were observed as shown in figure 1(b) at R_f values 0.07 (10.46%), 0.15 (15.48%), 0.41 (43.07%) and 0.47 (30.98%).

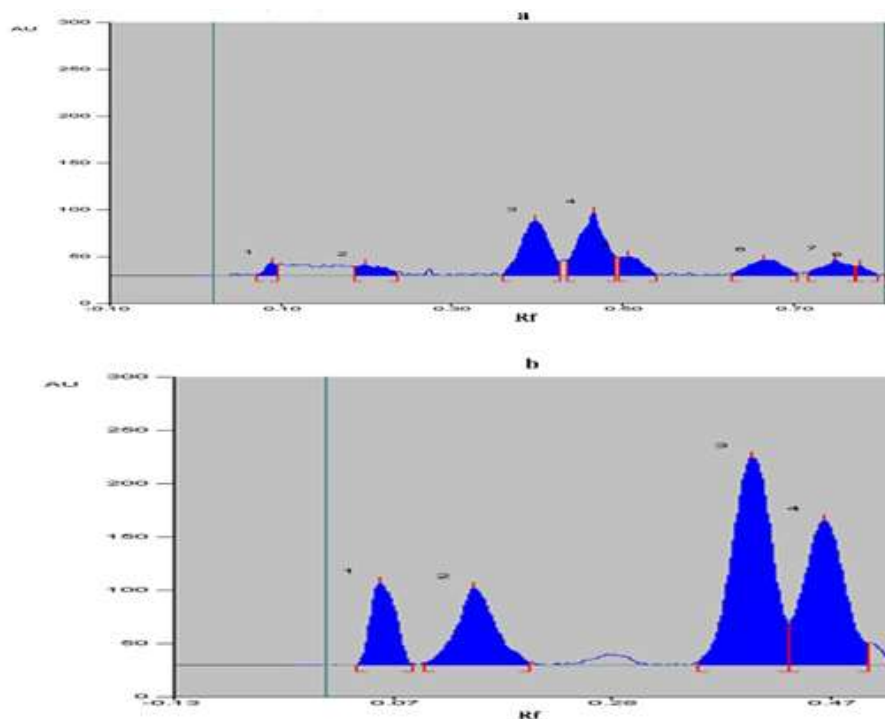


Figure 1. HPTLC fingerprinting graph of EFEE and EFCF (a) HPTLC fingerprinting graph of EFEE (b) HPTLC fingerprinting graph of EFCF

2.4. Effect of EFEE and EFCF on acute arthritic models

On injecting formaldehyde an acute reaction was observed followed by the hyperemic and edematous response in rats, signifying the establishment of acute arthritis. The outcome of joint odema from 0th to 10th day in rats were presented in Figure 2 after comparison with arthritic control. Group II observed with paw volume to be (3.45 ± 0.68 - 3.66 ± 0.59). Aspirin treated Group III anticipated with declined in the paw level (2.60 ± 0.71 - 1.00 ± 0.69 ; $p < 0.001$). There is noteworthy diminution in paw level in Group VII (2.73 ± 0.61 - 1.20 ± 0.93 ; $p < 0.001$), besides Group V (3.08 ± 0.55 - 1.89 ± 0.84 ; $p < 0.01$) and Group IV (3.20 ± 0.57 - 2.25 ± 0.62 ; $p < 0.01$). Group VI also revealed substantial reduction, (2.92 ± 0.93 - 1.53 ± 0.51 ; $p < 0.001$), Figure 2(a). The level of enlargement anticipated by analysing paw thickness (diameter) in Group II was (5.92 ± 0.99 - 6.44 ± 0.95). Substantial decline in swelling was anticipated in Group III (5.28 ± 0.24 - 3.40 ± 0.40 ; $p < 0.001$). Group IV was observed with higher incidence of swelling (5.70 ± 0.88 - 4.76 ± 0.43 ; $p < 0.01$) besides Group V (5.58 ± 1.23 - 4.55 ± 0.66 ; $p < 0.001$). The rats experimented with fraction were anticipated with substantial diminution in paw swelling (5.39 ± 0.73 - 3.72 ± 0.58 ; $p < 0.001$) Figure 2(b).

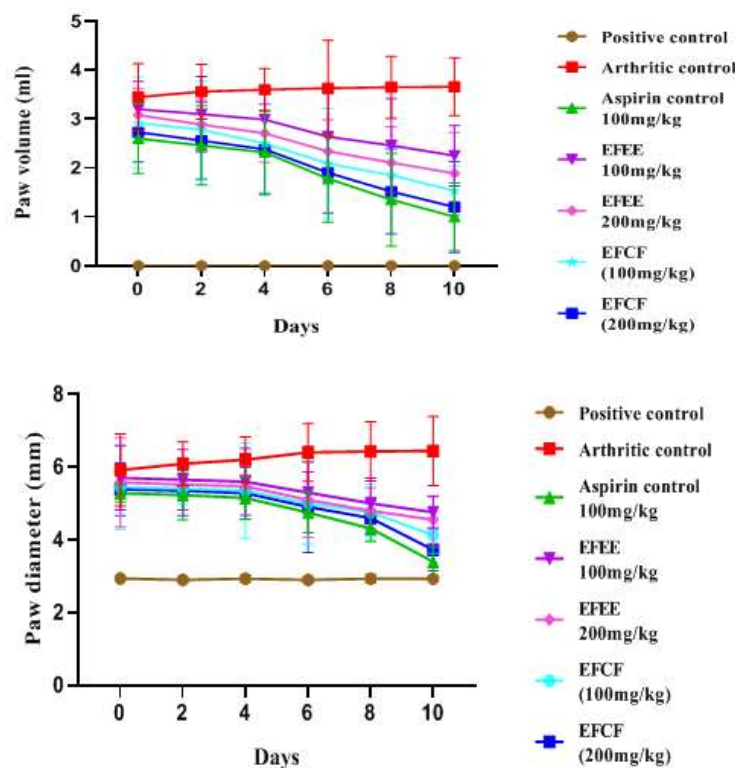


Figure 2. (a) Effect of EFEE & EFCF of *E. ferox* on paw volume in formaldehyde induced arthritic model (b) Effect of EFEE & EFCF of *E. ferox* on paw diameter in formaldehyde induced arthritic model

The outcome of extract and fraction on turpentine provoked joint odema in rats from 0 to 6hrs was presented in Figure 3. Considerable swelling in paw with respect to volume was estimated in Group II as (2.70 ± 0.87 - 3.16 ± 0.43) followed instantaneously by injection. Group VII was likely to be observed with diminution as (1.32 ± 0.152 to 1.10 ± 0.66 ; $p < 0.001$) after 4 hours. Group VI (2.40 ± 0.94 - 1.25 ± 1.29 ; $p < 0.01$) and group V (2.52 ± 0.40 - 1.30 ± 1.23 ; $p < 0.01$) were likely to be observed with moderate diminution in paw width (diameter). In assessing paw width, Group II was anticipated with utmost swelling as (6.80 ± 1.24 - 7.71 ± 1.69). The swelling steadily falls in Group III above 6 h (5.92 ± 1.73 - 3.56 ± 0.69 ; $p < 0.001$). From the experiment it was anticipated a substantial diminution in swelling for fraction group (6.05 ± 0.24 to 3.69 ± 0.91 ; $p < 0.001$) besides Group V (6.32 ± 1.56 - 4.10 ± 1.44 ; $p < 0.01$).

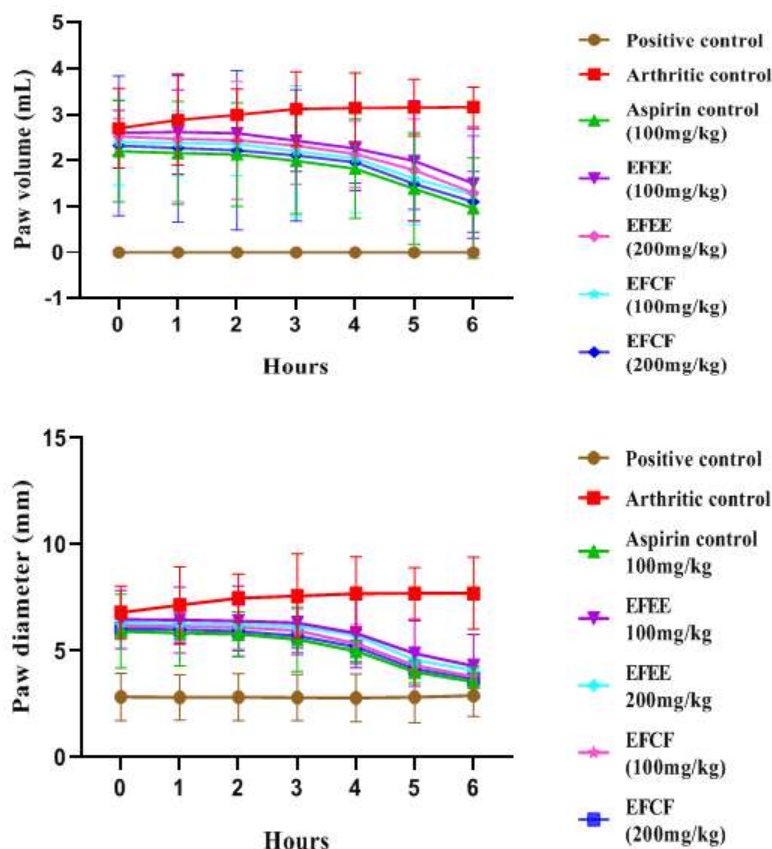


Figure 3. (a) Effect of EFEE & EFCF of *E. ferox* on paw volume in turpentine oil induced arthritic model. (b) Effect of EFEE & EFCF of *E. ferox* on paw diameter in turpentine oil induced arthritic model.

2.5. Effect of EFEE and EFCF in CFA induced arthritic model

2.5.1. Paw swelling

As demonstrated in Figure 4, rats developed persistent arthritis in their left hind paw. In paw volume, Group II demonstrated significant edema soon after injection on all of the experimental days. Group VII EFCF fraction 200 mg/kg b.w (2.25 ± 1.33 - 0.95 ± 1.70 ; $p < 0.001$), observed with ample diminution in paw volume for 28 days besides Group VI EFCF 100 mg/kg b.w (2.32 ± 1.14 - 1.04 ± 1.38 ; $p < 0.001$), Group V EFEE 200 mg/kg b.w (2.42 ± 1.28 - 1.23 ± 1.56 ; $p < 0.01$), Group IV EFEE 100 mg/kg b.w (2.48 ± 1.16 - 1.23 ± 1.89 ; $p < 0.01$). Group III observed with diminution in swelling as (2.18 ± 1.19 to 0.81 ± 1.02 ; $p < 0.001$).

On the 0th day, paw diameter was calculated in all groups. In Group VII, the paw diameter decreased significantly (5.22 ± 1.73 - 3.85 ± 1.65 ; $p < 0.001$). In Group VI fraction at 100mg/kg b.w. rats had a lower paw diameter reduction (5.32 ± 1.29 - 4.11 ± 1.58 ; $p < 0.001$). Group IV observed with swelling as (5.60 ± 1.36 - 4.39 ± 1.40 ; $p < 0.01$) and Group V as (5.49 ± 1.56 - 4.23 ± 0.77 ; $p < 0.01$) indicated a slight reduction in paw diameter.

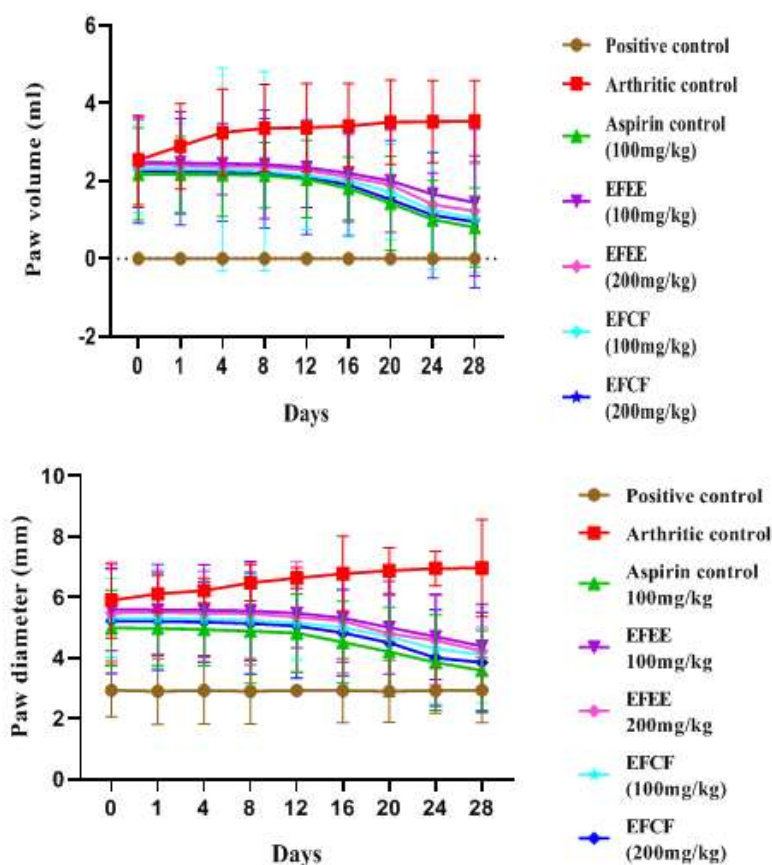


Figure 4. (a) Effect of EFEE & EFCF of *E. ferox* on paw volume in CFA induced arthritic model (b) Effect of EFEE and EFCF of *E. ferox* on paw diameter in CFA induced arthritic model

2.5.2. Body weight

This experiment revealed a correlation amongst paw inflammation and body weight. The fact that arthritis was developed on all trial days was confirmed by the loss in body weight in Group II (154.64 ± 4.32 to 133.89 ± 3.02) which is significant. In CFA-induced rats, there are no substantial variation in body weight of rats after the action of EFEE and EFCF. The results were depicted in Figure 5.

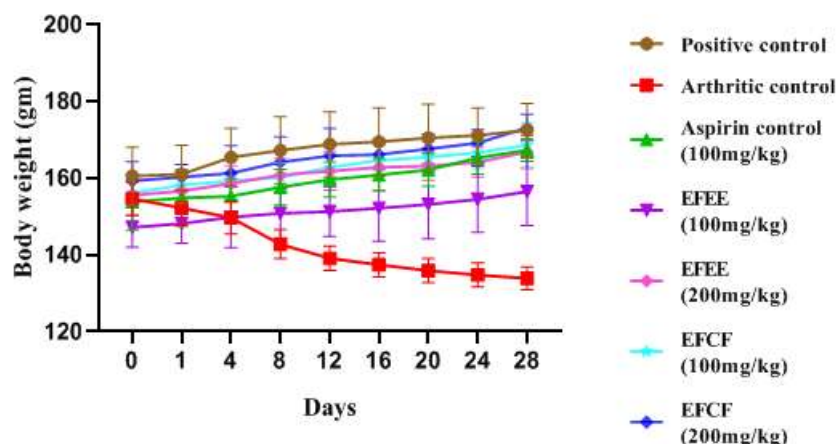


Figure 5. Effect of EFEE and EFCF of *E. ferox* on body weight in CFA induced arthritic model

2.5.3. Arthritic scoring system

The severity was scored by visual illustration on days 4, 16 and 28. The fraction treated group EFCF at 200mg/kg shows mild edema with score 1 and is considered to be comparable with the aspirin treated group which also shows mild edema. The maximum score was observed to be 4.

2.5.4. Hematological parameters

The blood samples of all groups were tested for blood factors, 28 days after CFA treatment to rats. WBC (7.44 ± 0.27 - 14.22 ± 0.18), Platelet count (3.83 ± 0.35 - 10.43 ± 0.26), CRP levels (1.46 ± 0.36 - 7.54 ± 0.52), and Rf value (0.00 ± 0.00 - 53.50 ± 2.88) increased in the CFA treated group, whereas hemoglobin (14.93 ± 1.13 - 9.3 ± 0.28) and RBC count (5.00 ± 0.86 - 3.43 ± 0.40) decreased. In the lead with arthritic control group, Group III were observed with diminution WBC as (14.22 ± 0.18 - 8.41 ± 0.23 ; $p < 0.001$), platelet count (10.43 ± 0.26 - 5.66 ± 0.78), CRP levels (7.54 ± 0.52 - 2.67 ± 1.07 ; $p < 0.001$), Rf value (53.50 ± 2.88 - 34.50 ± 1.87 ; $p < 0.001$) but improved Hb value as (9.38 ± 0.28 - 14.69 ± 0.43) and RBC value as (3.43 ± 0.40 - 6.55 ± 0.32 ; $p < 0.001$). The group experimented with fraction at 200 mg/kg b.w likely to be observed with substantial rise in RBC value as (3.43 ± 0.40 - 6.55 ± 0.22 ; $p < 0.001$) and hemoglobin (9.38 ± 0.28 - 14.61 ± 0.47 ; $p < 0.001$) but dwindled WBC (14.22 ± 0.18 - 9.53 ± 0.13 ; $p < 0.001$), platelet value (10.43 ± 0.26 - 6.46 ± 0.33), CRP value (7.54 ± 0.52 - 3.46 ± 0.62 ; $p < 0.001$) and Rf (53.50 ± 2.88 - 37.50 ± 1.81 ; $p < 0.001$) besides with group experimented with fraction at 100 mg/kg b.w in RBC value (3.43 ± 0.40 - 7.74 ± 0.14), haemoglobin (9.38 ± 0.28 - 13.55 ± 0.42), WBC (14.22 ± 0.18 - 10.46 ± 0.21), platelet count (10.43 ± 0.26 - 7.62 ± 0.25 ; $p < 0.01$), CRP value (7.54 ± 0.52 - 4.26 ± 0.31) and Rf (53.50 ± 2.88 - 40.66 ± 1.21 ; $p < 0.001$). The group experimented with extract at 200 mg/kg b.w. anticipated with less variation in RBC value (3.43 ± 0.40 - 7.23 ± 0.10), hemoglobin (9.38 ± 0.28 - 12.38 ± 0.30 ; $p < 0.01$), WBC (14.22 ± 0.18 - 11.40 ± 0.17 ; $p < 0.01$) Platelet count (10.43 ± 0.26 - 8.58 ± 0.29), CRP value (7.54 ± 0.52 - 4.43 ± 0.16) and Rf (53.50 ± 2.88 - 43.16 ± 1.16 ; $p < 0.01$) besides with the group experimented with 100 mg/kg b.w in RBC value (3.43 ± 0.40 - 8.31 ± 0.24), hemoglobin (9.38 ± 0.28 - 11.51 ± 0.23), WBC (14.22 ± 0.18 - 12.46 ± 0.20 ; $p < 0.05$), platelet count (10.43 ± 0.26 -

9.67±0.61; $p < 0.05$), CRP value (7.54±0.52-5.53±0.37; $p < 0.05$) and Rf (53.50±2.88-47.16±1.72; $p < 0.05$). The results were depicted in Figure 6.

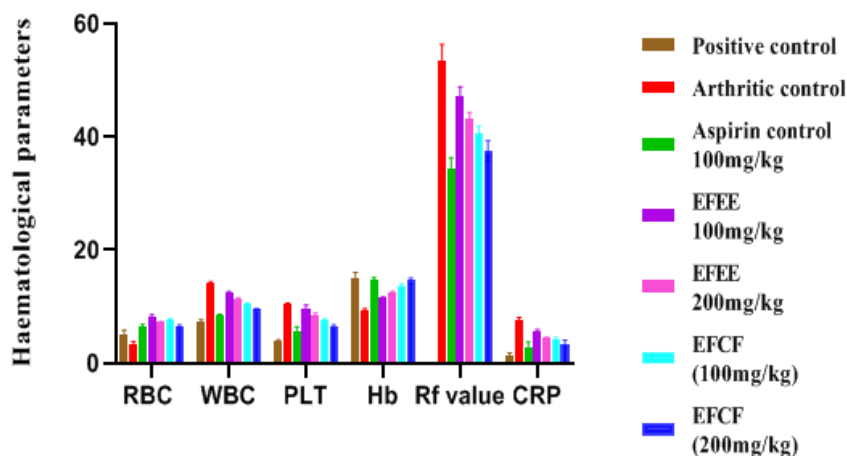


Figure 6. Effect of EFEE and EFCF of *E. ferox* on hematological parameters in CFA induced arthritic rats

2.5.5. Biochemical parameters

AST, ALP, and ALT were measured in 28 days following CFA injection in all groups. The CFA-induced rat had substantially higher AST (34.00±2.19-212.00±5.54), ALT (42.92±1.79- 176.33±4.50), and ALP (77.50±5.75-417.78±28.16). The group experimented with aspirin anticipated diminuted levels of serum enzyme marker besides with arthritic control as values to be, AST (212.00±5.54-68.33±4.96), ALT (176.33±4.50-54.56±0.53), ALP (417.78±28.16-133.16±4.57). Upon experimentation with extract at 100 mg/kg b.w. the levels of AST (212.00±5.54-193.16±2.92), ALT (176.33±4.50-91.22±0.78), ALP (417.78±28.16-303±2.36) decreases. Experimentation with extract at 200 mg/kg b.w, AST (212.00±5.54- 158.33±5.31; $p < 0.05$), ALT (176.33±4.50-75.00±0.52), ALP (417.78±28.16-242.33±3.07; $p < 0.05$) were also decreases. Noteworthy variations were seen in experimented levels by Group VII, AST (212.00±5.54-85.33±4.13; $p < 0.001$) ALT (176.33±4.50-61.28±0.81; $p < 0.001$), ALP (417.78±28.16-205.83±1.83; $p < 0.01$) as compared with Group VI, AST (212.00±5.54- 111.66±5.3; $p < 0.01$), ALT (176.33±4.50-71.10±0.64; $p < 0.001$), ALP (417.78±28.16- 239.66±4.03; $p < 0.01$). The results were shown in Figure 7.

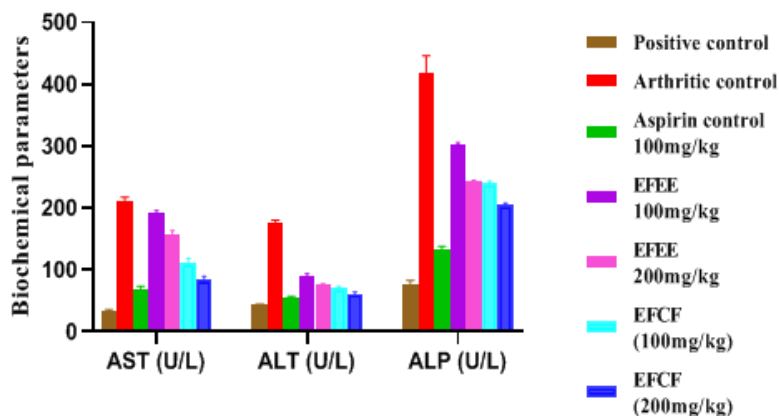


Figure 7. Effect of EFEE and EFCF of *E. ferox* on biochemical parameters in CFA induced arthritic model

2.5.6. Histopathological analysis

In histopathological study, no inflammation with few lymphocytes infiltration, no bone deterioration in the left hind paw of rats was observed in Group I (Figure 8A). In the arthritic control group, there was a large influx of inflammatory cells into the synovial cavity, with lymphocytes, plasma cells, and some macrophages predominating, producing lymphoid follicles, fibrin deposition, pannus formation and marked thickening of the synovial membranes in (Figure 8B). Group III treated rats showed significant decreased inflammatory cells, reduced fibrin deposits, no pannus formations in (Figure 8C). Group IV and Group V showed declined inflammatory cells and minor fibrin deposits as in (Figure 8D). Group VI showed little inflammatory cells and minor fibrin deposits as in (Figure 8E). Group VII showed little inflammatory cells with no fibrin deposits, limited input of inflammatory cells, reduced villous hypertrophy and no pannus development, hence the rats paw showed substantial protection against bone necrosis as shown in (Figure 8F).

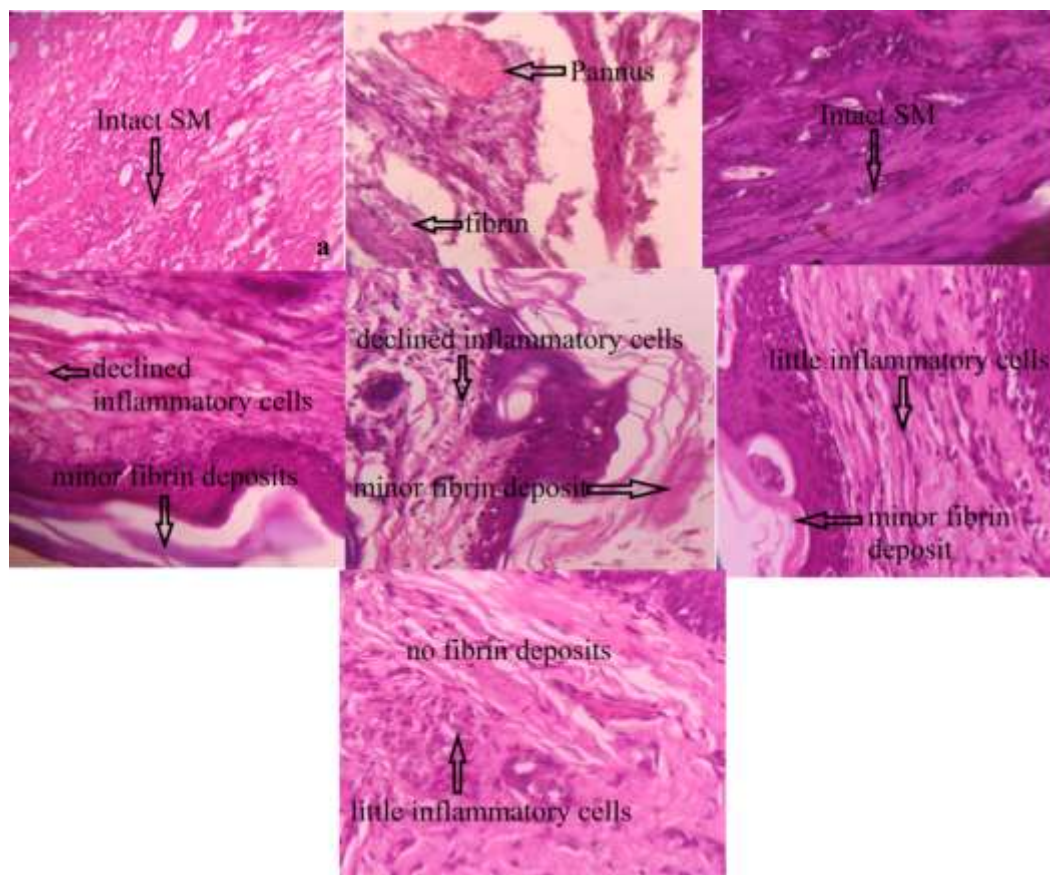


Figure 8. Histopathological analysis of ankle joints (A) positive control. (B) arthritic control (C) aspirin control (D) EFEE 100mg/kg (E) EFEE 200mg/kg (F) EFCF 100mg/kg (G) EFCF 200mg/kg. SM: synovial membrane

3. DISCUSSION

The plant *Euryale ferox* mostly used in traditional medicine for ameliorating the symptoms associated with rheumatoid arthritis, but there are no scientific studies supporting the claimed use. Hence, the current experiment was accomplished to examine the antiarthritic effect of ethanolic extract and chloroform fraction of the plant in arthritic model. Phytochemical studies and qualitative HPTLC analysis established the existence of diversified phytoconstituents in ethanolic extract (EFEE) and its fraction (EFCF). The results on acute toxicity studies consider that *Euryale ferox* is safe upto the maximum dose including 5000mg/kg hence two doses were selected viz 100mg/kg b.w and 200mg/kg b.w for the study. In acute arthritic models the animals were treated orally with the extract and its fractions. Paw swelling were estimated by using formaldehyde and turpentine induced arthritic models. Earlier studies suggested that formaldehyde-induced arthritis is one of the most often used acute non-immunological arthritis models for studying a plant extract's antiarthritic properties [16]. Formaldehyde causes localized inflammation as well as distinctive biphasic pain considering initial neurogenic pain followed by tissue intervened discomfort. Substantial diminution in paw edema was considerable in formaldehyde induced arthritic model after 6th day of treatment with extract and its fraction. With turpentine induced arthritic model, earlier studies

suggests that acute inflammatory response is localized to the limited area where the tissue damage occurs which is linked with the assemblance of inflammatory mediators considering histamine and serotonin in the initial stages, kinin-like compounds and prostaglandins in the ensuing stages [17]. In this study, the group experimented with fraction at 200 mg/kg b.w. anticipated with declined immediate inflammatory effect in the joint of rats showing invigorating response in dose-dependent manner.

Another animal model used in this study to test antiarthritic efficacy is CFA induced arthritic model, having analogous clinical and pathological variations as anticipated in human RA. As anticipated, the infiltrated inflammatory cells containing nitrogen, proteases, and other reactive oxygen species provokes tissue degeneration and lead to chronic inflammation [18]. In this study, EFCF treated animals showed decreased cell infiltration, reduced pannus formation and lessened fibrin deposits possibly due to decreased levels of reactive species. In this technique, the arthritis model allows researchers to investigate degenerative changes in tissues other than joints. Scientific explorations consider that in RA, anemia is the most frequent extracellular symptom which is produced by a drop in plasma iron levels leading to bone marrow failure. Moreover, high amount of cytokines instigates macrophages to engulf premature erythrocytes causing impaired level of erythrocyte in plasma [19]. However, there was a significant increase in Hb and RBC count after treatment with EFCF 200 mg/kg b.w fraction, indicating a invigorating effect in arthritis.

Alternatively, an increase in leukocyte count (White blood cell, WBC) in RA is due to liberation of neutrophils from bone marrow in inflammatory conditions. The mobility of neutrophils probably activates inflammatory mediators including TNF α , IL-6, IL-17 which leads to chronic inflammation [20]. In this study EFCF treated rats shows ameliorating effect in WBC count. As postulated in earlier studies that platelets contribute to inflammatory responses leading to generalized and localized fibrin deposition and accumulation [21]. Scientific explored literature suggests that an elevated CRP level and Rf factor signifies the rate of disease progression in RA. CRP considered as a biological marker in assessment of RA and worsens the damaged joint by binding to the glycoproteins viz., fibrinogen which is prone to be present at the site of inflammation [22]. The EFCF treated rats diminished the elevated values of CRP and Rf factor. Weight loss in rheumatoid arthritis is considered to be due to cytokine production which elevates resting metabolic rate and protein breakdown. In this test, the arthritic group exhibited slight reduction in body weight which gets restored on treatment with EFCF. Arthritic score is feasible to determine long term damage of joints. In the present study, arthritic score 4 indicates loss of functionality of joints which was observed in arthritic group. However experimentation with EFCF restored the manifestations associated with RA.

The intensity of serum enzyme markers including AST, ALT, ALP provide an effective and easy method for evaluating anti-arthritic potential. As per earlier reported literature in adjuvant arthritis in rats, the activities of aminotransferases and ALP, excellent indicators of liver and kidney damage, rise considerably [23]. In addition to the fact that serum alkaline phosphatase activity increased with RA pathogenicity, AST would considerably releases bradykinin throughout the inflammatory progression [24]. This enzyme, which is released into the bloodstream during bone production and resorption, is implicated in localised bone loss such as periarticular osteopenia [25]. In this investigation, arthritic rats had considerably higher ALP, AST, and ALT levels, but elevated levels of these enzymes were dramatically reduced in animals given EFCF at 200mg/kg b.w. On the basis of histopathological findings, the

antiarthritic potential of *Euryale ferox* salisb is well demonstrated by the reduction of joint inflammation and cell proliferation. Since this study is limited at preclinical basis, there is need to ascertain antiarthritic mechanism at molecular level.

4. CONCLUSION

Euryale ferox salisb has potential antiarthritic effect in the presented experimental work. The possible effects on arthritis could probably be interrelated with the existence of flavonoid and phytosterols present in the ethanolic extract and chloroform fraction. Hence this study supports the pharmacological facts to reported traditional claim of the plant in the management of manifestations related to arthritis.

5. MATERIALS AND METHODS

5.1. Plant collection

The aerial parts of plant *Euryale ferox* salisb were collected during the month of November 2020 from ICAR-RCER Research Center for Makhana, Darbhanga, Bihar. Further, botanical identification was conducted by taxonomist at Botanical Survey of India, CRC, Prayagraj (U.P.). A plant specimen was placed in the herbarium for future reference with Accession No. (BSA) 104701.

5.2. Drugs, chemicals and instruments

Complete Freund's adjuvant (CFA) was purchased from Sigma-Aldrich, USA. Aspirin was obtained from Global Influence, New Delhi, as a gift sample. Sodium chloride, turpentine oil, formaldehyde and other chemicals and solvents taken are AR grade and were purchased from K.D Pharma, Gujrat. The instruments for experiment used were Plethysmometer (Kent Scientific), Vernier caliper (Asahi), CAMAG HPTLC system (Mutenz, Switzerland) comprising of Hamilton 100µl syringe, Linomat IV applicator, twin trough developing chamber (20 X 20 cm).

5.3. Extraction and fractionation

Pulverized leaves (500g) were extorted considering 50%v/v ethanol by continuous extraction process in Soxhlet apparatus at 60°C. The yield was anticipated to be 39.8% w/w. Fractionation was made by amalgamating 100 g of relic with water and n-hexane, chloroform, ethyl acetate and methanol (1:1) by considering successive liquid-liquid partitioning method in a separating funnel. The n-hexane (EFH), chloroform (EFC), ethyl acetate (EFEA) and methanol (EFM) fractions were obtained and intensified considering rotavapour (Buchi, USA) at <400°C. The yield of chloroform fraction was 32.32% w/w.

5.4. Preliminary phytochemical screening and TLC

EFEE and EFCF was tested for preliminary phytochemical screening and TLC considering Silica Gel 60 to be stationary phase by using standard procedures [26]. Under UV chamber at 254 nm, 365 nm and visible light the plates were experimented for spots considering Ethyl acetate: toluene: formic acid (2:7:1

v/v/v) at 254 nm. EFEE showed (03) spots and subjected for further fractionation. Then-hexane (EFH), chloroformic (EFC), ethyl acetate (EFEA) and methanol (EFM) fractions were also tested. In EFCF, four spots were observed at 254 nm hence considered for anti-arthritic activity.

5.5. Characterization of ethanolic extract and its fraction

The ethanolic extract and chloroform fraction were analyzed qualitatively by HPTLC fingerprinting method. 10 µl of 50% ethanolic extract (EFEE) and its chloroform fraction (EFCF) were spotted on HPTLC plates. The plates were developed at 254nm using mobile phase ethyl acetate: toluene: formic acid (2:7:1 v/v/v).

5.6. Experimental animals

Young healthy male albino wistar rats weighing 180–210 g were kept in polypropylene cages for 12 h light and 12 h dark cycle at 25±2 °C in the animal facility of United Institute of Pharmacy, Allahabad. Prior the experiment all animals were acclimatized for five days and fed with standard laboratory pellet diet and water ad libitum. The experimental protocol was approved by the Institutional Animal Ethical Committee of United Institute of Pharmacy with approval number (REG. No: UIP/IAEC/Nov-2020/13).

5.7. Toxicity study of the plant

The lethal median dose (LD50) assessment was performed in rats by OECD guidelines [27]. A single dose of the extract (5, 50, 300, 2000 and 5000 mg/kg) in 1% gum acacia was given orally by gavage to different group of animals (three each). The animals were regularly observed every hour during the first 12 h throughout the study period (14 days) for any abnormal changes.

5.8. Experimental induction of arthritis

Induction of arthritis has been performed as per our previous work [28]. Briefly, Arthritis was induced intraplantarally in left hind paw after 30 min of drug/vehicle administration to all the rats. Suspensions of Standard drug aspirin, extract and its fractions were prepared in 1%w/v gum acacia and administered orally to rats. Formaldehyde solution (2%v/v) and Turpentine emulsion (10%v/v) were made in 0.9% saline.

5.9. Acute arthritic model

5.9.1 Formaldehyde induced arthritic model

Seven groups of rats (n=6) were used for the study. Group I considered as positive control rats, given vehicle, Group II considered as arthritic control rats given 0.1 ml of 2% formaldehyde solution, Group III was arthritic rats treated with the standard drug aspirin at 100 mg/kg body weight, Group IV was arthritic rats treated with extract (EFEE) 100 mg/kg body weight, Group V was arthritic rats treated with extract (EFEE) 200 mg/kg body weight, Group VI was arthritic rats treated with fraction (EFCF) 100 mg/kg body weight, Group VII was arthritic rats treated with fraction (EFCF) 200 mg/kg body weight.

On day 0, 2, 4, 6, 8, and 10, the anti-arthritic activity of EFEE and EFCF was assessed on the injected paw using the parameters paw volume and joint diameter.

EFEE and EFCF evaluated for anti-arthritic activity by measuring paw volume and joint diameter every hour for up to 6 hours.

5.10. Chronic arthritic model

5.10.1 Complete Freund's adjuvant arthritic model

Anti-arthritic activity of EFEE and EFCF was evaluated on injected paw on the following parameters paw volume, joint diameter, body weight and arthritic score on day 0, 1, 4, 8, 12, 16, 20, 24, and day 28. Inference of various parameters were considered by withdrawing the blood by retro-orbital puncture on 28th day.

5.10.2 Arthritic scoring system

The arthritis scoring system was considered for assessing the condition of arthritis [29]. The arthritis score was considered from 0 to 4 in which, 0 = normal paw; 1 = mild swelling and erythema; 2 = swelling and erythema; 3 = severe swelling and erythema; 4 = gross distortion and lack of ability.

5.10.3 Hematological and serum parameters

The parameters were assessed as per our previous work [28]. Briefly, blood of the rats was withdrawn by retro-orbital puncture on 28th day. The collected blood samples were centrifuged at 2500 rpm for 15 min. The serum was collected in fresh serum tubes and stored in refrigerator (2–4°C) after tightly capped and subjected to biochemical and hematological examination for AST, ALT, ALP levels, red blood cell (RBC) count, white blood cell (WBC) count, haemoglobin (Hb), and platelets (PLT). Serum C-reactive protein (CRP) and Rheumatoid factor (RF) level. The parameters were also measured using diagnostic kits (Erba Lachema).

5.10.4 Histopathological analysis

The histopathological analysis were performed as per our previous work [28]. Briefly, the control as well as treated rats were sacrificed by using cervical dislocation and the ankle joint was removed, immediately fixed in bouin's fluid for 24 h and washed in running tap water to remove colour of bouin's fluid and dehydrated in alcohol embedded in paraffin and cut at 5 µm in a rotary microtome. The joint sections were then deparaffinized in xylene and stained with eosin haematoxylin stain and viewed under 40X magnifications. The snaps of histopathological slides were captured with a Nikon E400 microscope (Chiyoda, Tokyo, Japan).

5.11 Statistical analysis

Data was expressed as mean \pm SD and statistical analysis was carried out by using GraphPad Prism 9.1.2 software by applying two-way ANOVA with Newman-Keuls method. $P < 0.001$ was considered to be significant.

Acknowledgements: Authors acknowledges the contribution of Dr. Arti Garg (Scientist E) BSI, Prayagraj in authentication of plant material and United Diagnostic Centre, Allahabad for serving their practical hands for estimating the serum parameters and histopathology. The authors also acknowledge United Institute of Pharmacy, Allahabad for animal authentication as per CPCSEA guidelines for providing the animal house facility to carry out in vivo experiments. The authors also acknowledge Biotech Park, Lucknow for providing the HPTLC fingerprinting data.

Author Contribution: Concept – S.S., V.C., S.B.M.; Design – S.S., S.B.M., V.C.; Supervision – S.S., S.B.M., V.C.; Resources – V.C., A.K.S., S.S.; Materials – V.C., A.K.S., S.B.M.; Data Collection and/or Processing – V.C.; S.S., S.B.M.; Analysis and/or Interpretation – S.B.M., S.S., V.C.; Literature Search – A.K.S., S.B.M., S.S., V.C.; Writing – S.S., S.B.M., V.C.; Critical Reviews – S.S., V.C., S.B.M., A.K.S.

Conflict of Interests: The authors declared no conflict of interest in the manuscript.

REFERENCES

- [1] Jeffrey AS. Rheumatoid arthritis. Ann Intern Med. 2019; 170(1): ITC1-ITC16. [CrossRef]
- [2] Tripathi KD, Essentials of Medical Pharmacology, eighth ed., Jaypee Brothers Medical Publishers, New Delhi 2019.
- [3] Tabish SA. Complementary and alternative healthcare: Is it evidence-based?. Int J Health Sci (Qassim). 2008; 2(1): V-IX.
- [4] Nehal N, Mann S, Gupta RK. Two promising underutilized grains a review. Indian J Tradit Knowl. 2015; 14(3): 416-422.
- [5] Mittal R, Sharma S, Mittal A. A critical review on ethnobotanical and pharmacological aspects of *Euryale ferox* Salisb. Pharmacog J. 2020; 12(6): 1444-1454. [CrossRef]
- [6] Ahmed D, Sharma M, Kumar V, Bajaj HK, Verma A. 2 β -hydroxybetulinic acid 3 β -caprylate: an active principle from *Euryale ferox* Salisb. seeds with antidiabetic, antioxidant, pancreas & hepatoprotective potential in streptozotocin induced diabetic rats. J Food Sci Technol. 2015; 52(9): 5427-5441.[CrossRef]
- [7] Baek SH, Nam IJ, Kwak HS, Kim KC, Lee SH. Cellular anti-melanogenic effects of a *Euryale ferox* seed extract ethyl acetate fraction via the lysosomal degradation machinery. Int J Mol Sci. 2015; 16(5): 9217-9235. [CrossRef]

- [8] Das S, Der P, Raychaudhuri U, Maulik N, Das DK. The effect of *Euryale ferox* (Makhana), an herb of aquatic origin, on myocardial ischemic reperfusion injury. *Mol Cell Biochem.* 2006; 289(1-2): 55-63. [CrossRef]
- [9] Negi JS, Jugran V, Kasliwal N. Development of non-effervescent floating matrix tablets based on *Euryale ferox* seeds. *Asian J Pharm.* 2011; 5: 93-100.
- [10] Jana BR, Idris M. Anti-aging amino acids in *Euryale ferox* (Salisb.): a review. *Adv Plants Agric Res.* 2018; 8(1): 39–43. [CrossRef]
- [11] He S, Wang D, Zhang Y, Yang S, Li X, Wei D, Zhang M, Qin J. Chemical components and biological activities of the essential oil from traditional medicinal food, *Euryale ferox* Salisb seeds. *J Essent Oil-Bear Plants.* 2019; 22(1) :73-81. [CrossRef]
- [12] Row LC, Ho JC, Chen CM. Cerebrosides and tocopherol trimers from the seeds of *Euryale ferox*. *J Nat Prod.* 2007; 70(7): 1214-1217. [CrossRef]
- [13] Song CW, Wang SM, Zhou LL, Hou FF, Wang K J, Han QB, Li N, Cheng YX. Isolation and identification of compounds responsible for antioxidant capacity of *Euryale ferox* seeds. *J Agric Food Chem.* 2011; 59(4): 1199-1204. [CrossRef]
- [14] Lee SE, Ju EM, Kim JH. Antioxidant activity of extracts from *Euryale ferox* seed. *Exp Mol Med* 2002; 34(2): 100-106. [CrossRef]
- [15] Kirtikar KR, Basu BD, Indian medicinal plants, second ed., International book distributors, Dehradun, Uttaranchal 2005.
- [16] Fischer BD, Adeyemo A, O-Leary ME, Bottaro A. Animal models of rheumatoid pain: experimental systems and insights. *Arthritis Res Ther.* 2017; 19(1): 146. [CrossRef]
- [17] Opriessnig T, Gimenez-Lirola LG, Halbur PG. Polymicrobial respiratory disease in pigs. *Anim Health Res Rev.* 2011; 12(2): 133-148.[CrossRef]
- [18] Murakami M, Hirano T. The molecular mechanisms of chronic inflammation development. *Front Immunol.* 2012; 3: 323. [CrossRef]
- [19] Libregts SF, Gutiérrez L, de Bruin AM, Wensveen FM, Papadopoulos P, van Ijcken W, Ozgur Z, Philipsen S, Nolte MA. Chronic IFN- γ production in mice induces anemia by reducing erythrocyte life span and inhibiting erythropoiesis through an IRF-1/PU.1 axis. *Blood.* 2011; 118(9): 2578–2588. [CrossRef]
- [20] Sadik CD, Kim ND, Luster AD. Neutrophils cascading their way to inflammation. *Trends Immunol.* 2011; 32(10): 452-460. [CrossRef]
- [21] Ansar W, Ghosh S. Biology of C Reactive Protein in Health and Disease. In: Ansar W, Ghosh S. (Eds). *Inflammation and Inflammatory Diseases, Markers, and Mediators: Role of CRP in Some Inflammatory Diseases.* Springer India Publisher, New Delhi, 2016, pp. 67-101.
- [22] Shadick NA, Cook NR, Karlson EW, Ridker P M, Maher N E, Manson J E, Buring JE, Lee IM. C-reactive protein in the prediction of rheumatoid arthritis in women. *Arch Intern Med.* 2006; 166(22): 2490-2494.[CrossRef]

- [23] Li Y, Kakkar R, Wang J. In vivo and in vitro approach to anti-arthritic and anti-inflammatory effect of crocetin by alteration of nuclear factor-E2-related factor 2/hem oxygenase (HO)-1 and NF- κ B expression. *Front Pharmacol.* 2018; 9: 1341. [CrossRef]
- [24] Yap HY, Tee SZ, Wong MM, Chow SK, Peh SC, Teow SY. Pathogenic Role of Immune Cells in Rheumatoid Arthritis: Implications in Clinical Treatment and Biomarker Development. *Cells.* 2018; 7(10): 161. [CrossRef]
- [25] Rehman Q, Lane NE. Bone loss: Therapeutic approaches for preventing bone loss in inflammatory arthritis. *Arthritis Res.* 2001; 3(4): 221–227. [CrossRef]
- [26] Harborne JB, Method of extraction and isolation: *Phytochemical Methods*, third ed., Chapman & Hall, London, UK 1998.
- [27] OECD, Organisation for Economic Co-operation and Development. https://ntp.niehs.nih.gov/iccvm/suppdocs/feddocs/oecd/oecd_gl423.pdf (accessed on february 8, 2022)
- [28] Singh S, Mishra SB, Mukerjee A. *Clerodendrum serratum* (L.) Moon leaf extract and its chloroform fraction attenuates acute and chronic arthritis in albino rats. *Biocatal Agric Biotechnol.* 2019; 22: 101399.[CrossRef]
- [29] Kumar VL, Roy S, Sehgal R, Padhy BM. A comparative study on the efficacy of rofecoxib in monoarticular arthritis induced by latex of *Calotropis procera* and Freund's complete adjuvant. *Inflammopharmacol.* 2006; 14: 17–21. [CrossRef]