

Nodular mucinosis of the breast: A rare entity

Memenin nodüler müsinözü: nadir bir antite

Andac SALMAN, Leyla CİNEL, Huseyin Kemal TURKOZ, Gamze AKBAS, Tulin ERGUN

ABSTRACT

Nodular mucinosis of the breast (NMB) is an uncommon disease involving the nipple-areolar region. It usually presents with asymptomatic, subcutaneous masses with indolent growth in women. Here, we report a 43-year-old man presented with a subcutaneous growth on the left nipple. Histopathological examination confirmed the diagnosis of NMB. We report our patient in order to point out this rare disease and think that the recognition of this entity is important for both clinicians and pathologists.

Keywords: Breast, Mucinosis, Nodular mucinosis of the breast

ÖZ

Memenin nodüler müsinözü (NM), genellikle meme başı ve areolar bölgeyi etkileyen, nadir görülen bir hastalıktır. Sıklıkla kadınlarda, yavaş büyüme seyri gösteren, asemptomatik, deri altı kitleler halinde ortaya çıkar. Burada, sol meme başında deri altı kitle ile başvuran 43 yaşında bir erkek hasta sunulmaktadır. Histopatolojik değerlendirme sonucunda memenin NM tanısı doğrulanmıştır. Bu olgu, bu nadir hastalığa dikkat çekmek ve klinisyenler ve patoloğlar açısından önemli bu durum hakkında farkındalığın artırılması amacıyla sunulmuştur.

Anahtar kelimeler: Meme, Müsinöz, Memenin nodüler müsinözü

Introduction

Nodular mucinosis of the breast (NMB) is an extremely rare condition affecting the nipple-areolar region. It was first defined in 1998 by Michal et al., and few cases have been reported since then [1-5].

Case Report

A 43-year-old man presented with a two-year-history of subcutaneous growth adjacent to his left nipple. His past medical history was insignificant and there was no history of trauma. The lesion was asymptomatic and was not related to any secretion or purulent discharge. Dermatological examination revealed a 2 cm sized nodule with a firm, rubbery consistency and normal looking overlying skin. Although, the lesion was surgically excised with a presumptive diagnosis of epidermal cyst, a deep seated nodule lacking capsule with distinctive mucinous drainage was noticed during surgery (Figure 1).

Gross examination of the specimen revealed a 2.7x1.5x1 cm-sized, nodule covered by normal skin.

Andac Salman (✉), Tulin Ergun
Department of Dermatology, School of Medicine, Marmara University,
Pendik, Istanbul, Turkey
e-mail: asalmani@f@gmail.com

Leyla Cinel, Huseyin Kemal Turkoz, Gamze Akbas
Department of Pathology, School of Medicine, Marmara University,
Pendik, Istanbul, Turkey

Submitted / Gönderilme: 16.02.2018 Accepted/Kabul: 27.03.2018

On cut surface, dermal, mucinous appearance was determined. Histopathological examination revealed poorly circumscribed, partially lobulated dermal myxoid collection (Figure 2a). The lesion was hypocellular and consisted of few spindle cells, vascular structures and fibrous septae. No mitosis was observed. In between myxoid stroma, sparse breast ducts and muscles were present (Figure 2b–d). The mucin stained positively with Alcian blue stain at pH 2.5 (Figure 2e). Immunohistologically, the lesion was negative for pancytokeratin and S100, but sparsely positive for smooth muscle actin (SMA) and relatively diffuse for CD34 (Figure 2f). A diagnosis of NM of the breast was made upon clinicopathological findings.

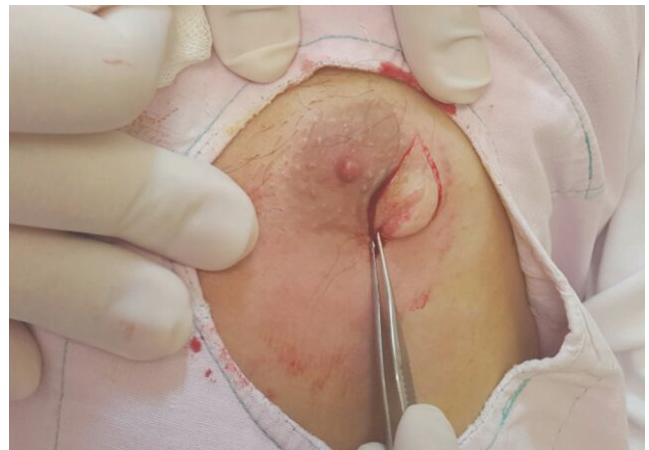

Figure 1. Excision of the subcutaneous nodular lesion adjacent to the left nipple

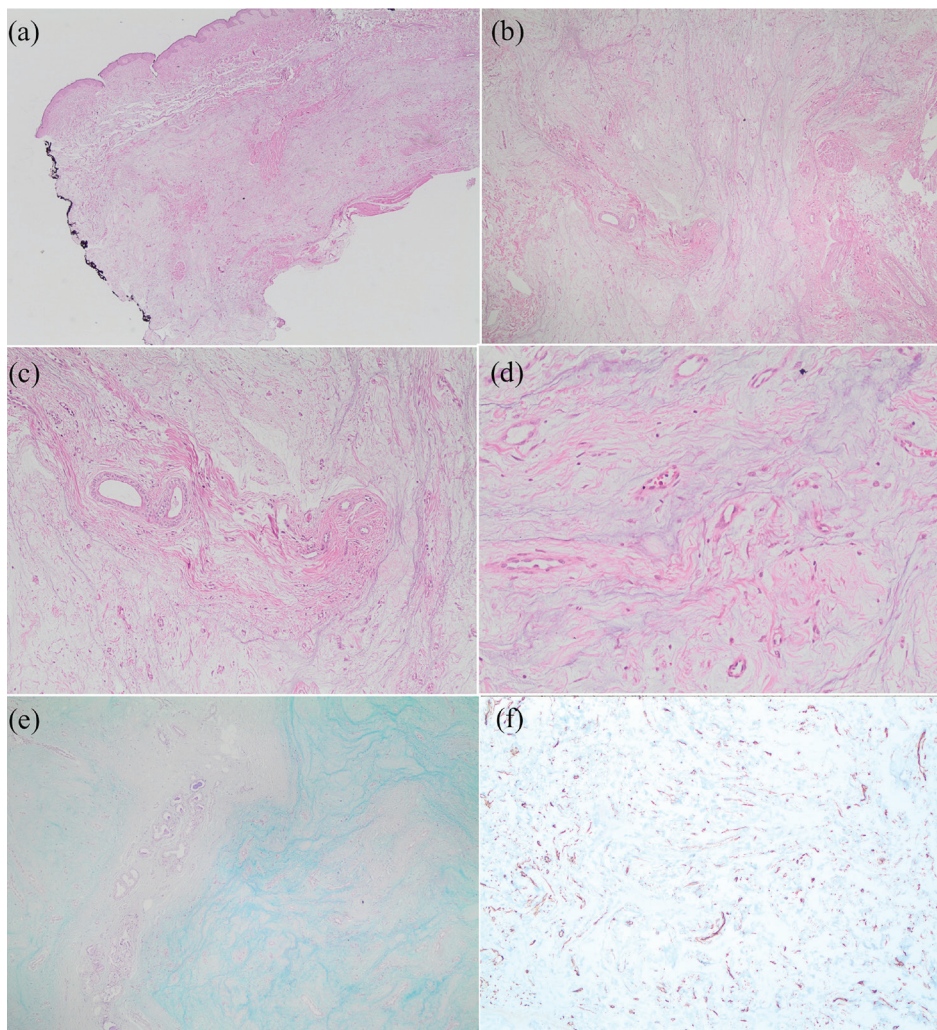


Figure 2. Nonencapsulated myxoid proliferation arise from dermis with surgical margin positivitiy (H&E x20) (a). Breast ducts and muscle bundles are present in the fibrocollagenous bands interlacing the myxoid nodules (H&E x40 and x100). Scattered spindle cells, histiocytes and some dilated vascular structures within the mucinous stroma (H&E x200) (b-d). Strong staining of myxoid tissue with Alcian blue (x40) (e). Positive immunohistochemical staining of the spindle cells and endothelium by CD34 (x40) (f).

Discussion

A recent review of the English literature revealed only 12 cases, 10 of whom were female [5]. Our patient is the third male case reported. The diagnosis of this tumour is challenging as it lacks distinctive clinical features. Physical examination almost always shows 1-6 cm sized, slowly-growing, asymptomatic, subcutaneous masses involving areola, nipple or supernumerary nipple [5]. Dermatological examination of our patient revealed a 2 cm sized nodule with a firm, rubbery consistency. On clinical grounds alone, it may resemble lipoma, neurofibroma, fibroadenoma, nipple adenoma or epidermal cyst as in the present case [3, 5]. Except for the characteristic location, there is no distinctive clinical feature for NMB. However, white colour of the nonencapsulated mass with damp and glistening surface and gelatinous consistency noticed during surgery may be suggestive of NM of the breast. Unlike the cutaneous myxomas, it is not associated with Carney complex or any systemic disease. Histopathological examination and clinical information are essential for a definitive diagnosis of NMB [1, 5]. On microscopic examination, the most characteristic feature is the presence of a nonencapsulated, multinodular myxoid proliferation. In addition, scattered spindle cells, histiocytes and some dilated vascular structures may be noticed within the mucinous stroma. Breast ducts and acini may be present in the fibrocollagenous bands, interlacing the myxoid nodules. The mucin deposition positively stains for alcian blue and colloidal iron. The histopathological differential diagnosis includes cutaneous myxomas, myxoid fibroadenomas, trauma-induced cutaneous focal mucinosis of the areola and mucinous (colloid) carcinoma [1, 5, 6]. Cutaneous myxoma (superficial angiomyxoma) often presents as a solitary polypoid lesion or slightly raised nodule or papule on trunk, head, neck and lower limbs [7]. It may be a manifestation of Carney complex (lentiginos, atrial myxomas, mucocutaneous myxomas and blue nevi). Cutaneous myxomas are poorly circumscribed lesions like NMB, however, microscopically prominent vasculature, fusiform or stellate cells and binucleated or multinucleated cells are seen in 50% of patients. In addition, presence of perivascular neutrophils is a useful diagnostic clue. Myxoid fibroadenomas constitute a histologic subtype of breast fibroadenomas characterized by a distinctive hypocellular stromal component with abundant myxoid matrix. It is usually well circumscribed and consists of a mixture of epithelial and myoepithelial cells. Trauma-induced

cutaneous focal mucinosis of the areola can easily be separated from NMB based on patient's history. Mucinous (colloid) carcinoma of the breast is a rare form of invasive ductal carcinoma. It shows large amount of extracellular mucin with the presence of malignant epithelial cells.

In terms of treatment, surgical excision is the treatment of choice for NMB. Among the previously reported cases, no recurrence was reported during a follow-up period of 6 months to 6 years [5]. Similarly, our patient also remained recurrence-free during six months of follow-up despite the positive surgical margin. Since NMB is not associated with any systemic disease, no further investigations are required.

In conclusion, NMB is a seldom reported disease of the breast with an indolent and benign behaviour. It should be included in the differential diagnosis in the presence of dermal/subcutaneous nodular lesions involving the nipple-areolar complex. Histopathological examination is mandatory to exclude other benign and malignant conditions of the breast presenting with subcutaneous masses.

References

1. Michal M, Ludvíková M, Zámečník M. Nodular mucinosis of the breast: report of three cases. *Pathol Int* 1998;48:542-4.
2. Sanati S, Leonard M, Khamapirad T, Eltorkey MA. Nodular mucinosis of the breast: a case report with pathologic, ultrasonographic, and clinical findings and review of the literature. *Arch Pathol Lab Med* 2005;129:e58-61. doi:10.1043/15432165(2005)129<e58:NMOTBA>2.0.CO;2
3. Manglik N, Berlinger-Ramos AC, Boroumand N, Eltorkey M. Nodular mucinosis of the breast in a supernumerary nipple: case report and review of the literature. *J Cutan Pathol* 2010;37:1178-81. doi: 10.1111/j.1600-0560.2009.01397.x.
4. Chisholm C, Greene JF. Nodular mucinosis of the breast: Expanding our understanding with an unusual case. *Am J Dermatopathol* 2010;32:187-9. doi: 10.1097/DAD.0b013e3181b4a61b.
5. Fernández-Figueras MT, Kazakov D V, López Martos R, et al. Nodular mucinosis of the breast in a male: Reassessment of diagnostic criteria and proposal for its classification as a soft tissue tumor in the myofibroblastoma and spindle cell lipoma spectrum. *Dermatopathology* 2014;1:47-54. doi.org/10.1159/000364859
6. Kempf W, von Stumberg B, Denisjuk N, et al. Trauma-induced cutaneous focal mucinosis of the mammary areola: an unusual presentation. *Dermatopathology* 2014;1:24-8. doi.org/10.1159/000358249
7. Zou Y, Billings SD. Myxoid cutaneous tumors: a review. *J Cutan Pathol* 2016;43:903-doi: 10.1111/cup.12749.