

PRIMARY ADENOCARCINOMA OF THE URINARY BLADDERM.Kadim¹*Plovdiv Medical University*I. Delchev²*Plovdiv Medical University*St. Zdravchev³*Plovdiv Medical University*V. Peev⁴*Plovdiv Medical University*K. Aпти⁵*Plovdiv Medical University*M. Gulanets⁶*Plovdiv Medical University*G. Ivanoc⁷*Plovdiv Medical University***Abstract**

Primary Adenocarcinoma of the bladder is uncommon histological variant of the transitional cell carcinoma and account 0.5% to 2.0% of all malignant vesical tumors.(1) It has an aggressive biological behavior and poor response to chemotherapy and radiotherapy. The only curative option is surgery-radical cystectomy or partial resection.(2)(4) To focus on the existence of rare histological subtype of the transitional cell carcinoma of the urinary bladder and to differ the primary from the secondary “ metastatic ” adenocarcinoma. A 73 years old male with gross hematuria, anemia and renal failure. Ultrasound and CT reveal solid, infiltrative tumor in the trigone with engagement to the left ureteric orifice and ureterohydronephrosis. histologic and immunohistochemical examination of the resected specimen showed primary bladder adenocarcinoma. No radical surgical treatment was performed because of the comorbidity and deteriorated general condition of the patient. We managed percutaneous nephrostomy with chemotherapy and radiotherapy. The malignant degeneration of the urothelium into the rare histological variant “ adenocarcinoma”arises many questions. It is accepted that predisposition for adenocarcinoma exist in patients with bladder extrophy, in areas where infection with Schistosoma is endemic, chronic urine retention, cystitis(3) More common is the secondary “ metastatic” adenocarcinoma from the digestive system and the genital system. This requires detailed clinical investigation of the patients and histologic and immunohistochemical examination of the resected tumor.(5),(6) A number of secondary "metastatic" adenocarcinomas are described such as urachus carcinoma, ring-cell carcinoma, hepatoid adenocarcinoma; metastatic prostate adenocarcinoma and mixed tumors.(7) Despite the scarcely information on rare histological variants of urothelial carcinoma of the urinary Bladder, there is sufficient evidence based on worldwide practice supporting the fact that histological and immunohistochemical subtyping of the tumor is essential in therapeutic and prognostic terms. Primary adenocarcinoma of the bladder is a rare neoplasia of the urothelium with aggressive biological behavior. Tumor is usually manifested in an advanced clinical stage. This limits surgical treatment options in partial resection or radical cystectomy with adjuvant chemotherapy or radiotherapy.

Keywords:

Adenocarcinoma, Urinary bladder, Case Study

1. Correspondence to: M. Kadim, Plovdiv Medical University, urology_kadim@yahoo.com/+359 888 332 603, Plovdiv/Bulgaria.

Introduction

Primary Adenocarcinoma of the bladder is uncommon histological variant of the transitional cell carcinoma and account 0.5% to 2.0% of all malignant vesical tumors.(Somak & Parwani, 2011) It has an aggressive biological behavior and poor response to chemotherapy and radiotherapy. The only curative option is surgery - radical cystectomy or partial resection.(Mello et al., 2015; Shaban et al., 2015; Ghoneim et al., 2008)

Purpose

To focus on the existence of rare histological subtype of the transitional cell carcinoma of the urinary bladder and to differ the primary from the secondary “ metastatic ” adenocarcinoma.

Case Presentation

A 73 years old male with gross hematuria, anemia and renal failure. Ultrasound and CT reveal solid, infiltrative tumor in the trigone with engagement to the left ureteric orifice and ureterohydronephrosis. Endoscopic examination reveals papillary tumors with a broad base, spread to entire bladder trigone and infiltration of the left ostium. Histologic and immunohistochemical examination of the resected specimen showed primary bladder adenocarcinoma.

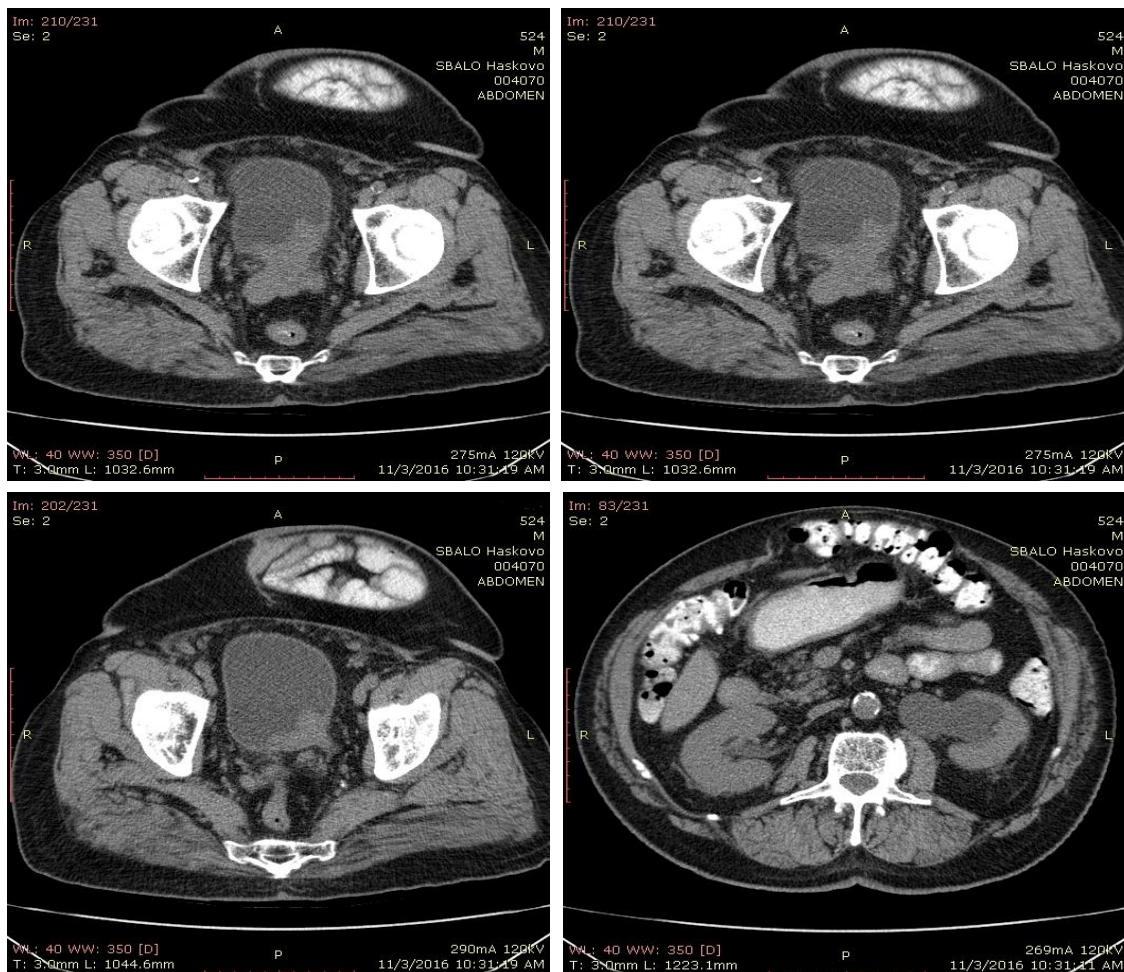


Figure 1. Abdomen Ultrasound Pictures

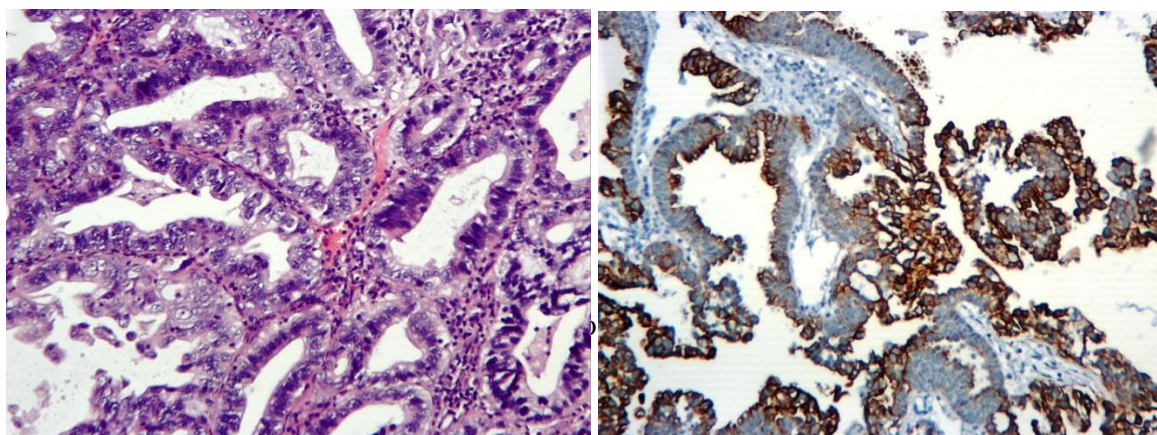


Figure 2. H&E x40 (left) and H&E x100(right)

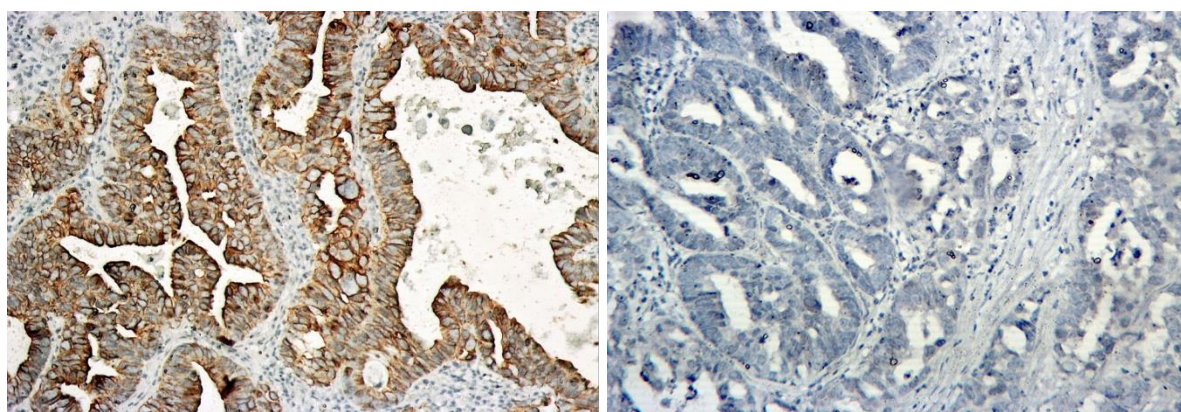


Figure 3. CK7 x100 - diffusely positive (cytoplasmic signal).

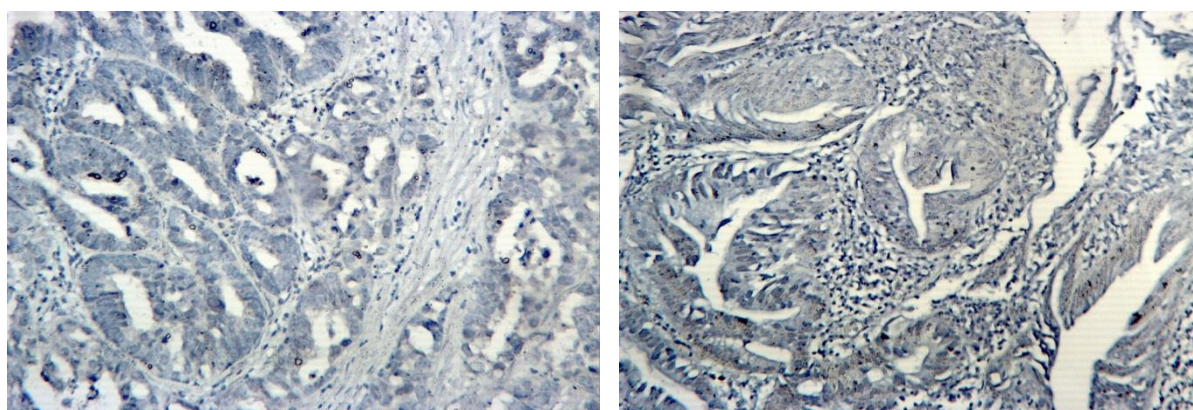


Figure 4. CK20 x100 – negative and PSA x100 - negative

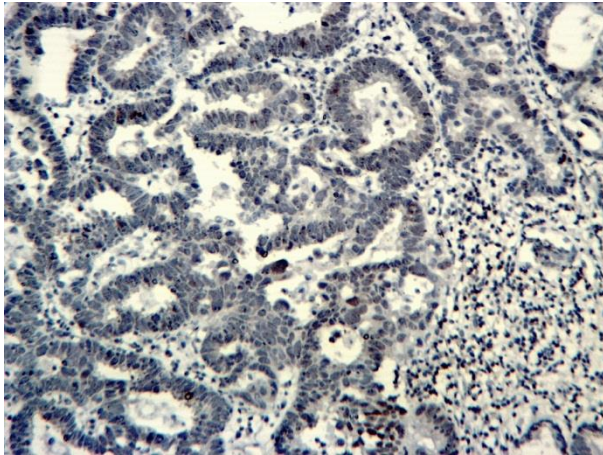


Figure 5. CDX2 x100 - diffusely positive in separate cells (nuclear signal).

Histology and immunohistochemistry / CK7, CK20, PSA, CDX2/: Specimen of bladder wall is sent for pathomorphological examination. The tissue samples for histology were treated with 10% formalin, processed by routine paraffin method and 4 microns thickness of slices, Hematoxylin and Eosin stained. Branched glands of different sizes with remarkable atypism of tumoral growth are spread in almost entire specimen. Great number of irregular mitosis and well-presented stromal reaction are found. No radical surgical treatment was performed because of the comorbidity and deteriorated general condition of the patient. Percutaneous nephrostomy was performed on the side of hydronephrosis, chemotherapy and radiotherapy were proceeded.

Discussion

A literature review of the rare histological subtypes of the bladder carcinoma reveals that malignization of the urothelium in the histological variant “adenocarcinoma” is a rarity. Diseases such as bladder extrophy, chronic inflammatory diseases, chronic urinary retention, endemic diseases such as Schistosomiasis and other factors are prerequisites for the atypical gene mutation of the urothelium and occurrence of adenocarcinoma (Shaaban et al., 2015).

The secondary “metastatic” adenocarcinoma of the intestinal tract and genital tumors in women is more common. Other secondary adenocarcinomas are also described such as urachus carcinoma, ring-cell carcinoma, hepatoid adenocarcinoma, metastatic prostate adenocarcinoma, mixed tumors, etc. (Epstein et al., 2010)

Preliminary exclusion of these locations requires a thorough clinical trial of the patient and a pathohistological - immunohistochemical study of the resected specimen. (Bates & Baithun, 2000; Malicow, 1995).

Despite the scarce information on rare histological variants of urothelial carcinoma of the bladder, there is sufficient evidence based on cases from the world practice supporting the fact, that histological and immunohistochemical subtyping of the tumor is essential in therapeutic and prognostic aspect.

Conclusion

Primary adenocarcinoma of the bladder is a rare neoplasia of the urothelium with aggressive biological behavior. Tumor is usually manifested in an advanced clinical stage. This limits surgical treatment options in partial resection or radical cystectomy with adjuvant chemotherapy or radiotherapy.

References

Bates, A.W. & Baithun, S.I. (2000) Secondary neoplasms of the bladder are histological mimics of nontransitional cell primary tumours: clinicopathological and histological features of 282 cases. *Histopathology*, 36, 32–40.

Bruno Mello R. Santos, Julia Duarte de Souza, * Rachel Silviano Brandão Correa Lima, and Enaldo Melo de Lima. (2015), Mucinous Bladder Adenocarcinoma: Case Report and Literature Review. *Case Rep Urol*. 783109.

Epstein, J.I., Amin, M.B. & Reuter, V.E. (2010) Glandular lesions. In: Epstein JI, Amin MB, Reuter VE, eds. *Bladder Biopsy Interpretation: Biopsy Interpretation Series*. 2nd ed. Philadelphia, PA: Lippincott Williams & Wilkins;150–176.

Ghoneim, M.A., Abdel-Latif, M, El-Mekresh M, Abol-Enein, H., Mosbah A, Ashamallah, A. & El-Baz, M.A. (2008) Radical Cystectomy for Carcinoma of the Bladder: 2,720 Consecutive Cases 5 Years Later. *J Urol*.180:121–127.

Melicow, M.M. (1995) Tumors of the urinary bladder: a clinicopathological analysis of over 2500 specimens and biopsies. *The Journal of Urology*. 7(4), 498-521

Shaaban, A.A., Elbaz, M.A. & Tribukait B. (1998) Primary nonurachal adenocarcinoma in the bilharzial urinary bladder: deoxyribonucleic acid flow cytometric and morphologic characterization in 93 cases. *Am J Clin Exp Urol.*, 3(2): 51–63.

Somak, R. & Anil V. P., (2011) Adenocarcinoma of the Urinary Bladder. *Archives of Pathology & Laboratory Medicine*: 135(12),1601-1605.