

## Giant gluteal lipoma in childhood: a case report

Sevgi Ulusoy Tangül<sup>1</sup>, Sevinç Şahin<sup>2</sup>

<sup>1</sup>Department of Pediatric Surgery, Bozok University School of Medicine, Yozgat, Turkey

<sup>2</sup>Department of Patology, Bozok University School of Medicine, Yozgat, Turkey

DOI: 10.18621/eurj.429131

### ABSTRACT

Lipomas are the most common benign tumors of mesenchyme. They are soft tissue neoplasm and mobile, well-encapsulated tumors. Lipomas are usually grow slowly and rarely reach a size of more than 2-3 cm. Lesions larger than 5 cm, called giant lipomas. They often appear after 40 years old but rarely can occur in childhood. A 12-year-old male patient had a mass showing rapid growth in the right gluteal region at 6 months. Mass was removed with total excision. Postoperative period was uneventful. In the pathology report, it was confirmed that the lipid tissue was composed of mature adipocytes.

**Keywords:** Lipoma, giant lipoma, childhood

*Received: May 31, 2018; Accepted: June 11, 2018; Published Online: June 13, 2018*

Lipomas are the most common benign tumors of mesenchyme; they are composed of mature lipocytes [1]. They are soft tissue neoplasm and mobile, well-encapsulated tumors [2]. Although they can origin in any location where fat cells are found commonly found in the subcutaneous plane of the head, neck, shoulders and back [3]. Lipomas are usually slow growing and rarely reach a size of more than 2-3 cm [2]. Lesions larger than 5 cm, called giant lipomas [4]. They often appear after 40 years old but rarely can occur in childhood [5]. Herein we report a case of 12-year-old male with giant mass showing rapid growth in the his right gluteal region at 6 months.

### CASE PRESENTATION

A 12-year-old male patient presented with complaints of swelling in the right gluteal region. There was a slowly growing mass in the right gluteal region about 6 months. There was no known disease,

trauma and family history in his history. He had no active complaints other than aesthetic complaints and were normal the laboratory parameters. Ultrasonography revealed a 5×6 cm lipoma in the right gluteal region. The patient underwent total excision under general anesthesia. Approximately 8×9 cm yellowish encapsulated lipoma was removed from the subcutaneous fat tissue by excision (Figure 1). The layers were closed one by one after hemostasis. The patient was discharged the same day. There was no problem after a week's checkup. Histopathological examination revealed that the lesion was composed of mature adipocytes, and lipoma diagnosis was confirmed (Figure 2). There was no recurrence in the 6-month follow-up period. The patient's follow-up continue regularly.

### DISCUSSION

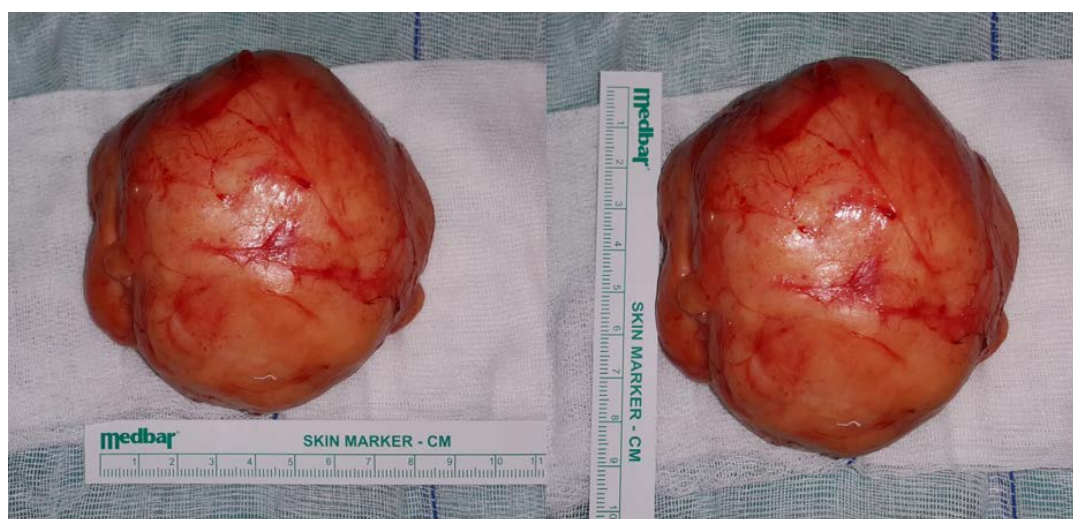
Lipomas are the most common benign



Address for correspondence: Sevgi Ulusoy Tangül, MD., Bozok University School of Medicine, Department of Pediatric Surgery, Yozgat, Turkey  
E-mail: sevguu@gmail.com.

e-ISSN: 2149-3189

Copyright © 2019 by The Association of Health Research & Strategy  
Available at <http://dergipark.gov.tr/eurj>



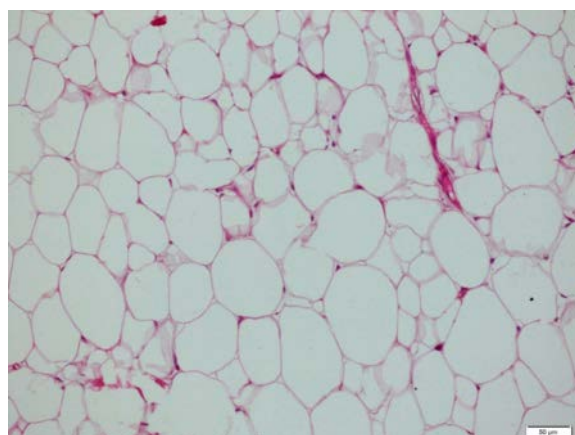
**Figure 1.** The macroscopic appearance of the lesion

mesenchymal tissue tumors and can arise from every region where fatty tissue is involved [1-3]. It is most common in the upper half of the body, especially in the trunk and neck, although it also presents in other regions [1]. These tumors may be of any age, but they are most commonly encountered in the middle ages between 40 and 60 years [3]. Lipomas are rarely seen in the first 2 decades of life, and if they consist, they can be seen any place in the body [6]. The etiology of lipomas are unclear. They are known as both sporadic and hereditary [1]. They can be seen after previous blunt traumas rarely [3]. In our case, there was no known prior history of trauma. The differential diagnosis of childhood masses include lipoblastoma, liposarcoma, angioliipoma, embryonal rhabdomyosarcoma, mycosis and myxoid malignant fibrous histiocytoma [6].

Lipomas are usually 2-3 cm in size. Sometimes lipomas can be greater than 5 cm and called are giant lipomas [2]. In our case, it was giant lipoma and its size was also about 8×9 cm. Lipomas are often asymptomatic but giant lipomas may cause cosmetic troubles. There can be symptoms which are related to vessels and nerves pressure [3]. In our case the patients had only cosmetic troubles.

Imaging methods can be used for the diagnosis of lipomas. The most commonly used and first preferred method is ultrasonography [8]. Computerized tomography (CT), magnetic resonance imaging (MRI) or thin needle aspiration can be used for the diagnosis that cannot be defined by ultrasonography [5-7]. In our case, we were preferred ultrasonography as diagnosing method. No additional imaging method was needed.

Lipomas's treatment is total excision [1]. Although



**Figure 2.** The light microscopic appearance of the lesion (hematoxylin-eosin stain, ×200).

total excision is the most commonly used method, liposuction has been used in some studies [6]. In our case, total excision was performed for treatment. Both preoperative and histopathological diagnosis was benign giant lipoma. The patient's follow-ups continue regularly and there isn't any recurrence.

## CONCLUSION

Congenital malignant tumors should be firstly considered in soft tissue masses in childhood. However, we believe that lipomas should be kept in mind. Diagnosis and treatment methods should be selected according the clinic and to the location of the mass. It should not be forgotten that the patients are children.

### *Informed consent*

Written informed consent was obtained from the patient for publication of this case report and any accompanying images.

### *Conflict of interest*

The authors declared that there are no potential conflicts of interest with respect to the research, authorship, and/or publication of this article.

## REFERENCES

- [1] Mazzocchi M, Onesti MG, Pasquini P, La Porta R, Innocenzi D, Scuderi N. Giant fibrolipoma in the leg- a case report. *Anticancer Res* 2006;26:3649-54.
- [2] Hombal PR. Giant gluteal lipoma: a case report and review of literature. *Int J Surg Med* 2015;1:26-9.
- [3] Adebayo OO, Ranti BO, Olateju AO. Giant lipoma of the right gluteal region. *J Med Trop* 2013;15:168-70.
- [4] Allen B, Rader C, Babigian A. Giant lipomas of the upper extremity. *Can J Plast Surg* 2007;15:141-4.
- [5] Zaroo MI, Bashir SA, Mohsin M, Baba PUF, Farooq SSA, Zargar HR. Giant lipoma: a case report. *J IMA* 2011;43:77-9.
- [6] Ilhan H, Tokar B. Liposuction of a pediatric giant superficial lipoma. *J Pediatr Surg* 2002;37:796-8.
- [7] Nigri G, Dente M, Valabrega S, Beccaria G, Aurello P, D'Angelo F, et al. Giant inframuscular lipoma disclosed 14 years after a blunt trauma: a case report. *J Med Case Rep* 2008;2:318.
- [8] Saha M. Intermuscular lipoma in a 4-year-old child presenting like Spigelian hernia. *J Indian Assoc Pediatr Surg* 2015;20:189-90.



This is an open access article distributed under the terms of Creative Commons Attribution-NonCommercial-NoDerivatives 4.0 International License.