

Potential Correlation Between Complicated Root Canal Morphologies of Mandibular Central Incisors and Radix Entomolaris in Mandibular Permanent First Molars in a Turkish Population: A Cone Beam Computed Tomography Analysis

Türk Popülasyonunda Mandibular Santral Kesici Dişlerdeki Komplike Kök Kanal Morfolojisi ile Mandibular Birinci Molar Dişlerdeki Radix Entomolaris Arasındaki Potansiyel Korelasyon: Konik Işınli Bilgisayarlı Tomografi Analizi

© Duygu Göller Bulut¹, © Zeliha Uğur Aydın²

¹Bolu Abant İzzet Baysal University Faculty of Dentistry, Department of Oral and Maxillofacial Radiology, Bolu, Turkey

²Bolu Abant İzzet Baysal University Faculty of Dentistry, Department of Endodontics, Bolu, Turkey



Keywords

Anatomical correlation, CBCT, mandibular molars, radix entomolaris, root canal configuration

Anahtar Kelimeler

Anatomik korelasyon, CBCT, mandibular azı dişler, radix entomolaris, kök kanal konfigürasyonu

Received/Geliş Tarihi : 23.06.2020

Accepted/Kabul Tarihi : 05.02.2021

doi:10.4274/meandros.galenos.2021.80664

Address for Correspondence/Yazışma Adresi:

Duygu Göller Bulut Assoc. Prof.,
Bolu Abant İzzet Baysal University Faculty
of Dentistry, Department of Oral and
Maxillofacial Radiology, Bolu, Turkey
Phone : +90 554 640 66 40
E-mail : duyugoller@hotmail.com
ORCID ID: orcid.org/0000-0003-4260-2520

©Meandros Medical and Dental Journal, Published by
Galenos Publishing House.
This is article distributed under the terms of the
Creative Commons Attribution NonCommercial 4.0
International Licence (CC BY-NC 4.0).

Abstract

Objective: This study investigated the potential correlation between the presence of complicated canal configurations of mandibular central incisors (ManCIs) and the existence of radix entomolaris (RE) in the permanent mandibular first molars (ManFMs) in a Turkish population.

Materials and Methods: The prevalence of complicated ManCI root canal configurations and the prevalence of RE in ManFMs were investigated using cone beam computed tomography images of 534 patients. The correlation between complicated root canal configurations and the presence of RE was evaluated using multivariable logistic regression analysis.

Results: RE was observed in 18.6% (199/1068) of ManFMs, and 22.8% (244/1068) of ManCIs had complicated root canal configurations. There was a positive correlation between complicated ManCI root canal configurations and the presence of RE ($p<0.001$, $r=0.248$).

Conclusion: Within the limitations of the current study, the presence of RE was associated with the existence of complicated ManCI root canal configurations in this Turkish population.

Öz

Amaç: Bu çalışmada Türk popülasyonu üzerinde mandibular santral kesici dişlerde (ManSK) komplike kanal konfigürasyonunun varlığı ile daimi mandibular birinci azı dişlerinde (ManBM) radix entomolaris'in (RE) varlığı arasındaki potansiyel korelasyon araştırıldı.

Gereç ve Yöntemler: Toplamda 534 hastaya ait konik ışınli bilgisayarlı tomografi görüntüsü üzerinde ManSK'lerde komplike kök kanal konfigürasyon prevalansı ve ManBM'lerde RE prevalansı araştırıldı. Karmaşık kök kanal konfigürasyonları ile RE varlığı arasındaki korelasyon çok değişkenli lojistik regresyon analizi kullanılarak değerlendirildi.

Bulgular: ManBM'lerin %18,6'sında (199/1068) RE gözlemlendi ve ManSK'lerin %22,8'inde (244/1068) karmaşık kök kanal konfigürasyonu saptandı. ManSK'lerde

karmaşık kök kanal konfigürasyonu varlığı ile ManBM'larda RE varlığı arasında pozitif bir korelasyon bulundu ($p<0,001$, $r=0,248$).

Sonuç: Mevcut çalışmanın limitasyonları dahilinde, Türk popülasyonunda ManBM'lerde RE varlığı ile ManSK'lerde karmaşık kök kanal konfigürasyonunun varlığı ilişkili bulundu.

Introduction

For successful endodontic treatment, the root canal system must be completely chemo-mechanically cleaned, prepared, and obturated (1). As is well known, these processes, which are essential for endodontic treatment, are affected by root canal anatomy (2). Therefore, knowledge of the main canals, additional canals or other anatomical variations for the elimination of incomplete instrumentation causing apical periodontitis may increase the success of endodontic treatment (1-3).

Mandibular permanent first molars (ManFMs) are frequently treated endodontically and usually have two roots, (distal and mesial) and three canals (two mesial and one distal). A common variation in ManFMs is the presence of a third root, which may be either buccal (radix paramolaris) or lingual [radix entomolaris (RE)] (1,4). This additional root may frequently cause procedural errors during endodontic treatment because it is smaller and separate from the other roots or fused with these roots. Radix paramolaris and RE are also curved. Previous studies showed that this anatomical variation needed to be considered in various dental procedures, such as surgical extractions, periodontal treatment, orthodontic treatment, and root canal treatment (1,4).

Mandibular central incisors (ManCIs) usually have a single root and a single canal. However, an additional canal or root is a common anatomical variation among ManCIs (2). To ensure the success of endodontic treatment and other dental procedures, extensive evaluations of this anatomical variation should be conducted prior to treatment (2,3).

Many studies have investigated the root canal anatomy in different populations using extracted teeth and periapical and panoramic radiographs (5,6). Although periapical and panoramic radiographs are important diagnostic tools for evaluating root canal configurations, they are not completely reliable due to limitations, such as distortion and superposition in the images obtained. Furthermore, studies of root canal configurations of extracted teeth are not always

possible for legal and ethical reasons (6). Recently, cone-beam computed tomography (CBCT) has been widely used in dentistry because it allows clinicians to display an area in three different planes. The combination of CBCT images in the sagittal, coronal, and axial section eliminates the superposition of anatomical structures, giving the clinician a more complete view of the true three-dimensional morphology of root canal systems (7,8).

In the literature it was reported that the existence of RE in ManFMs may be associated with the presence of additional canals in ManCIs (9). Thus far, no study has investigated this association in a Turkish population. The aim of this study was to investigate the association between the existence of RE in ManFMs and the presence of complicated root canal configurations of ManCIs in a Turkish population.

Materials and Methods

Study Group

Due to the retrospective design of the study, the consent was not required from the patients. The study was approved by the Local Ethics Committee of Bolu Abant İzzet Baysal University (decision no: 2018/132 date: 06.09.2018). The study was performed in accordance with the ethical standards laid down in the 1964 Declaration of Helsinki and its later amendments. The CBCT images included in this study were obtained from the Faculty of Dentistry of Bolu Abant İzzet Baysal University. In total, 1,250 CBCT images taken between 2014 and 2018 were obtained. Only CBCT images of good image quality in which the root canal configurations and canal orifices could be easily determined were included in the study. Only teeth without dental anomalies, periapical pathologies, root resorption, previous hemisection or root amputation treatment, large metallic restorations, coronal or post-core restorations, and root canal treatment were included. In all the included ManFMs and ManCIs, complete root formations were present bilaterally.

The final group included images obtained from 534 patients [319 females (59.7%) and 215 males (40.3%)] and 1,068 ManFMs and 1,068 ManCIs.

Imaging Procedures

The CBCT scans were obtained using an I-Cat imaging system (Imaging Sciences International, Hatfield, PA, USA) at 120 kVp and 15 mA, with a voxel size of 0.2 mm and an exposure time of 8.9 sec.

The presence or absence of RE and the existence of complicated ManCI canal configurations, including the type of configuration, were investigated using i-CAT vision Q 1.9 imaging software (Imaging Sciences International LLC, Hatfield, PA, USA). Tomography slices of 0.2 mm in the coronal, axial, and sagittal views were produced. To determine the number of canals and roots and the canal configurations in axial tomography slices, we investigated all sections throughout from the bottom of the pulp chamber to the root apex.

Morphological Analysis and Classification

Two observers evaluated all the CBCT images: an oral and maxillofacial radiologist with 6 years of experience and an endodontist with 6 years of experience. Observer calibration was achieved by having the two observers evaluate 20% of the CBCT scans at the beginning of the study. Intra-observer reliability was assessed by calculating the correlation coefficients (for observer one and observer two; 0.857 and 0.861, respectively). The observers were permitted to use image enhancement filters to change the intensity, contrast, or brightness of the images. A consensus was established in cases where there was inconsistency between the observers in the determination of morphological differences. Interobserver reliability was assessed when all the measurements were performed. The correlation coefficient was 0.908.

The presence of RE in the ManFMs was evaluated according to previous studies (9-11). The RE status of the patients was classified as follows (Figure 1 A-D):

No RE: RE was not found in either the left or right side;

Unilateral RE: RE was found in just one ManFM on either the left or right side, and no RE was detected in the other ManFM on the other side;

Bilateral RE: RE was found in both the right and left sides of ManFMs.

To determine the root canal configurations of ManCIs, a series of axial images and cross-sectioned images were examined from the cemento-

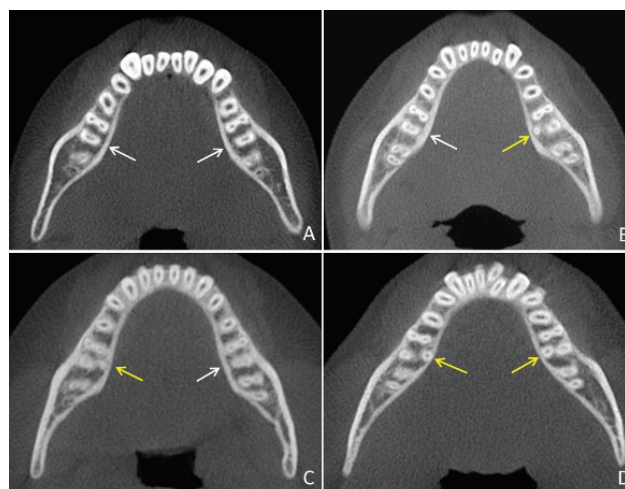


Figure 1. Axial CBCT images. (A) No RE, (B) unilateral RE on the left side, and (C) unilateral RE on the right side. (D) Bilateral RE (yellow arrows denote RE; white arrows denote no RE) RE: Radix entomolaris, CBCT: Cone beam computed tomography

enamel junction to the root apex. The ManCI canal configurations were then classified in accordance with a system used in previous studies (9,12), as follows:

A single canal: the presence of one root and one canal.

A complicated canal: the occurrence of more than one root and canal.

The symmetric distribution arrangement of complicated ManCI canals was categorized as follows: bilateral single, unilateral complicated or bilateral complicated (Figure 2 A-C).

The root canal configuration of the teeth was classified according to Vertucci's classification (13).

Statistical Analysis

In each analysis, frequencies and percentages were calculated at tooth and patient levels. The chi-square test was used for examining differences in categorical variables, such as side (left/right) and sex (male/female), root canal configuration (single/complicated), and RE group (no RE, unilateral RE, or bilateral RE) (9). To assess the effect on the canal configurations of ManCIs, a multivariate logistic regression analysis was used and was simultaneously adjusted for other variables (side, age, and sex). The statistical analysis was performed using SPSS for Windows (Version 22.0; SPSS, Inc., Chicago, IL, USA). The statistically significant level was set at $p < 0.05$.

Results

As shown by the results, 18.6% (199/1,068) of ManFMs had RE, and 22.8% (244/1,068) of ManCIs had a complicated root canal configuration. Only Vertucci's type I and type III canal configurations were

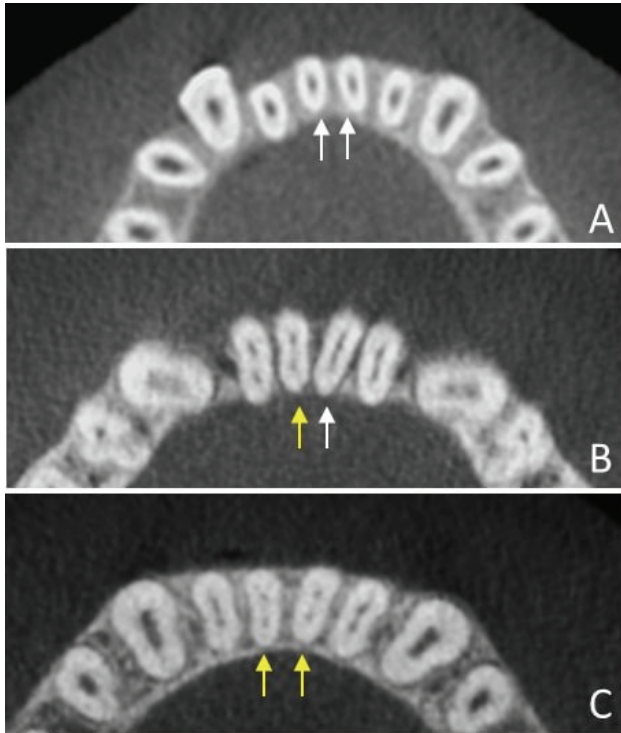


Figure 2. The root canal configuration of a ManCI in an axial CBCT image. (A) Bilateral single root canal configuration, (B) unilateral complicated root canal configuration, and (C) bilateral complicated root canal configuration (yellow arrows show RE; white arrows show no RE)
RE: Radix entomolaris, CBCT: Cone beam computed tomography, ManCIs: Mandibular central incisors

seen in ManCIs (Figure 3). In 74.2% of ManCIs, the canal configuration was type I, and it was type III in 25.8% of ManCIs.

Based on the CBCT images, 11.7% (63/534) of the patients had bilateral RE, and 12.1% (65/534) had unilateral RE (Figure 4A). Among the patients, 15.9% (86/534) had ManCIs with a bilateral complicated canal configuration, 73% (394/534) had ManCIs with a bilateral single canal, and 10% (54/534) had ManCIs with a unilateral complex canal configuration (Figure 4B).

Table 1 shows the prevalence of RE in ManFMs and complicated ManCI canal configurations according to side and sex. The prevalence of RE was higher in males (24.7%) than in females (13.8%) ($p=0.002$). The ratios of complicated ManCI canal configurations and RE in ManFMs were similar on the right and left sides ($p=0.215$ and $p=0.753$, respectively).

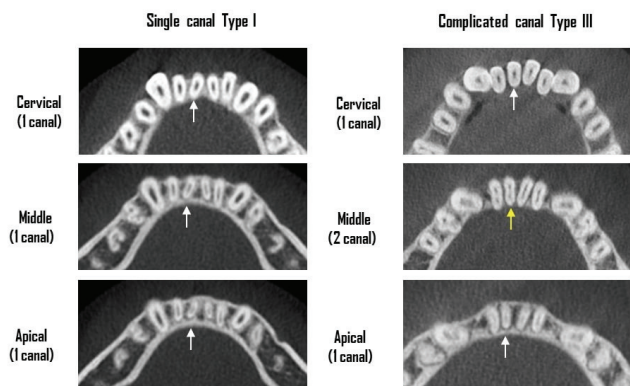


Figure 3. The root canal configuration of ManCIs according to Vertucci's classification type I and type III (white arrow: a single canal; yellow arrow: two canals)
ManCIs: Mandibular central incisors

Table 1. Distribution of ManCIs with complicated root canal configurations and ManFMs with RE by gender and side

	ManCIs, n (%)		p-value	ManFMs, n (%)		p-value
	Single	Complicated		Without RE	With RE	
Total	824 (77.2)	244 (22.8)		869 (81.4)	199 (18.6)	
Gender						
Female	235 (73.7)	84 (26.4)	0.256	275 (86.2)	44 (13.8)	0.002*
Male	161 (74.9)	54 (25.1)		162 (75.3)	53 (24.7)	
Side						
Right	403 (75.5)	131 (24.5)	0.215	437 (81.8)	97 (18.2)	0.753
Left	421 (78.8)	113 (21.2)		402 (80.9)	102 (19.1)	

Single indicates the presence of one canal in ManCIs. Complicated indicates the occurrence of more than one canal in any CBCT section. *Statistical significance level was set at $p<0.05$, RE: Radix entomolaris, ManCIs: Mandibular central incisors, ManFMs: Mandibular first molars

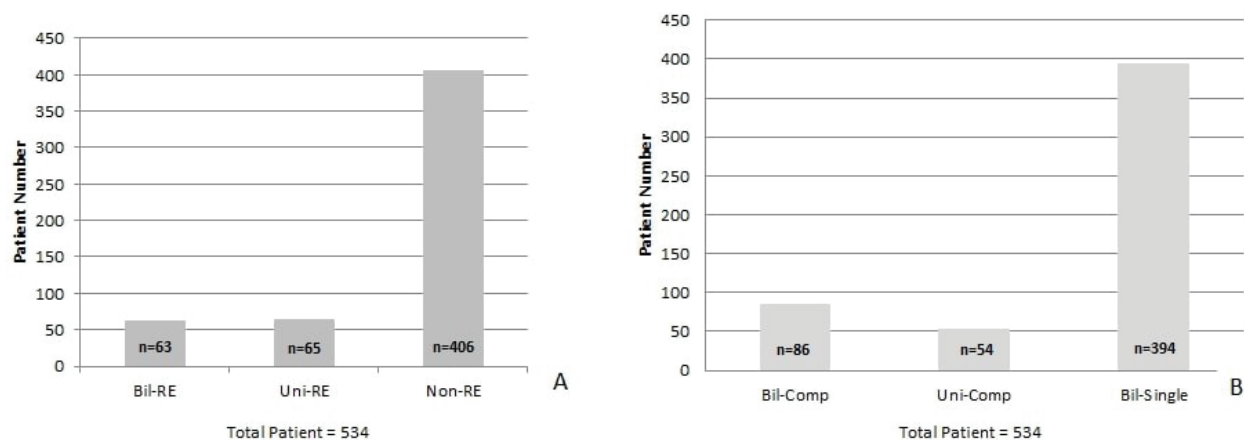


Figure 4. (A) Distribution patterns of unilateral RE and bilateral RE. (B) Distribution patterns of bilateral and unilateral complicated root canals
RE: Radix entomolaris

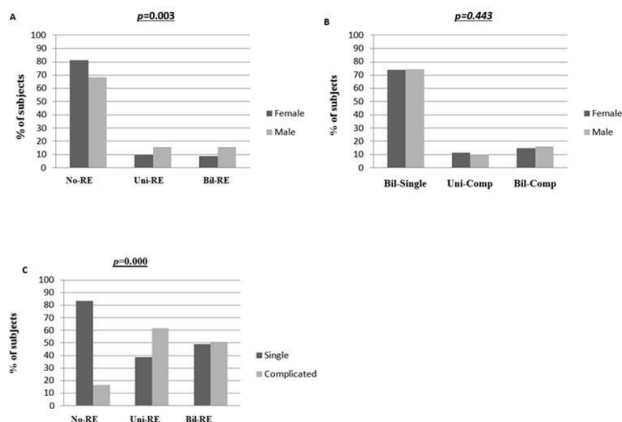


Figure 5. (A) Distribution patterns of ManFMs without/with RE (no RE, unilateral RE, and bilateral RE) based on sex. (B) Distribution patterns of ManCIs with bilateral single root canal configurations and complicated root canal configurations based on sex. (C) Distribution patterns of no RE, unilateral RE, and bilateral RE based on single and complicated root canal configurations
RE: Radix entomolaris, ManCIs: Mandibular central incisors, ManFMs: Mandibular first molars

There was a significant sex-related difference in the prevalence of RE in ManFMs ($p=0.003$) (Figure 5A), whereas there was no significant sex- or side-related difference in the prevalence of complicated ManCI root canal configurations ($p=0.443$) (Figure 5B). There was a positive correlation between complicated ManCI root canal configurations and ManFMs with RE ($p<0.001$, $r=0.248$) (Figure 5C).

The multivariate analysis was adjusted for categorical variables, such as sex and sides. The adjusted odds ratios for the frequency of complicated ManCI root canal configurations in the bilateral RE group and unilateral RE group were 0.18 (95% confidence interval, 0.103-0.322; $p<0.001$) and 1.54 (95% confidence interval, 0.764-3.129; $p=0.226$), respectively (Table 2).

Discussion

Anatomical variations in root canal anatomy can cause difficulties in diagnosis and treatment. To ensure the success of dental treatments, the practitioner must have knowledge of the root canal anatomy. Although many studies have investigated the root canal anatomy of different tooth groups in different populations, only a few studies have investigated the relationship between variations in root canal anatomy (9,14).

In previous studies, the prevalence of RE in ManFMs differed, depending on the population (15,16). The prevalence of RE in ManFMs was reported to be higher in populations of Mongoloid origin (Chinese, Japanese, Korean, and Taiwanese) (5.8-43.6%) as compared with that in white populations (0.68-4.2%) (4). In this study, the prevalence of RE in ManFMs in a Turkish population was 18.6%. Although the etiology of RE is not known, previous research reported that external factors in the odontogenesis phase, penetrance of an atavistic gene, or a polygenetic system may influence the etiology (17). Studies also

Table 2. The Relationship between variables and the Frequency of complicated root canal configurations in ManCIs: Adjusted ORs and 95% CIs from multivariable logistic regression analysis

	Adjusted ORs	ManCIs		
		95% CI		p-value
		Lower	Upper	
Gender				
Male	Referent			
Female	1.398	0.900	2.172	0.398
Side				
Left	Referent			
Right	1.211	0.910	1.613	0.190
RE group				
No-RE	Referent			
Bil-RE	0.18	0.103	0.322	<0.001*
Uni-RE	1.54	0.764	3.129	0.226

No-RE, no mandibular first molars with radix entomolaris bilaterally; Bil-DLR, radix entomolaris in both right and left mandibular first molars bilaterally; Uni-RE, one mandibular first molar with a radix entomolaris either at the left or right side and the other permanent mandibular first molar without a radix entomolaris. Analysis by multivariable logistic regression; the statistical significance level was set at $p < 0.05$ *. OR: Odds ratio, CI: Confidence interval, ManCIs: Mandibular central incisors

suggested that the presence of RE depended to a high degree on racial genetic factors (17,18). Therefore, we think that genetic differences between populations most likely explain the discord in the findings of the present study as compared with those in the literature.

A previous research reported root canal anatomy variations of ManCIs (19), with a number of studies reporting that ManCIs most commonly have type I or type III Vertucci root canal configurations (12,20). In line with these results, in this study, ManCIs with type I (74.2%) and type III (25.8%) root canal configurations were the most common.

Wu et al. (9) reported that there was a correlation between the presence of RE in ManFMs and complicated ManCI root canal configurations in a Taiwanese population. Similarly, we found a correlation between the presence of RE in ManFMs and complicated ManCI root canal configurations in this Turkish population. No previous studies have investigated this relationship in a Turkish population. Based on the findings of the present study, if RE should be present, and there should be a suspicion that complicated canal configuration in ManCIs.

Therefore, the results of this study can benefit clinical management.

A number of studies on symmetry in dental structures found that many anatomical variations were symmetrical and irrespective of the region (17,19,21). In patients with RE, Wu et al. (9) reported a 54.6% prevalence of the bilateral type in ManFMs. In this study, among those with RE, the prevalence of the bilateral type was 49.2%, and the prevalence of RE did not show a significant difference between the sides. In contrast, Schäfer et al. (15) detected no cases of bilateral RE in ManFMs in a German population. Similarly, other studies reported that anatomical variations differed significantly, depending on the side (16,18). According to some studies, the prevalence of RE was greater on the right side (16,22) whereas others found that it was greater on the left side (19). As stated previously in the literature (17), genetic variations between different populations most likely explain this difference.

Roots or canals in the same buccolingual plane in both ManFMs and ManCIs may cause superposition on two-dimensional radiographs. As a result, additional roots or canals may not be detected. To overcome this limitation and detect additional roots and canals, radiographs may be taken at different angles (23). However, the latter increases radiation exposure and is time consuming. In the identification of additional canals and roots, CBCT has been shown to provide more accurate results, without causing superposition and distortion as compared with two-dimensional radiographs (10). The voxel size is one of the most important factors that affects the image resolution in CBCT, with the smaller the voxel size, the better the quality and detail of the resulting image. However, a reduction in the voxel size in CBCT devices increases the exposure to radiation. In this study, CBCT images with a voxel size of 0.2 mm were obtained. This size is considered the maximum ideal size for evaluating root canal anatomy (23,24).

In a previous study, the presence of RE in ManFMs was reported to be related to a C-shaped canal configuration and radicular grooves in mandibular first premolar teeth (14). Zhang et al. (25) evaluated the morphological characteristics of RE in a Chinese population, and De Moor (26) classified RE according to the RE type. The relationship between the presence of RE and root canal configurations of teeth

other than ManFMs, in addition to the morphological characteristics of RE, should be determined in a Turkish population in future studies.

Conclusion

The results revealed a correlation between the presence of RE in ManFMs and the existence of complicated ManCI root canal configurations in this Turkish population. RE should be considered to be present in the presence of a complicated root canal configuration.

Ethics

Ethics Committee Approval: The study was approved by the Local Ethics Committee of Bolu Abant İzzet Baysal University (decision no: 2018/132 date: 06.09.2018).

Informed Consent: Retrospective study.

Peer-review: Externally and internally peer-reviewed.

Authorship Contributions:

Surgical and Medical Practices: Z.U.A., Concept: D.G.B., Z.U.A., Design: D.G.B., Z.U.A., Data Collection or Processing: D.G.B., Analysis or Interpretation: Z.U.A., Literature Search: D.G.B., Z.U.A., Writing: D.G.B., Z.U.A.

Conflict of Interest: No conflict of interest was declared by the authors.

Financial Disclosure: The authors declared that this study received no financial support.

References

- Chen G, Yao H, Tong C. Investigation of the root canal configuration of mandibular first molars in a Taiwan Chinese population. *Int Endod J* 2009; 42: 1044-9.
- Leoni GB, Versiani MA, Pécora JD, Damião de Sousa-Neto M. Micro-computed tomographic analysis of the root canal morphology of mandibular incisors. *J Endod* 2014; 40: 710-6.
- Liu J, Luo J, Dou L, Yang D. CBCT study of root and canal morphology of permanent mandibular incisors in a Chinese population. *Acta Odontol Scand* 2014; 72: 26-30.
- Song JS, Choi HJ, Jung IY, Jung HS, Kim SO. The prevalence and morphologic classification of distolingual roots in the mandibular molars in a Korean population. *J Endod* 2010; 36: 653-7.
- Choi SJ, Lee JW, Song JH. Dental anomaly patterns associated with tooth agenesis. *Acta Odontol Scand* 2017; 75: 161-5.
- Boschetti E, Silva-Sousa YTC, Mazzi-Chaves JF, Leoni GB, Versiani MA, Pécora JD, et al. Micro-CT Evaluation of Root and Canal Morphology of Mandibular First Premolars with Radicular Grooves. *Braz Dent J* 2017; 28: 597-603.
- Fernandes NA, Herbst D, Postma TC, Bunn BK. The prevalence of second canals in the mesiobuccal root of maxillary molars: A cone beam computed tomography study. *Aust Endod J* 2019; 45: 46-50.
- Alfawaz H, Alqedairi A, Alkhayyal AK, Almobarak AA, Alhusain MF, Martins JNR. Prevalence of C-shaped canal system in mandibular first and second molars in a Saudi population assessed via cone beam computed tomography: a retrospective study. *Clin Oral Investig* 2019; 23: 107-12.
- Wu YC, Cheng WC, Weng PW, Chung MP, Su CC, Chiang HS, et al. The Presence of Distolingual Root in Mandibular First Molars Is Correlated with Complicated Root Canal Morphology of Mandibular Central Incisors: A Cone-beam Computed Tomographic Study in a Taiwanese Population. *J Endod* 2018; 44: 711-6.e1.
- Huang RY, Cheng WC, Chen CJ, Lin CD, Lai TM, Shen EC, et al. Three-dimensional analysis of the root morphology of mandibular first molars with distolingual roots. *Int Endod J* 2010; 43: 478-84.
- Wu YC, Su CC, Tsai YC, Cheng WC, Chung MP, Chiang HS, et al. Complicated Root Canal Configuration of Mandibular First Premolars Is Correlated with the Presence of the Distolingual Root in Mandibular First Molars: A Cone-beam Computed Tomographic Study in Taiwanese Individuals. *J Endod* 2017; 43: 1064-71.
- Ahmed HM, Hashem AA. Accessory roots and root canals in human anterior teeth: a review and clinical considerations. *Int Endod J* 2016; 49: 724-36.
- Vertucci FJ. Root canal anatomy of the human permanent teeth. *Oral Surg Oral Med Oral Pathol* 1984; 58: 589-99.
- Wu YC, Cathy Tsai YW, Cheng WC, Weng PW, Su CC, Chiang HS, et al. Relationship of the Incidence of C-shaped Root Canal Configurations of Mandibular First Premolars with Distolingual Roots in Mandibular First Molars in a Taiwanese Population: A Cone-beam Computed Tomographic Study. *J Endod* 2018; 44: 1492-9.e1.
- Schäfer E, Breuer D, Janzen S. The prevalence of three-rooted mandibular permanent first molars in a German population. *J Endod* 2009; 35: 202-5.
- Tu MG, Tsai CC, Jou MJ, Chen WL, Chang YF, Chen SY, et al. Prevalence of three-rooted mandibular first molars among Taiwanese individuals. *J Endod* 2007; 33: 1163-6.
- Chandra SS, Chandra S, Shankar P, Indira R. Prevalence of radix entomolaris in mandibular permanent first molars: a study in a South Indian population. *Oral Surg Oral Med Oral Pathol Oral Radiol Endod* 2011; 112: e77-82.
- Curzon ME. Three-rooted mandibular permanent molars in English Caucasians. *J Dent Res* 1973; 52: 181.
- Kayaoglu G, Peker I, Gumusok M, Sarikir C, Kayadugun A, Ucok O. Root and canal symmetry in the mandibular anterior teeth of patients attending a dental clinic: CBCT study. *Braz Oral Res* 2015; 29: S1806-83242015000100283.
- Verma GR, Bhadage C, Bhoosreddy AR, Vedpathak PR, Mehrotra GP, Nerkar AC, et al. Cone Beam Computed Tomography Study

- of Root Canal Morphology of Permanent Mandibular Incisors in Indian Subpopulation. *Pol J Radiol* 2017; 82: 371-5.
21. Johnsen GF, Dara S, Asjad S, Sunde PT, Haugen HJ. Anatomic Comparison of Contralateral Premolars. *J Endod* 2017; 43: 956-63.
 22. Steelman R. Incidence of an accessory distal root on mandibular first permanent molars in Hispanic children. *ASDC J Dent Child* 1986; 53: 122-3.
 23. Yew SC, Chan K. A retrospective study of endodontically treated mandibular first molars in a Chinese population. *J Endod* 1993; 19: 471-3.
 24. Ji Y, Wen S, Liu S, Zhu M, Yao M, Wang T, et al. Could cone-beam computed tomography demonstrate the lateral accessory canals? *BMC Oral Health* 2017; 17: 142.
 25. Zhang X, Xu N, Wang H, Yu Q. A Cone-beam Computed Tomographic Study of Apical Surgery-related Morphological Characteristics of the Distolingual Root in 3-rooted Mandibular First Molars in a Chinese Population. *J Endod* 2017; 43: 2020-4.
 26. De Moor RJ, Deroose CA, Calbertson FL. The radix entomolaris in mandibular first molars: an endodontic challenge. *Int Endod J* 2004; 37: 789-99.