

## Bilateral and multicentric Warthin's tumor primarily presented with cervical lymph node involvement

Muammer Melih Şahin<sup>1</sup>, Alper Ceylan<sup>1</sup>, Mehmet Düzlü<sup>1</sup>, Erolcan Sayar<sup>2</sup>

<sup>1</sup>Department of Otorhinolaryngology - Head and Neck Surgery, Faculty of Medicine, Gazi University, Ankara, Turkey

<sup>2</sup>Department of Pathology, Faculty of Medicine, Gazi University, Ankara, Turkey

### Abstract

Papillary cystadenoma lymphomatosa (Warthin's tumor) is the second most common benign neoplasm of the parotid gland. Although the tumor usually presents as a slowly growing mass in the tail of the parotid gland, extraparotid involvements such as the cervical lymph nodes may be observed rarely. In this article, we aimed to report a Warthin's tumor case with atypical presentation. A 68-year-old male patient with the history of smoking was admitted to our clinic with the complaint of right-sided neck lump. After physical examination and imaging, excisional biopsy was performed with an initial diagnosis of cervical lymphadenopathy. Pathology result was reported as Warthin's tumor. Five months later, multicentric Warthin's tumor in the contralateral parotid gland was diagnosed and operated. With this case report, we want to emphasize that Warthin's tumors may rarely present as a neck lump outside the parotid gland, and we want to review relevant literature data.

**Keywords:** Warthin's tumor, cervical lymph node, papillary cystadenoma lymphomatosa, extraparotid.

### Özet: Primer olarak servikal lenf nodu tutulumu gösteren bilateral multisentrik Warthin tümörü

Papiller kistadenoma lenfomatozum (Warthin tümörü), parotis bezinin ikinci en sık görülen benign neoplazisidir. Tümör parotis bezi kuyruğunda, yavaş büyüyen kitle olarak kendini gösterir. Sıklıkla parotis bezinde gözlense de, servikal lenf nodları gibi ekstraparotidal tutulumlar da gözlenebilir. Biz de bu çalışmamızda atipik yerleşimli bir Warthin tümörü olgusunu sunmayı planladık. Sigara içme öyküsü olan 68 yaşında erkek hasta bir yıldır olan boyunda şişlik şikayeti ile kliniğimize başvurdu. Fizik muayene ve görüntüleme sonrası servikal lenfadenopati ön tanısı ile eksizyonel biyopsi yapıldı. Patoloji sonucu Warthin tümörü olarak raporlandı. Beş ay sonra karşı parotis bezinde multisentrik Warthin tümörü tanısı kondu ve opere edildi. Bu olgu sunumu ile Warthin tümörlerinin nadiren de olsa ekstraparotidal yerleşimli görülebileceğini vurgulamayı ve ilgili literatür verilerini derlemeyi amaçladık.

**Anahtar sözcükler:** Warthin tümörü, servikal lenf nodu, parotis dışı Warthin tümörü, papiller kistadenoma lenfomatozum.

Warthin's tumor (WT) is a benign salivary gland tumor frequently arising from the parotid gland. It is the most common salivary gland tumor after pleomorphic adenoma.<sup>[1]</sup> WT may be seen bilateral (5–14%) and multicentric (12–20%).<sup>[2]</sup> Although WT is often originated from parotid gland, it may be encountered in extraparotid tissues such as nasopharynx, oral cavity, larynx, and cervical lymph nodes.<sup>[3,5]</sup> Histopathologically, there are encapsulated lesions containing cystic and solid components. The tumor occurs more commonly in male patients (10:1) and develops more often in the sixth and seventh decades.<sup>[3]</sup> Patients often complain slow but progressively growing masses around the

jawbone. In this article, we aimed to present a case of WT with an atypical presentation and location and to compare it with literature data.

### Case Report

A 68-year-old male patient admitted to our clinic with the complaint of swelling on the right side of his neck approximately for one year. The medical history revealed that the neck mass has enlarged in the last four months, despite the empiric antibiotic treatment. In addition, the patient was in the remission period of bladder tumor without any problems

**Correspondence:** Muammer Melih Şahin, MD. Department of Otorhinolaryngology - Head and Neck Surgery, Faculty of Medicine, Gazi University, Ankara, Turkey.  
e-mail: mlhseda@gmail.com

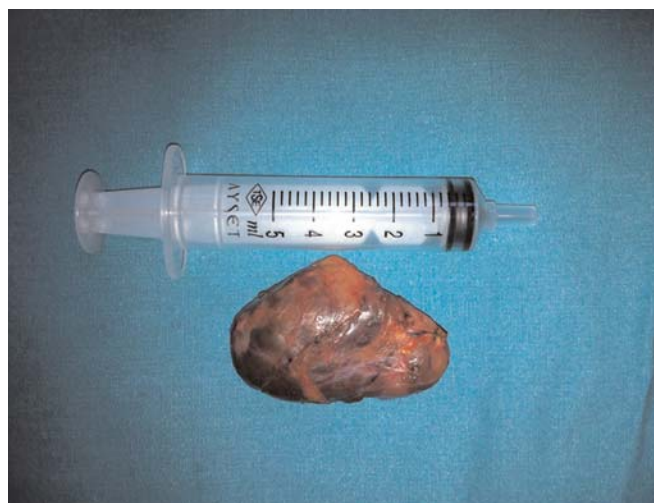**Received:** February 9, 2018; **Accepted:** April 3, 2018

Online available at:  
www.entupdates.org  
doi:10.2399/jmu.2018001010  
QR code:



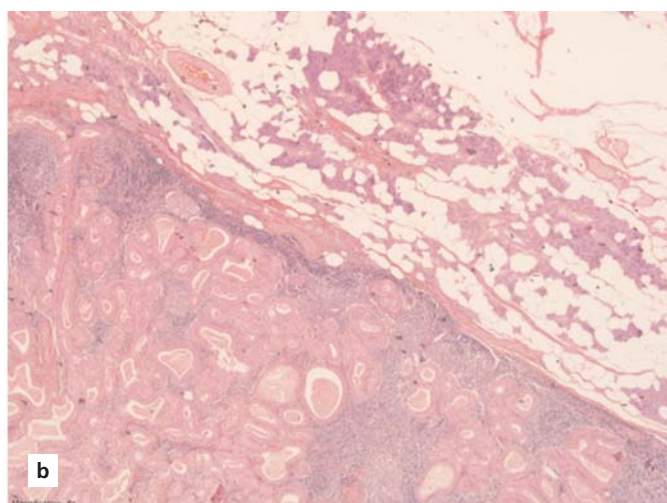
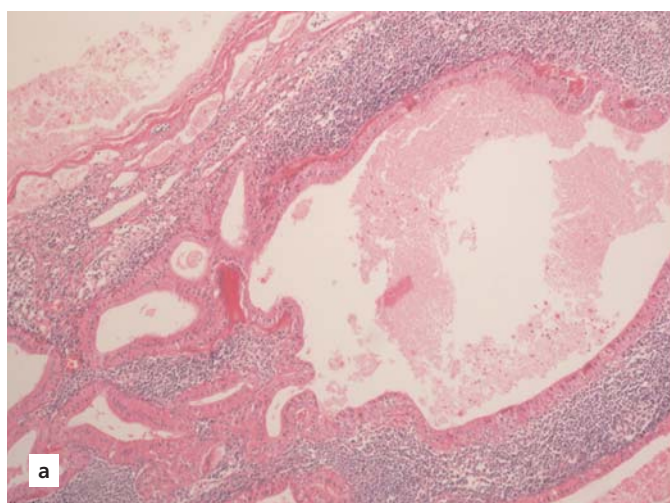
in the follow-up. The low-grade bladder epithelial tumor was treated surgically without adjuvant treatment for about 3 years ago. The patient had one packet/day smoking history for 40 years. On physical examination, approximately 4×3 cm hard, mobile, painless mass was observed on the right side of the neck. Comprehensive otorhinolaryngologic examination was normal except this right sided neck mass. The USG examination revealed heterogeneous-hypoechoic multifocal lymph nodes-mass appearance with locally cystic areas with the largest size of 4.1×4.7 cm in the right cervical zone 3. Due to the patient's age and previous medical history, excisional biopsy was planned considering bladder tumor metastasis or lymphoma. A 4 cm horizontal incision was made approximately 2 cm below the right mandibular angle. The tumor was exposed after dissection in sub-platysmal plane and the mass was entirely excised from the surrounding tissues. Marginal mandibular nerve not recognized. The sub-mandibular gland was observed in natural location and no relation was noticed between the mass and the parotid gland tail. The mass was observed to be about 6×4 cm in size, with hard-nosed, necrotic, lobule, and somewhat cystic areas (**Fig. 1**). There were no complications during the operation. The cervical lymph node pathology was reported as WT (**Fig. 2a**).

In the post-operative follow-up, a secondary neck mass formation was noticed on the contralateral (left) parotid gland five months later. USG imaging revealed a deep lobe mass with a size of 25×10 mm. The subsequent fine needle



**Fig. 1.** Macroscopic view of the mass.

aspiration was reported as non-diagnostic. Parotidectomy was planned with WT diagnosis. In the operation, both the superficial and the deep lobes of the parotid gland were observed to be involved, meaning that multicentricity of the tumor is present. Therefore, total parotidectomy was performed. Pathology result was compatible with WT (**Fig. 2b**). There were no complications. No residual or recurrence was encountered in control examinations in the post-operative second year control.



**Fig. 2.** (a) Lymph node. Oncocytic columnar cells lining the surface epithelium in the dense lymphoid stroma and epithelial elements composed of the basal cell layer (H&E ×100). (b) Parotid gland. In the dense lymphoid stroma, oncocytic columnar cells lining the surface epithelium, epithelial elements composed of the basal cell layer and surrounding normal salivary gland tissue (H&E ×40). [Color figure can be viewed in the online issue, which is available at [www.entupdates.org](http://www.entupdates.org)]

## Discussion

Warthin's tumor is the second most common benign neoplasm in salivary gland tumors and it is accounted for about 6–10% of all salivary gland tumors. It was first described by Hillebrand in 1985 as “adenolenoma” and was described by Warthin in 1929 as “papillary cystadenoma lymphomatosis”.<sup>[4]</sup> It often occurs in the parotid gland, especially in the tail part of the gland. However, it is rarely seen outside the parotid gland in various locations like submandibular salivary glands, cervical lymph nodes, larynx, nasal and oral cavity, minor salivary glands, upper lip, and nasopharynx.<sup>[5–7]</sup>

In patients with complaints of neck mass, inflammatory lesions are considered primarily, and antibiotic treatment is frequently administered. Especially in patients over forty years of age, neck masses should be considered primarily as a neoplastic formation unless proved to be non-neoplastic.<sup>[8]</sup> WT is often seen in the sixth decade and is rarely seen before fourth decade. Several theories have been proposed in the histopathogenesis of extraparotid WT. Most commonly accepted theories are, delayed encapsulation of the parotid gland in the embryological process and development of the salivary ductal inclusions located in the lymph nodes. Macroscopically, it contains cystic and necrotic areas filled with brown gelatinous fluid, and histologically it is surrounded by an oncocytic epithelium of cystic and papillary structures around the dense lymphoid stroma.<sup>[9]</sup> It is known to be closely related to smoking. The risk of WT development was shown to be eight times higher in smokers than in non-smokers.<sup>[10]</sup> Our case had one packet/day smoking story for 40 years. WT's recurrence (2%) and malignant transformations (1%) are very rare. For this reason, the World Health Organization (WHO) should consider it as “tumor-like lesions” and discuss whether it is a true neoplasm.<sup>[11]</sup>

After reviewing medical history and detailed physical examination, USG is the first imaging modality for diagnosis. CT and MRI studies can be performed in the presence of recurrences, multicentric formation, contact with neighboring structures and presence of concomitant neoplastic lesions.<sup>[12]</sup> In parotid tumors, some studies suggest that fine-needle aspiration (FNA) shows high specificity and sensitivity, but some authors argue that the main goal of FNA is the distinction between malignant benign neoplasms and the definitive result can only be revealed by excisional biopsy.<sup>[13]</sup> In this case, we planned excisional biopsy considering malignant lesion.

WT is often caused by the superficial lobe of the parotid gland (90%), and therefore superficial parotidectomy is considered necessary and adequate. However, total parotidectomy is recommended if the mass is originated from deep lobe or extends toward deep lobe. The most important complication after surgery is facial paralysis. Temporary paralysis is seen between 16% and 47%, and permanent paralysis between 0% and 9%.<sup>[14]</sup>

Although WT frequently originates from the parotid gland, it may also be located on the cervical lymph nodes with bilateral and multicentric involvement as is our case. Cervical lymph node involvement of WT may be the first apparent tumor focus for the patients. Therefore, these patients should be closely followed both parotid glands and other extraparotid fields for possible disease in post-operative routine examinations. In the surgery of benign salivary gland tumors with heterotypic placement, local excision and close follow-up are recommended.

In conclusion, WT often originates from parotid gland; however, it may also be seen in extraparotid tissues. Extraparotid presentation of WT, such as cervical lymph node involvement, may also be a sign of a primary tumor located in the ipsilateral or contralateral parotid gland.

**Conflict of Interest:** No conflicts declared.

## References

1. Tian Z, Li L, Wang L, Hu Y, Li J. Salivary gland neoplasms in oral and maxillofacial regions: a 23-year retrospective study of 6982 cases in an eastern Chinese population. *Int J Oral Maxillofac Surg* 2010;39:235–42.
2. Maiorano L, Lo ML, Favia G, Piattelli A. Warthin's tumour: a study of 78 cases with emphasis on bilaterality, multifocality and association with other malignancies. *Oral Oncol* 2002;38:35–40.
3. Düzlü M, Gümüş S, Tutar H, Karamert R, Cevizci R, Oltulu P. A case of Warthin tumor with atypical location. *Gazi Medical Journal* 2014;25:114–5.
4. Warthin A. Papillary cystadenoma lymphomatousum. *J Cancer Res* 1929;13:116–25.
5. Kawakami M, Ito K, Tanaka H, Hyo S. Warthin's tumor of the nasopharynx: a case report. *Auris Nasus Larynx* 2004;31:293–8.
6. Pereira J, Machado S, Lima F, Lima M, Miguel M. Warthin tumor in an unusual site: a case report. *Minerva Stomatol* 2013;62:189–92.
7. Bernier JL, Bhaskar SN. Lymphoepithelial lesions of salivary glands; histogenesis and classification based on 186 cases. *Cancer* 1958;11:1156–79.
8. Lee SG, Helmus C. Cervical lymph node biopsy. *Mich Med* 1970;69:581–3.
9. Faur A, Lazar E, Cornianu M, Dema A, Vidita CG, Galuşcan A. Warthin tumor: a curious entity - case reports and review of literature. *Rom J Morphol Embryol* 2009;50:269–73.

10. Wang MC, Tsai TL, Chen PC, Liu CY, Chu PY. Extraparotid Warthin's tumor presented as a neck mass. *J Chin Med Assoc* 2003;66:752-4.
11. Seifert G. Tumour-like lesions of the salivary glands. The new WHO classification. *Pathol Res Pract* 1992;188:836-46.
12. Castro GA, Tiago RSL, Silva DA, Machado MC, Fukuda Y, Fava AS. Warthin's tumor of the parotid gland. [Article in Portuguese] *Int Arch Otorhinolaryngol* 2004;8(2):3-5.
13. Brennan PA, Davies B, Poller D, et al. Fine needle aspiration cytology (FNAC) of salivary gland tumours: repeat aspiration provides further information in cases with an unclear initial cytological diagnosis. *Br J Oral Maxillofac Surg* 2010;48:26-9.
14. Chedid HM, Rapoport A, Aikawa KF, Menezes ADS, Curioni OA. Warthin's tumor of the parotid gland: study of 70 cases. *Rev Col Bras Cir* 2011;38:90-4.

This is an open access article distributed under the terms of the Creative Commons Attribution-NonCommercial-NoDerivs 3.0 Unported (CC BY-NC-ND3.0) Licence (<http://creativecommons.org/licenses/by-nc-nd/3.0/>) which permits unrestricted noncommercial use, distribution, and reproduction in any medium, provided the original work is properly cited.

*Please cite this article as:* Şahin MM, Ceylan A, Düzlü M, Sayar E. Bilateral and multicentric Warthin's tumor primarily presented with cervical lymph node involvement. *ENT Updates* 2018;8(1):62-65.