



The Effect of Octyl-Cyanoacrylate in Wound Healing at Closing the Experimentally Formed Skin Incision in Rabbits

Abdullah KARASU¹ Bahtiyar BAKIR²

¹ Yuzuncu Yil University, Faculty of Veterinary Medicine, Department of Surgery, Van, Turkey

² Gazi University, Health Services Vocational School, Ankara, Turkey

Received: 09.08.2015

Accepted: 05.10.2015

SUMMARY

In this study, it was aimed to evaluate the effect of tissue adhesive octyl-cyanoacrylate (OCA) at wound healing in closing the incisional skin wounds in rabbits. 24 healthy rabbits were used as study material. Two parallel full-thickness skin incisions with 6 cm length were performed under aseptic conditions on the left and right sides of each experimental rabbit dorsum and immediately subcutaneous connective tissue of all wounds were sutured by simple continuous suture pattern with 3/0 chromic gut. The right side skin incision (control group) sutured by seven simple sutures with 3/0 silk. The skin incisions at the left (OCA group) were closed with OCA tissue adhesive after approximate the wound edges with forceps and fingers. Six rabbits were anesthetized on days 3, 7, 14 and 21 after surgery. Skin wounds were removed both from the OCA and suture applied wounds which was 3 cm width and 6 cm length. They were used for histopathologic evaluation, tensile strength and hydroxyproline measurement. It was macroscopically observed that the inflammatory reaction and scab formation in the OCA group was less and the scar formation was similar and better in some regions compared to the control group. It was also microscopically determined in the OCA group that the inflammatory reaction on postoperative days of 3 and 7 was less formed and the collagen formation was less on postoperative days of 14 and 21 compared to the control group. The wound tensile strength didn't statistically different between the groups. It was determined that the hydroxyproline levels in OCA group were higher on postoperative days of 3 and 7 and there was no difference on postoperative days of 14 and 21. In conclusion, OCA tissue adhesive could be used in closing the incisional skin wounds in the small animal together with the subcutaneous suture.

Key Words: Octyl-cyanoacrylate, Wound healing, Rabbit

ÖZET

Tavşanlarda Deneysel Olarak Oluşturulan Deri Ensizyonlarının Kapatılmasında Oktil-Siyanoakrilatın Yara İyileşmesi Üzerine Etkisi

Bu çalışmada tavşanlarda oluşturulan ensizyonel deri yaralarının kapatılmasında oktil-siyanoakrilat (OCA) doku yapıştırıcısının yara iyileşmesine etkilerinin araştırılması amaçlandı. Çalışmanın materyalini 24 adet sağlıklı tavşan oluşturdu. Tavşanların bel omurları çizgisinin iki yanında ve birbirine paralel 6 cm uzunluğunda tam kalınlıkta deri ensizyonları oluşturuldu. Tüm yaraların deri altı bağ dokusuna 3/0 krome katgüt iplik ile basit sürekli dikiş uygulandı. Sağ taraftaki deri ensizyonları (kontrol grubu), 3/0 ipek iplikle basit ayrı dikiş uygulanarak kapatıldı. Sol taraftaki deri ensizyonları ise (çalışma grubu), yara dudakları forseps veya parmaklarla karşı karşıya getirildikten sonra OCA doku yapıştırıcısı ile kapatıldı. Postoperatif 3, 7, 14 ve 21. günlerde 6'şar adet tavşan anestezi edilerek, histopatolojik değerlendirme, gerilim direnci ve hidroksiprolin ölçümünde kullanılmak üzere hem OCA hem de dikiş uygulanan yara hattını içine alacak şekilde 3 cm genişliğinde ve 6 cm uzunluğunda dokular alındı. Makroskobik olarak çalışma grubunda kontrol grubuna göre yangısal reaksiyonun ve kabuk oluşumunun daha az, skar oluşumunun ise bazı bölgelerde benzer ve bazı bölgelerde ise daha iyi olduğu gözlemlendi. Mikroskobik olarak çalışma grubunda kontrol grubuna göre postoperatif 3. ve 7. günlerde yangısal reaksiyonun daha az şekillendiği ve postoperatif 14. ve 21. günlerde kollajen yapının daha az olduğu belirlendi. Yara gerilim direncinin gruplar arası istatistiksel değerlendirmede farklılık arz etmediği belirlendi. Hidroksiprolin düzeylerinin çalışma grubunda kontrol grubuna göre postoperatif 3. ve 7. günlerde yüksek olduğu, 14. ve 21. günlerde ise farklılık arz etmediği saptandı. Sonuç olarak; küçük hayvanlarda ensizyonel deri yaralarının kapatılmasında OCA doku yapıştırıcısının deri altı dikişi ile birlikte hareketsiz bölgelerde kullanılabileceği kanısına varıldı.

Anahtar Kelimeler: Oktil-siyanoakrilat, Yara iyileşmesi, Tavşan

INTRODUCTION

Today, the classic suture has still a wide usage in surgery and wound repair. But it was also known that it has some

disadvantages such as granuloma and fistula formation because of the tissue incompatibility, also dehiscence of wound because of the loose sutures, leaks in organs with lumens, the delays in wound healing linked to ischemia

because of tight applications and long application duration (Spotniz et al. 1997; Scardio et al. 1999). These disadvantages directed the scientists to search an adhesive material which enables the atraumatic tissue union (Scardio et al. 1999). Presented tissue adhesive cyanoacrylate (CA) is used for closing the skin wounds and started to be used as tissue adhesive in 1950's (Toriumi et al. 1990). The liquid CA tissue adhesive was stucked firmly to the skin by hardening and turning into polymer structure when it is applied to the damp skin and it holds together the wound edges by combining them each other at the recuperation period (Lehnhardt 2000). In the previous studies, the first synthesized short chain CA derivations of methyl-cyanoacrylate and ethyl- cyanoacrylate were determined as toxic to the tissue and its usage was limited in surgery (Mattick 2002; Narang et al. 2003). Nowadays practically, OCA which is a longer chain CA derivative has been successfully used in human medicine for closing the skin incisions. Furthermore, it is known that OCA has some advantages such as having a more flexible formation than the other CA derivatives (Singer et al. 2002; Eaglstein and Sullivan 2005), and enabling to close longer incisions (Mattick 2002), having non-toxic and non-carcinogenic effect because of its topical application (Singer et al. 2002; Vauthier et al. 2003) and having 3-4 times more tensile strength than the BCA (Petratos et al. 2002; Eaglstein and Sullivan 2005). It is also known, OCA has some advantages such as shortening the operation duration in skin wound closure because of its easiness and fast usage (Singer and Thode 2004), having hemostatic effect (Nguyen et al. 2002; Singer et al. 2004) and having no need for dressing material for closure in the healing period (Singer and Thode 2004). OCA has also an antibacterial effect and preventing the wound contamination (Narang et al. 2003; Singer et al. 2003; Singer and Thode 2004), optimal wound dressing during healing period while keeping the surrounding moisten (Singer and Thode 2004). Additionally, it has no need for removing sutures and its self-removal on days 5-10 after the application (Singer et al. 2002; Singer and Thode 2004), having less infection percentage compared to classic suture (Singer et al. 2003; Singer and Thode 2004,) and less tissue reaction embodiment (Singer et al. 2003).

In the present study, it was aimed to determine the feasibility of the usage of OCA tissue adhesive in practice, its contribution to the wound repair at skin incision in rabbits and the evaluation of the material with the clinic, biometric, biochemical and histopathological diagnosis.

MATERIALS and METHODS

In this study, 24 cross-bred rabbits with different gender at the age of 12-20 months and 2,3 - 2,85 kg weight were used. The rabbits were kept in separate cages in Yuzuncu Yil University Veterinary Faculty, Research and Practice Hospital. The animals were kept in the same environment for at least one month for physiologic adaptation before the beginning of the study. At the end of this period, clinical and parasitological examination of the study group were performed. The rabbits found as healthy after the clinical examination were included to the study. The rabbits were fed by commercial pelleted diet (Purina) and water *ad libidum*. The study protocol was approved by the University of Yuzuncu Yil's Ethical Committee and the experiments were conducted in accordance with animal protection laws.

Wound creation: The rabbits were weighed and anesthetized by intramuscular injection of a combination of 50 mg/kg of ketamine hydrochloride (Ketamidol, Richterpharma) and 5 mg/kg of xylazine hydrochloride

(Rompun, Bayer). Rabbits were positioned in ventral recumbency. Two parallel full-thickness skin incisions with 6 cm length were performed under aseptic conditions on the left and right sides of each experimental rabbit dorsum and immediately subcutaneous connective tissue of all wounds were sutured by simple continuous suture pattern with 3/0 chromic gut. The right side skin incision (control group) sutured by seven simple sutures with 3/0 silk. The skin incisions at the left (OCA group) were closed with OCA (Dermabond-Ethicon) tissue adhesive by application through the incision line after approximate wound edges with forceps and fingers. After the hardening of first adhesive layer, one thin layer was applied through the incision line by paying ultimate attention not to have any leakage to the wound edges.

Suture applied wounds were dressed for 3 days in postoperative period. In the postoperative period, the wounds with OCA were not covered with any dressing material or applied any medicine.

Removal of skin wound: Six rabbits were anesthetized on postoperative days 3, 7, 14 and 21. Skin wounds removed both from the OCA and suture applied wounds which was 3 cm width and 6 cm length (Figure 1). They were used for histopathologic evaluation (Figure 1/a), tensile strength (Figure 1/b) and hydroxyproline measurement (Figure 1/c).

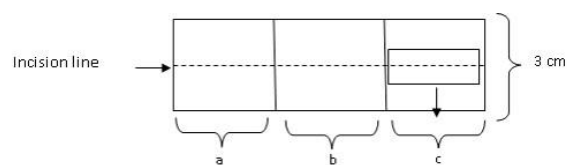


Figure 1. Postoperative wound evaluation (a: histopathological evaluation b: wound tensile strength measurement c: hydroxyproline assay)

Macroscopic examination: The scar formation and the inflammatory differences on the wound edges, the presence of complications such as dehiscence of wound and infection were evaluated and photographed.

Histopathologic examination: On postoperative days of 3, 7, 14 and 21, the tissue samples were taken both from the OCA and suture applied wounds which consist of the wounded and healthy tissue (Figure 1/a). After they were fixed with 10% formaldehyde. The tissue samples were evaluated about regarding the inflammatory cell infiltration, fibroblast proliferation, angiogenesis, collagen development and epithelialization.

Measuring the wound tensile strength: The mechanic wound tensile strength (Figure 1/b) was estimated on postoperative days 3, 7, 14 and 21 (Baie and Sheikh 2000) with a mechanic tensiometer similar with the one used in Borden et al. (1995) studies.

Determination of hydroxyproline: The skin samples were taken from the wounds (Figure 1/c) on postoperative days 3, 7, 14 and 21 and preserved in normal saline at -18°C until hydroxyproline quantity was measured. The hydroxyproline level was measured based on the photometric principle method of hydroxyproline oxidation with chloramine T and the color compound formed with dimethylaminobenzaldehyde (Anonymous 1997).

Statistical analysis: All the values were recorded as mean \pm standard error mean (mean \pm S.E.M.). The statistical evaluation of the obtained data was performed with independent *t* test for determine the statistical difference between the wounds closed with OCA and sutured by SPSS

Packet Program. The $p < 0.05$ was considered as statistically important.

RESULTS

Macroscopic findings: It was determined that OCA application was easier and had shorter application time compared to suturing. It was observed that must needs to close a wound with OCA (2.47 ± 0.83 sec) is statistically shorter than suture (3.76 ± 0.97 sec) ($p < 0.001$). It was determined that the adhesive covers the incision line as a thin film layer and hold the wound edges together. The sutures in the control group were taken out at the 7th postoperative day. Two rabbits died in 4-6 hours after the operation probably because of the anesthesia. The five sutured and OCA applied wounds ($n=5$) were evaluated on postoperative days 14 and 21. Partial blood clot was observed on the wound edges in control group on the 3rd postoperative day. Furthermore, slight inflammatory reactions were determined around the suture, while no inflammatory reactions were observed in the wounds closed with OCA wound edges. On the 7th postoperative day, necrotic wound remains were observed on the incision line in the control group. Epithelization was seen in the regions without crust. In the OCA applied wounds, it was observed that the epithelization was better than the suture applied wounds. Besides it was also observed in some cases that there were some wound crust formations on some points through the incision line.

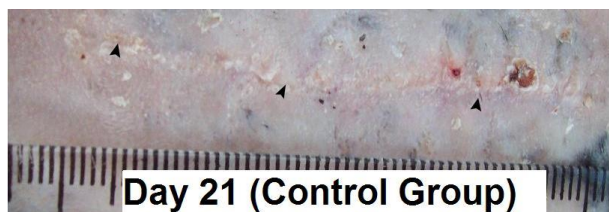

Figure 2. The view of the wound in control group at the 21 postoperative day (arrows: scar line)

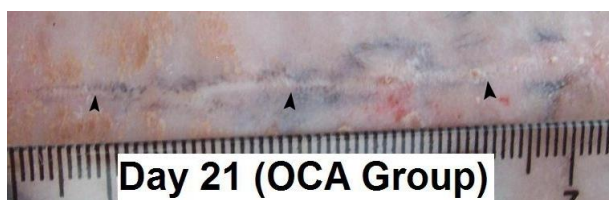


Figure 3. The view of the wound in OCA group at the 21 postoperative day (arrows: scar line)

Additionally, it was determined that the wound line was more regular than the control group. On the 14th postoperative day, it was determined that the epithelization was completed in the control group wounds but it was observed that necrotic wound formation continued in some regions. In the OCA applied wounds, it was determined that epithelization was more proper and completed earlier than the control group. It was observed in the 21st postoperative day that the scar tissue in the OCA applied wounds was better than in the suture applied. Besides it was observed that the adhesive applied to the skin didn't go off from some parts of the skin. It was not observed any infection in the during recovery period in both groups which could need treatment such as wound opening or any obvious inflammatory reaction (Figure 2 and Figure 3).

Table 1. Wound hydroxyproline findings and tensile strength

Parameter	Control group (mean \pm S.E.M)	OCA group (mean \pm S.E.M)
Hydroxyproline (mg/g)		
Day 3 (n=6)	25.22 \pm 0.77	28.03 \pm 0.95*
Day 7 (n=6)	38.99 \pm 0.41	41.38 \pm 0.87*
Day 14 (n=5)	47.03 \pm 0.70	45.62 \pm 0.77
Day 21 (n=5)	43.48 \pm 1.13	42.16 \pm 1.07
Tensile strength (g/mm²)		
Day 7 (n=6)	9.23 \pm 0.74	10.58 \pm 0.61
Day 14 (n=5)	57.61 \pm 2.63	52.23 \pm 2.11
Day 21 (n=5)	113.79 \pm 6.44	99.71 \pm 5.06

Histopathologic findings: During histopathologic examination of the tissue samples taken in the 3rd, 7th, 14th and 21st days of wound healing period, regional bleedings and a thick acute inflammatory reaction including neutrophil leukocytes on both sides of incision line starting from lamina epithelia in the control group on the 3rd day were observed. In the OCA group, it was determined that the bleeding and the acute inflammatory focuses were less than in the control group. On the 7th day postoperative, it was determined in the control group that the incision area was still open in the lamina epithelia despite the regeneration. Large necrotic areas on the lamina epithelia and on the incision line starts from lamina epithelia until tunica serosa were observed. Thick inflammatory exudates and intense bleeding foci around the necrosis were encountered. It was observed endothelial cell and fibroblast proliferation in the lamina propria. It was determined that the inflammatory reaction and the necrosis in the OCA group were fairly less than in the control group. On the postoperative day 14th, it was observed that the incision line was totally closed and epithelization was completed in the OCA group. It was observed that lamina propria was filled with fibroblasts rich chronic granulation tissue and little amount of neutrophil leukocytes. It was observed in the control group that regeneration was formed on epidermis in the incision area and epithelization was completed. But necrotic tissue presence was observed in some areas on the healthy epidermis layer around the incision line and partially through the epithelium. It was observed in the lamina propria that there were endothelium proliferation and a chronic granulation tissue which is rich with fibrosis and fibroblasts. It was determined that the connective tissue activation is fairly better than OCA group. On the 21st postoperative day, it was seen that regeneration in epidermis in both group was completed. It was followed on the incision applied dermis that there were connective tissue cells, capillary vein with empty lumen and chronic granulation tissue formation with collagen fibers. In the OCA group, the epithelization was more properly formed than in the sutured group and fibroblast proliferation was observed. It was determined that fibroblast proliferation and collagen structure in control group were richer than the OCA group.

Wound tensile strength and hydroxyproline findings: The wound tensile strength and hydroxyproline amounts belonging to control and OCA groups were presented in Table 1.

DISCUSSION

Wound treatment was the main interest area of the researchers since the beginning of medicine history. Despite, different suture materials and techniques were successfully applied. It is known that OCA can be an alternative application to the suture because it is quick and handy application. It shortens the surgery time, provides homeostasis, prevents the wound contamination and increases the wound healing (Colak et al. 1997; Ollivier et al. 2001; Kim and Gupta 2003; Singer and Thode 2004; Faria et al. 2005.).

For this reason, the presence of the tissue adhesive OCA on skin incision in the study material was evaluated with macroscopic, histopathological, biomechanical and biochemical evaluations. In this study, it was observed that the tissue adhesive statistically shortens the surgery ($p < 0,001$). It was also observed that OCA was more practical and easier in application than the suture. These evaluations are mostly similar to reference (Ollivier et al. 2001; Kim and Gupta 2003; Faria et al. 2005).

In this study, it was showed in the control group that the bleeding and the crust formation during the inflammation and proliferation phases (3rd and 7th postoperative days), the inflammatory reaction formation around the suture, exudation between wound edges and the irregular scare formation were more present than the OCA group.

These results are comparable with the researchers' (Spotniz et al. 1997; Scardio et al. 1999) it can occurred because of the trauma caused by the needle passing through tissues during suture and because of the exudate between the two sutures. Despite postoperative care was taken to the wounds during recovery period, it was determined that the wound crust formation and bleeding were less and there was no inflammatory reaction. It was observed in the maturation period (14th and 21st postoperative days) that the epithelialization in the OCA group was formed faster than the control group, the wound line was more proper and the scar tissue was stronger. This situation can be explained as the adhesive protects the wound line as a natural covering material during healing process while both inhibiting the wound contamination and keeping the wound line damp which leads the capillaries have a quick and early formation (Bello 2002; Singer et al. 2003). In researches performed by Dalvi et al. (1986) in humans and Hampel et al. (1991) in rabbits was found that the macroscopic inflammatory reaction in OCA group was less than the suture group and the skin surfaces were flatter. In the study about the evaluation of the effect of BCA and silk suture on skin incision during wound healing (Colak et al. 1997); it was found that any distinctive inflammation and dehiscence on the wound edges in the BCA group were not macroscopically observed. In our study, the results were similar to other researcher (Dalvi et al. 1986; Hampel et al. 1991; Colak et al. 1997).

In this study, any dehiscence of wounds in the OCA group which need futures treatment was observed in the early and late periods of wound healing. Our results are similar with the reports of the authors (Colak et al. 1997; Lehnhardt 2000; Singer et al. 2002; Singer and Thode 2004) which found that the ratio of the dehiscence of wounds in the wounds closed with CA adhesives need medical treatment was rather low. All the suturing materials are artificial substances for the tissues and cause direct tissue reaction (Nomori et al. 2000). The polymorph nuclear leukocyte infiltration between the 1-4 days of implantation and macrophage infiltration between the 4-7 days are

histologically formed in the tissues against suture material (Lomborn et al. 1970).

In the control group, the presence of acute inflammatory infiltration in the early phases of wound healing is similar to the references (Nomori et al. 2000).

BCA and silk suture on the wound healing was found that the inflammatory reaction in the BCA applied wounds in the early phases of the wound healing was less present and there was no any difference in the 21st postoperative day between the groups (Nomori et al. 2000; Borba et al. 2000).

It was found during an experimental study in the cats that the morphologic effects of suture and BCA tissue adhesive in closing the skin incisions were discussed that it was not observed any differences between the groups in the postoperative days 14th and 21st (Queiroz et al. 2001). In this study, the histological findings are compatible with many references (Borba et al. 2000, Queiroz et al. 2001; Bello 2002). In the present study, the foreign body reaction due to the external usage of the OCA tissue adhesive and any presence of toxic effects show similarities with the references (Gueiros 2001).

It is known that CA has effect on the gram positive (Eaglstein and Sullivan 2005) and negative bacteria (Toriumi et al. 1990; Singer and Thode 2004). Narang et al. (2003) found that OCA has a wonderful antimicrobial characteristic against gram positive and some gram negative bacteria. In this study, the first 3 days' covering of the control group were done despite the OCA group wounds were not covered and no infection was present in any wound in the postoperative time. This situation can be explained by OCA's antibacterial properties (Toriumi et al. 1990; Narang et al. 2003; Singer and Thode 2004; Eaglstein and Sullivan 2005).

The important result of the wound healing period after surgery is the wound tension force's comes to the normal tissue surface (Engin 2004). It is found that the regeneration tie and quality in the closed incise wounds healing were examined by measuring the best tensile strength (Tekin et al. 2001). Skin incisions in rats were closed with different suture materials, BCA (Toriumi et al. 1990; Kothe et al. 2000) and OCA (Petratos et al. 2002); it was found that there was no difference between the wounds closed with tissue adhesives and the suture regarding the wound tension in the 7th (Petratos et al. 2002), 14th (Kothe et al. 2000), 7th and 20th postoperative days (Toriumi et al. 1990). On the other hand, it was found that the wound tension in the incisional wounds in the rats which was closed with CA derivatives (by applying between wound edges) was statistically less important than the wounds closed with suture (Lomborn et al. 1970) in the 7th and 28th postoperative days. It was determined that the wound tension of OCA group in the 7th postoperative day was slightly more than the control group despite there was no statistical difference. This situation was explained by the strong adhesion on the wound edges caused by adhesive do not come off completely from the wound line (Lomborn et al. 1970) and the inflammatory reaction's being less (Schwarz et al. 1995). However, the wound breaking strength in the 14-21 postoperative days which is similar with histopathologic findings was not found statistically important despite it was less in the OCA group than the control group. This reduction can be explained with the correlation between collagen accumulation and wound tension (Nayak et al. 2006). Our findings were similar with many references (Toriumi et al. 1990; Kothe et al. 2000; Petratos et al. 2002) and different from other (Lomborn et al. 1970). This difference can be because of precise

application, not to have the adhesive leakage between wound edges and OCA's having more tension resistance than the other CA derivatives. In this study, the wound resistance showed less progress in the inflammation phase and increasing progress in proliferation phase. This situation can be explained with the existence of the fibrin clot between the wound edges which provides a weak wound strength in the inflammatory phase of wound healing and the increase of the collagen amount which is responsible for the wound strength in the following phases (Jorgensen et al. 1987; Pascoe 1991; Engin 2004).

Collagen consists of 9% hydroxyproline opposite from the other proteins and this amino acid can be hardly found in other proteins (Lomborn et al. 1970; Engin 2004). Hydroxyproline is important in stabilization of collagen triple helix formation (Lomborn et al. 1970). It is reported that the hydroxyproline measurement is directly proportional with the collagen amount (Jorgensen et al. 1987). In this study, hydroxyproline amount in 3rd and 7th postoperative days in OCA group was statistically higher to a considerable extend ($p < 0.05$) than in control group. The lower hydroxyproline values in control group can be explained with the procollagen breakdown (Schwarz et al. 1995) parallel with collagenase, elastase and hydrolyses enzymes increase (Demir et al. 2004) with the result of protease activity induction (Schwarz et al. 1995) of the having much inflammatory reaction (Schreiber et al. 2005; Muehlberger et al. 2005). In our study, it was found that there was no statistical difference in hydroxyproline amount between the groups in the 14th and 21st postoperative days and there was no correlation between hydroxyproline and the wound resistance. The data can be explained by the wound resistance because of the increase of the present collagen intra-inter molecular covalent bonds and related with collagen fiber order and maturation (Pascoe 1991, Engin 2004).

It was understood that OCA tissue adhesive, which is used to close the incisional wounds with a thin layer film application, following subcutaneous suture, can be used in the incisional wound closing during small animal surgeries together with subcutaneous suture in the inactive areas.

REFERENCES

- Anonymous (1997).** Et ve et mamulleri - hidroksiprolin muhtevasi tayini, TSE 6236, ISO 3496.
- Baie SH, Sheikh KA (2000).** The wound healing properties of Channa striatus-cetrimide cream-tensile strength measurement. *J Ethnopharmacol*, 71, 93-100.
- Bello TR (2002).** Practical treatment of body and open leg wounds of horses with bovine collagen, biosynthetic wound dressing and cyanoacrylate. *J Equine Vet Sci*, 22(4), 157-164.
- Borba CC, Roubaud net weight AND, Val RLR, et al. (2000).** Use of cyanoacrylate the surgical adhesive in rats skin incisions: experimental study. *Acta Cir Bras*, 15(1), 48-54.
- Borden EB, Sammartano RJ, Dembe, Boley SJ (1985).** The effect of metronidazole on wound healing in rats. *Surgey*, 97(3), 331-336.
- Colak A, Okumuş Z, Aslan S (1997).** Use of Enbucrilate in the closing of skin incisions in dogs. *Kafkas Üniv Vet Fak Derg*, 3(1), 43-47.
- Dalvi A, Faria M, Pinto A (1986).** Non-suture closure of wound using cyanoacrylate. *J Postgrad Med* 32(2), 97-100.
- Demir H, Yaray S, Kirnap M, Yaray K (2004).** Comparison of the effects of laser and ultrasound treatments on experimental wound healing in rats. *J Rehabil Res Dev*, 41(5), 721-728.
- Eaglstain W, Sullivan T (2005).** Cyanoacrylates for skin closure. *Dermatol Clin*, 23, 193-198.
- Engin A (2004).** Yara iyileşmesi. In: Temel Cerrahi, Sayek İ. (Ed), 266-277, Güneş Kitabevi, Ankara.
- Faria MCF, de Almeida FM, Serrao ML, de Oliveria Almeida NK, Labarthe N (2005).** Use of cyanoacrylate in skin closure for ovariohysterectomy in a population control programme. *J Feline Med Surg*, 7, 71-75.
- Gueiros VA, Borges APB, Silva JCP, Duarte TS, Franco KL (2001).** Utilization of the methyl-2-cyanoacrylate adhesive and the nylon suture in surgical skin wounds of dogs and cats. *Cienc Rural*, 31(2), 285-289.
- Hampel NL, Johnson RG, Pijanowski GJ (1991).** Effects of isobutyl-2-cyanoacrylate on skin healing. *Compend Contin Educ Pract Vet*, 13(1), 80-83.
- Jorgensen PH, Jensen K, Andreassen TT (1987).** Mechanical strength in rat skin incisional wounds treated with fibrin sealant. *J Surg Res* 42(3), 237-241.
- Kim YM, Gupta BK (2003).** 2-octyl cyanoacrylate adhesive for conjunctival wound closure in rabbits. *J Pediatr Ophthalmol Strabismus*, 40(3), 152-155.
- Kothe W, Patzelt K, Anke H, Theel L (2000).** Hautklebungen an der ratte zschr, *Chirurgie*, 93, 197-204.
- Lehnhardt FJ (2000).** Report on experience with the application of tissue adhesives in experimental and small animal surgery. *Ir Vet J*, 50(2), 99-106.
- Lomborn PB, Soloway HB, Matsumoto T, Aaby GV (1970).** Comparison of tensile strength of wounds closed by sutures and cyanoacrylates. *Am J Vet Res*, 31(1), 125-130.
- Mattick A (2002).** Use of tissue adhesives in the management of paediatric lacerations. *Emerg Med J*, 19, 382-385.
- Muehlberger T, Moresi JM, Schwarze H, Hristopoulos G, Laenger F, Wong L (2005).** The effect of topical tretinoin on tissue strength and skin components in a murine incisional wound model. *J Am Acad Dermatol* 52(4), 583-588.
- Narang U, Mainwaring L, Spath G, Barefoot J (2003).** In-vitro analysis for microbial barrier properties of 2-octyl cyanoacrylate-derived wound treatment films. *J Cutan Med Surg*, 7(1), 13-19.
- Nayak S, Nalabothu P, Sandiford S, Bhogadi V, Adogwa A (2006).** Evaluation of wound healing activity of Allamanda cathartica L. and Laurus nobilis L. extracts on rats. *BMC Complement Altern Med*, 6(12), 1-6.
- Nguyen AJ, Baron TH, Burgat LJ, Leontovich O, Rajan E, Gostout CJ (2002).** 2-octyl-cyanoacrylate (Dermabond), a new glue for variceal injection therapy: Results of a preliminary animal study. *Gastrointest Endosc* 55(4), 572-575.
- Nomori H, Horio H, Suemasu K (2000).** The efficacy and side effects of gelatin-resorcinol formaldehyde gluteraldehyde (DRFG) glue for preventing and sealing pulmonary air leakage. *Surg Today*, 30(3), 244-248.
- Ollivier F, Delverdier M, Regnier A (2001).** Tolerance of rabbit cornea to n-butyl-ester cyanoacrylate adhesive (Vetbond®). *Vet Ophthalmol*, 4(4), 261-266.
- Pascoe JR (1991).** Wound healing. In: Atlas of Small Animal Surgery, Gourley I.M., Gregory C.R. (Eds), 2-13, Gower Medical, New York.
- Petratos BP, Rucker GG, Soslow R.A, Felsen D, Poppas DP (2002).** Evaluation of octylcyanoacrylate for wound repair of clinical circumcision and human skin incisional healing in a nude rat model. *J Urol*, 167(2), 677-679.
- Scardino MS, Swaim SF, Morse SB, Sartin EA, Wright JC, Hoffman CE (1999).** Evaluation of fibrin sealants in cutaneous wound closure. *J Biomed Mater Res*, 48, 315-321.
- Schreiber J, Efron PA, Park JE, Moldawer LL, Barbul A (2005).** Adenoviral gene transfer of an NF-κB super-repressor increases collagen deposition in rodent cutaneous wound healing. *Surgery*, 138 (5), 940-946.
- Schwarz DA, Lindblad WJ, Rees RS (1995).** Altered collagen metabolism and delayed healing in a novel model of ischemic wounds. *Wound Repair Regen*, 3, 204-212.
- Singer AJ, Quinn JV, Clark RE, Hollander JE (2002).** Closure of lacerations and incisions with octylcyanoacrylate: A multicenter randomized controlled trial. *Surgery* 131(3), 270-276.
- Singer AJ, McClain SA, Katz A (2004).** A porcine epistaxis model: Hemostatic effect of octylcyanoacrylate. *Otolaryngol Head Neck Surg*, 130(5), 553-557.
- Singer AJ, Thode HC (2004).** A review of the literature on octylcyanoacrylate tissue adhesive. *Am J Surg*, 187, 238-248.
- Queiroz GF de, Paula VV de, Reis RK, Dos, Tabosa IM (2001).** Employment of n-butyl-2-cyanoacrylate adhesive and nylon for skin closure in cats. *Rev Bras Med Vet* 23(3), 126-129.
- Tekin E, Taneri F, Ersoy E et al. (2001).** The effects of glutamine-enriched feeding on incisional healing in rats. *Eur J Plast Surg*, 23, 78-81.
- Toriumi DM, Raslan WF, Fredman M (1990).** Histotoxicity of cyanoacrylate tissue adhesives. A comparative study. *Arch Otolaryngol Head Neck Surg*, 116, 546-550.