

# Isolated Zygomatic Arch Fracture: A Case Report

## *İzole Zigomatik Ark Kırığı: Bir Olgu Sunumu*

Hasan Onur Şimşek<sup>1</sup>, Gökhan Özkan<sup>2</sup>, Umut Demetoğlu<sup>1</sup>, Burcu Gürsoytrak<sup>1</sup>, Özlem Kocatürk<sup>1</sup>

<sup>1</sup>Adnan Menderes University Faculty of Dentistry, Department of Oral and Maxillofacial Surgery, Aydın, Turkey

<sup>2</sup>Adnan Menderes University Faculty of Dentistry, Department of Oral and Maxillofacial Radiology, Aydın, Turkey



### Abstract

Zygomatic bone is situated at the lateral part of the facial triangle, and is frequently exposed to maxillofacial traumas, since it forms the most prominent region of the facial skeleton. Isolated zygomatic arch fractures comprise 5% of all facial fractures and 10% of zygomatic bone fractures. In this case report, the clinical and radiological characteristics, and the treatment options of isolated zygomatic arch fractures have been discussed. The traumatic zygomatic arch fracture of the left zygomatic arch region of a 35-year-old male patient and its treatment have been reported in this case report. The Gillies method should be considered as an effective treatment method in isolated zygomatic arch fracture cases due to its feasibility and esthetic properties.

### Keywords

Zygomatic arch, trauma, Gillies method

### Anahtar Kelimeler

Zigomatik ark, travma, Gillies metodu

Received/Geliş Tarihi : 05.06.2017

Accepted/Kabul Tarihi : 07.07.2017

doi:10.4274/meandros.52824

### Address for Correspondence/Yazışma Adresi:

Hasan Onur Şimşek MD,  
Adnan Menderes University Faculty of  
Dentistry, Department of Oral and Maxillofacial  
Surgery, Aydın, Turkey  
Phone : +90 535 856 44 00  
E-mail : hasanonursimsek@yahoo.com  
ORCID ID: orcid.org/0000-0001-9628-3014

©Meandros Medical and Dental Journal, Published by  
Galenos Publishing House.  
This is article distributed under the terms of the  
Creative Commons Attribution NonCommercial 4.0  
International Licence (CC BY-NC 4.0).

### Öz

Zigomatik kemik, yüzün orta üçlü yan bölümünde bulunan yüzün en çıkıntılı bölgesi olarak maksillofasiyal travmalara sık maruz kalmaktadır. İzole zigomatik ark kırıkları, tüm yüz kırıklarının %5'ini ve zigomatik kemik kırıklarının da %10'unu oluşturur. Bu raporda izole zigomatik ark kırıklarının klinik ve radyolojik özellikleri ve tedavi seçenekleri tartışılmıştır. Bu olgu sunumunda 35 yaşında erkek hastanın sol zigomatik ark bölgesinde travma sonrası oluşan izole zigomatik ark kırığı ve tedavisi rapor edilmiştir. İzole zigomatik ark kırığı olgularında, Gillies metodu uygulanabilirlik ve estetik özelliklerinden dolayı etkin bir tedavi alternatifi olarak düşünülmelidir.

### Introduction

The zygomatic bone is the most prominent bone of the facial region situated at the lateral part of the facial triangle, and is articulated with the maxilla, frontal and temporal bones. Zygomatic bone fractures are common in face traumas. Isolated zygomatic arch fractures comprise 5% of all facial traumas and 10% of zygomatic bone fractures (1,2). Zygomatic arch fractures are commonly observed as “greenstick” fractures approximately 1.5 cm posterior to the zygomatico-temporal suture.

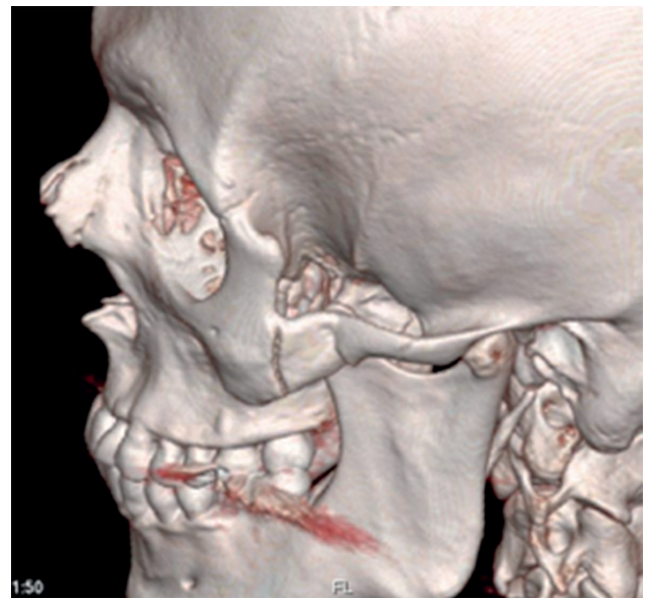Ecchymosis and edema may be observed in the periorbital region and buccal sulcus in zygomatic arch fractures, and asymmetry, pain and trismus may be observed in the face. The most frequent cause of admission to dentists in zygomatic arch fractures is the limited opening ability of the mouth, which is observed in approximately 45% of zygomatic arch fractures (3). Limited mandibular motion is the result of the seizing up of the coronoid process to the displacing part of the zygomatic arch inward during opening of the mouth (3,4). Furthermore, the mandible is deviated to the fractured side during the opening of the mouth.

Various intraoral and extra-oral approaches have been used as closed reduction techniques in isolated zygomatic arch fractures. The Gillies methods, first described by Gillies et al. (5) in 1927, have been used closed reduction technique for zygomatic arch fractures (6). In this report, an isolated zygomatic arch fracture case has been presented with the diagnostic and therapeutic approaches to zygomatic arch fractures in the light of the literature.

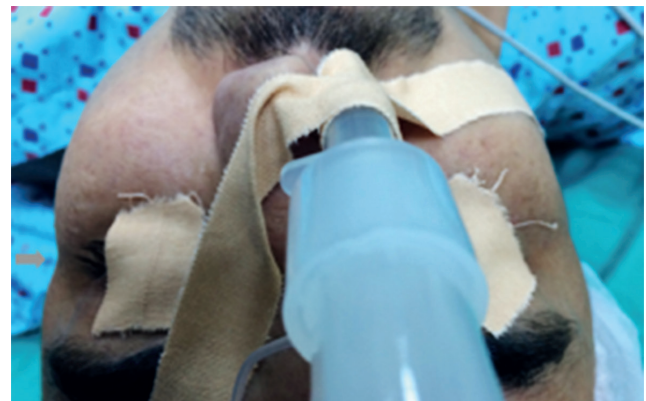### Case Report

In the computed tomographic examination of the 35-year-old male patient who was referred from the emergency unit of the medical faculty to our clinics with the complaints of post-traumatic limited mouth opening and pain, a fracture line was observed in the left zygomatic arch region with a displaced angled inward in a “greenstick” style, where the mandible was in contact with the coronoid process (Figure 1). The mouth opening of the patient was measured as 9 mm. In the extra-oral examination of the region, collapse of the left zygomatic arch and asymmetry compared to the opposite arch, and infraorbital ecchymosis and swelling were observed (Figure 2). No fracture line other than the isolated zygomatic fracture was observed considering the images. No visual function disorder or fracture of the orbital region or the surrounding tissues was detected on the consultation with the eye clinic. Under general anesthesia, the patient underwent an operation with the indication of isolated zygomatic arch fracture. The hairy skin was shaved 2.5 cm anterior and superior to the ear curve. The ramus parietalis-ramus frontalis division of the superficial temporal artery was defined,

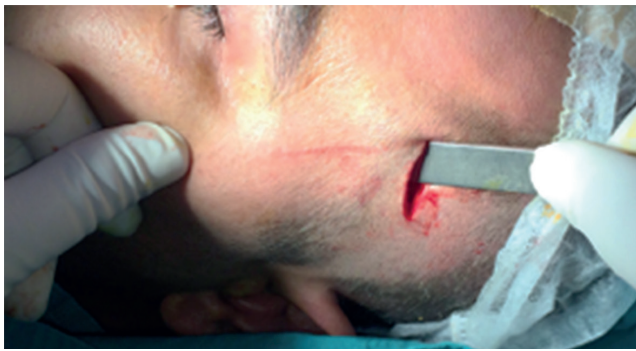a 2 cm skin incision was performed and advanced until the temporal fascia dissecting the subcutaneous tissues. The superficial fascia of the temporal muscle was incised. The zygomatic arch was accessed by advancing downwards through the temporal muscle and fascia with the help of an elevator. Reduction was performed for the fractured part. The reduction of the fractured bones and the symmetry of both arches were checked over the zygomatic arch by palpation during the operation (Figure 3). The cutaneous and subcutaneous tissues were primarily sutured and the operation was terminated. Post-operative computed tomography examination revealed the continuity of



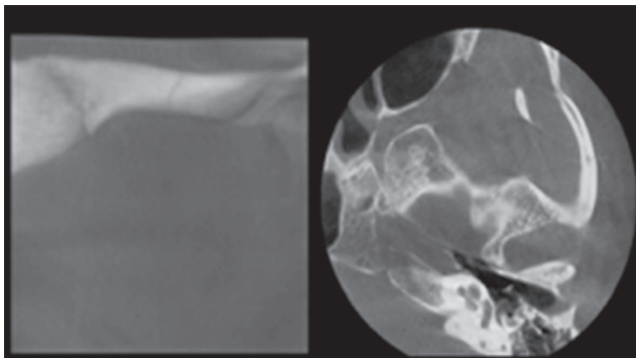
**Figure 1.** Pre-operative 3-dimensional computed tomography image of the patient; isolated zygomatic arch fracture is visualized



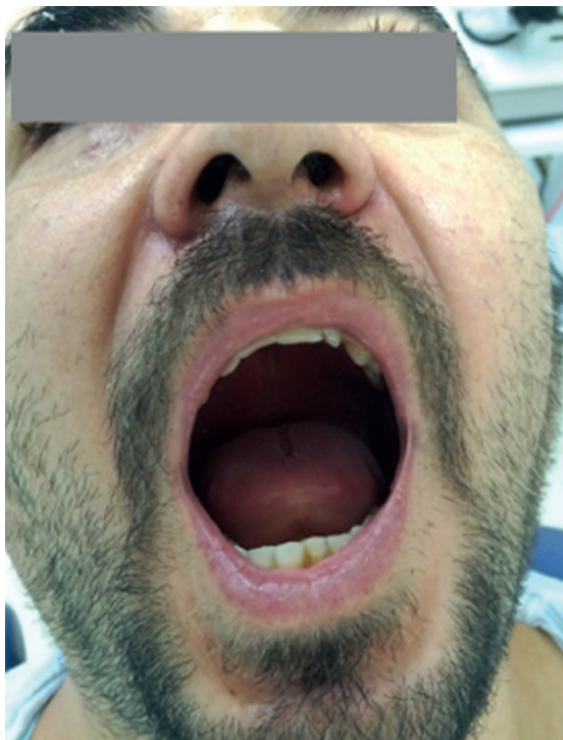
**Figure 2.** Pre-operative extra-oral image of the patient. Collapse is observed in the left zygomatic arch region



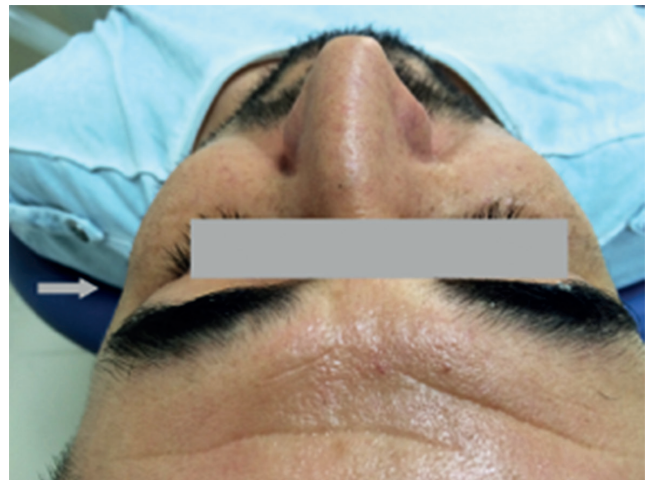**Figure 3.** The intraoperative image of the patient. Palpation control after reduction of the fractured bones



**Figure 4.** The post-operative dental volumetric tomographic image of the patient, bone continuity is visualized



**Figure 5.** Post-operative mouth opening image of the patient (6<sup>th</sup> month)



**Figure 6.** Post-operative extra-oral image of the patient (6<sup>th</sup> month)

the zygomatic arch (Figure 4). The mouth opening of the patient was measured as 27 mm in the early post-operative period, and 38 mm at the 6<sup>th</sup> month. No difficulty or pain was observed during mouth opening. No pain, sensitivity of asymmetry compared to the opposite arch was observed in the zygomatic arch region of the patient was observed in the extra-oral examination of the patient (Figure 5, 6). The patient's clinical 12-month follow-up was uneventful.

### Discussion

The zygomatic bone is situated at the lateral part of the triangle of the face, and is exposed to maxillofacial traumas frequently due to its anatomic positioning. Zygomatic bone fractures may either be observed in an isolated zygomatic arch fracture form or in form of complex fractures. For classification of the fractures, the fracture may be named together with the neighboring bone classically (6,7) or the new classification system may be used (1).

A periorbital fracture may be considered in zygomatic region fractures. Pre-operative radiological examination should be performed in detail and consultation from the ophthalmologists should be requested with regard to the deformity of the orbital region, diplopia, enophthalmos, or similar complications (8). Early diagnosis and surgical intervention with accurate timing are important in zygomatic arch fractures. Surgical intervention is suggested within one week after the trauma (9). Fibrous ankylosis cases may be observed related



to the delays in the treatment of zygomatic arch fractures, which may consequently lead to limitations in mouth opening (10).

Zygomatic arch fractures may primarily be evaluated via panoramic radiography. In suspicious cases, a radiography obtained using the submentovertex technique is an important tool in investigating the fracture line along the arch. It should be considered that the radiolucence image of the zygomatico-temporal suture may be misjudged as a fracture. In cases with insufficient two-dimensional imaging or for those in whom the fracture line should be examined in detail, dental volumetric tomography may be used to obtain high resolution images. In particular, the axial sections enable a clear visualization of the zygomatic arch, and the fracture segments and the asymmetry may be observed clearly via three-dimensional imaging (3,4,11). Ultrasonography and fluoroscopy may be used for intraoperative imaging (12). In addition to these methods, the computed navigation technique is a facilitating method in defining the position and evaluating the accuracy of the post-operation localizations of the segments (13).

The Gillies method (temporal approach) (5), Keen's technique (the buccal sulcus approach) (14), the lateral coronoid approach (15), the eyebrow elevation approach (16) and the percutaneous approach (17) have been used as closed reduction techniques in zygomatic arch fractures. In the operation presented herein, the Gillies method was preferred since it enabled the concealing of the scar, protection of the facial nerve, and easy applicability within a short time. The Gillies method has been shown to give successful outcomes with regard to stabilization and esthetic means in long term studies (12,18).

Isolated zygomatic arch fractures may frequently be observed in maxillofacial region injuries. Cases with zygomatic arch fractures may successfully be treated via the Gillies method in a closed manner. Consistent with the presented case herein, this method may be preferred as a successful treatment alternative in uncomplicated zygomatic arch fractures to provide an effective treatment and minimize the risk of complications for both the patient and the physician.

#### **Ethics**

**Informed Consent:** Informed consent was obtained from patient.

**Peer-review:** Internally peer-reviewed.

#### **Authorship Contributions**

Surgical and Medical Practices: H.O.Ş., U.D., B.G., Ö.K., Concept: H.O.Ş., G.Ö., Design: H.O.Ş., G.Ö., Data Collection or Processing: G.Ö., Ö.K., Analysis or Interpretation: Ö.K., Literature Search: H.O.Ş., Writing: H.O.Ş., G.Ö.

**Conflict of Interest:** No conflict of interest was declared by the authors.

**Financial Disclosure:** The authors declared that this study received no financial support.

#### **References**

1. Kim J, Kim S, Chung S, Chung YK. Zygomatic arch fracture: a new classification and treatment algorithm with epidemiologic analysis. *J Craniofac Surg* 2014; 25: 1389-92.
2. Swanson E, Vercler C, Yaremchuk MJ, Gordon CR. Modified Gillies approach for zygomatic arch fracture reduction in the setting of bicoronal exposure. *J Craniofac Surg* 2012; 23: 859-62.
3. Adam AA, Zhi L, Zu Bing LZ, Zhong Xing WU. Evaluation of treatment of zygomatic bone and zygomatic arch fractures: a retrospective study of 10 years. *J Maxillofac Oral Surg* 2012; 11: 171-6.
4. Mermod M, Zweifel D, Hoarau R, Broome M. Isolated bilateral zygomatic arch fracture: an unusual pattern. *J Craniofac Surg* 2014; 25: 1111-2.
5. Gillies HD, Kilner TP, Stone D. Fractures of the Malar-zygomatic compound: With a description of a new X-ray position. *Br J Surg* 1927; 14: 651-6.
6. Ellis E, Kittidumkerng W. Analysis of treatment for isolated zygomaticomaxillary complex fractures. *J Oral Maxillofac Surg* 1996; 54: 386-400.
7. Zingg M, Laedrach K, Chen J, Chowdhury K, Vuillemin T, Sutter F, et al. Classification and treatment of zygomatic fractures: a review of 1,025 cases. *J Oral Maxillofac Surg* 1992; 50: 778-90.
8. al-Qurainy IA, Stassen LF, Dutton GN, Moos KF, el-Attar A. Diplopia following midfacial fractures. *Br J Oral Maxillofac Surg* 1991; 29: 302-7.
9. Hwang K, Kim DH. Analysis of zygomatic fractures. *J Craniofac Surg* 2011; 22: 1416-21.
10. Baykul T, Aydın A, Nasır S, Aksoy MÇ. İhmal Edilmiş Zigoma Kırığı Sonucu Oluşan Fibröz Ankiloz. *Türkiye Klinikleri J Dental Sci* 2008; 14: 102-5.
11. Czerwinski M, Ma S, Williams HB. Zygomatic arch deformation: an anatomic and clinical study. *J Oral Maxillofac Surg* 2008; 66: 2322-9.
12. Yamamoto K, Murakami K, Sugiura T, Fujimoto M, Inoue M, Kawakami M, et al. Clinical analysis of isolated zygomatic arch fractures. *J Oral Maxillofac Surg* 2007; 65: 457-61.
13. Li Z, Yang RT, Li ZB. Applications of Computer-Assisted Navigation for the Minimally Invasive Reduction of Isolated Zygomatic Arch Fractures. *J Oral Maxillofac Surg* 2015; 73: 1778-89.

14. WW K. Surgery, its principles and practice. Philadelphia: WB Saunders; 1909.
15. Quinn J. Lateral coronoid approach for intraoral reduction of fractures of the zygomatic arch. J Oral Surg 1977; 35: 321-2.
16. Shumrick D. Malar and zygomatic fractures. Maxillofacial Trauma: Williams and Wilkins Baltimore, MD; 1984: 303-8.
17. Poswillo D. Reduction of the fractured malar by a traction hook. Br J Oral Surg 1976; 14: 76-9.
18. af Geijerstam B, Hultman G, Bergström J, Stjärne P. Zygomatic fractures managed by closed reduction: an analysis with postoperative computed tomography follow-up evaluating the degree of reduction and remaining dislocation. J Oral Maxillofac Surg 2008; 66: 2302-7.