

Evaluation of Different Root Canal Filling Methods in Primary Teeth

Süt Dişlerinde Farklı Kök Kanal Dolum Yöntemlerinin Değerlendirilmesi

Sezin Özer¹, Emine Şen Tunç¹, Elif Kalyoncuoğlu¹, Banu Gülcan²

¹Ondokuz Mayıs University Faculty of Dentistry, Department of Pedodontics, Samsun

²Private Clinic, Kocaeli, Turkey



Keywords

Digital radiography, root canal obturations, Metapex®, ultrasonic aid

Anahtar Kelimeler

Dijital radyografi, kök kanal dolgusu, Metapex®, ultrasonik aktivasyon

Received/Geliş Tarihi : 07.06.2017

Accepted/Kabul Tarihi : 08.08.2017

doi:10.4274/meandros.13008

Address for Correspondence/Yazışma Adresi:

Sezin Özer MD,
Ondokuz Mayıs University Faculty of Dentistry,
Department of Pedodontics, Samsun
Phone : +90 532 553 87 89
E-mail : sezinsezgin78@yahoo.com
ORCID ID: orcid.org/0000-0002-5795-6287

©Meandros Medical and Dental Journal, Published by Galenos Publishing House.
This is article distributed under the terms of the Creative Commons Attribution NonCommercial 4.0 International Licence (CC BY-NC 4.0).

Objective: To compare the efficacy of 5 different methods for filling primary teeth root canals by digital radiography.

Materials and Methods: A total of 50 extracted primary anterior teeth with no more than 25% root resorption were prepared using Mtwo® NiTi rotary instruments to a standard apical file size. Teeth were randomly divided into 5 groups, as follows according to the sealer application method. Group 1: Metapex® syringe (control); group 2: Metapex® syringe and Endoactivator® (sonic activation); group 3: Metapex® syringe and indirect ultrasonic activation; group 4: Endodontic irrigation needle; group 5: Lentulo spiral. Photostimulated phosphor radiographs of canals were evaluated for length of filling (underfilled, suboptimally filled, optimally filled, overfilled) and quality of filling (presence, localization and total sum of voids). Data was statistically analyzed using Kruskal-Wallis and Bonferroni-corrected Mann-Whitney U tests.

Results: For the both length and the quality of the filling the worse results were seen in the endodontic irrigation needle group (group 4) ($p < 0.05$). However, there were no significant differences between the other groups ($p > 0.05$).

Conclusion: Based on the results of this study apart from the endodontic irrigation needle group, all the tested methods could be used for obturation of primary teeth.

Öz

Amaç: Süt dişleri kök kanallarının dolumu için kullanılan beş farklı metodun etkinliğinin dijital radyografi yöntemiyle karşılaştırılmasıdır.

Gereç ve Yöntemler: Çalışmada kök rezorpsiyonu %25'ten fazla olmayan toplam 50 adet çekilmiş süt ön diş kullanıldı. Dişler, Mtwo® NiTi döner aletler kullanılarak standart bir apikal genişlik elde edilecek şekilde hazırlandı. Dişler rastgele 5 gruba ayrıldı: grup 1: Metapex® şırınga (kontrol); grup 2: Metapex® şırınga ve Endoaktivatör® (sonik aktivasyon); grup 3: Metapex® şırınga ve indirekt ultrasonik aktivasyon grup 4: Endodontik irrigasyon iğnesi; grup 5: Lentulo spiral. Kanalların fosfor plakla alınmış radyografik görüntüleri ile kanal dolusunun uzunluğu (yetersiz, ideale yakın, ideal ve taşkın dolgu) ve kalitesi (boşlukların varlığı, lokalizasyonu ve toplam alanı) değerlendirildi. Veriler istatistiksel olarak Kruskal-Wallis ve Bonferroni-düzeltilmeli Mann-Whitney U testleri kullanılarak analiz edildi. **Bulgular:** Kök kanal dolumları hem uzunluk hem de kalite anlamında

değerlendirildiğinde en kötü sonuçlar endodontik irrigasyon iğnesi grubunda elde edildi (grup 4) ($p<0,05$). Bununla birlikte diğer gruplar arasında istatistiksel olarak anlamlı bir fark bulunamadı ($p>0,05$).

Sonuç: Çalışmanın sonuçlarına göre; endodontik irrigasyon iğnesi grubu dışında tüm test edilen yöntemler süt dişlerinin kanal dolgusu sırasında kullanılabilir.

Introduction

Pulpectomy treatment is one option for maintaining primary teeth diagnosed with pulpal tissue inflammation involving radicular or nonvital pulp until normal exfoliation (1). The treatment consists of extirpation of the infected pulp tissue, removal of debris from the canal and obturation with resolvable antibacterial paste (2). The success of primary teeth root canal pulpectomy depends on several factors, including the adequacy of biochemical preparations, the material used in obturation, and a hermetic seal with minimal voids. How the obturating material is mixed and the technique used for obturation also significantly affects the success of primary teeth root-canal treatment (3,4).

The most popular root-canal filling materials for primary teeth have been zinc oxide eugenol, calcium hydroxide and iodoform-based pastes (2,5). In addition, pastes containing a mixture of calcium hydroxide and iodoform have recently come into more frequent use as a primary root-canal filling material and have demonstrated good clinical and radiographic success (6,7).

A variety of methods can be used to deliver paste into primary teeth root canals, including an endodontic pressure syringe (8), a disposable tuberculin syringe, a local anesthetic syringe (2) and a NaviTip syringe (9). Endodontic pluggers may also be used, especially in long straight canals and a Lentulo spiral mounted on a slow-speed handpiece can be used in both straight and curved narrow canals (10).

Ultrasound has been used extensively in dentistry for many years, mainly for its ability to enhance polishing and plaque and tartar removal from tooth surfaces (11). Its effects on viscosity and voids have also made it useful in restorative dentistry (12), and its use in endodontics has become more frequent in recent decades, particularly in applications such as gaining access to canal openings, cleaning and shaping, obturation of root canals, removal of intracanal materials and obstructions, and endodontic surgery (13).

The ideal root canal filling technique must provide complete filling of the canal, with no overfill and with minimal or no voids (14). While there is currently no agreement as to which technique provides the best sealing of root-canal filling material in primary teeth, it may be hypothesized that ultrasonic and sonic aid can improve condensation and adaptation of root-canal filling pastes in primary anterior teeth. Therefore, the aim of this study was to compare using digital radiography the sealing ability of Metapex®, a mixture of calcium hydroxide and iodoform, applied using 5 different techniques: 1. Metapex® syringe (control); 2. Metapex® syringe and EndoActivator® (sonic activation); 3. Metapex® syringe and indirect ultrasonic activation; 4. Endodontic irrigation needle; and 5. Lentulo spiral.

Materials and Methods

The study was approved by the Ondokuz Mayıs University Human Research and Ethics Committee (approval no: 2014/682). The study was conducted with 50 extracted primary anterior teeth. Teeth with more than 25% root resorption, signs of root-canal obstruction or root anomalies, or previous endodontic treatment were excluded. Moreover, in order to standardize samples, only teeth whose canals had a curvature of less than 15 degrees, as determined by Schneider's method (15) were included. Teeth were immersed in 5.25% sodium hypochlorite (NaOCl) for 24 hours and stored in saline solution until use.

Root Canal Preparation

All canals were prepared and filled by a single operator. A standard access cavity was prepared in each tooth, a #10 K file (Mani Co, Tokyo, Japan) was introduced into the canal until the tip was just visible at the apical foramen, and working length was determined as 1.0 mm short of the apical foramen. Root canals were instrumented with Mtwo® NiTi rotary files up to size 35/0.06 at working length. Canals were irrigated between each instrument with 1 mL of 2.5% NaOCl using a 21-gauge needle attached to a 10 mL syringe. After instrumentation was complete, canals were flushed with 1 mL of 17%

ethylenediaminetetraacetic acid, followed by 5 mL of 2.5% NaOCl to remove the smear layer, and then dried (16).

The apices of the prepared roots were covered with red wax to prevent any extrusion of the filling material. The roots were mounted in 1x1 cm cold-cured acrylic resin blocks from 1 mm below the cemento-enamel junction (17).

Root Canal Filling

Root canals were filled with, Metapex® (Meta Biomed Co., Ltd, Korea), a commercially available iodoform-calcium hydroxide paste. Specimens were randomly divided into five groups (n=10) according to sealer application method, as follows:

Group 1 (control): Prepared canals were filled with paste using the Metapex® syringe. The procedure was repeated at least twice until back fill was observed in the orifice.

Group 2: Prepared canals were filled with paste using the Metapex® syringe and EndoActivator® (Dentsply Tulsa Dental Specialties, Tulsa, OK, USA). The Metapex® syringe was placed in the canal, and the paste was injected. The EndoActivator® tip (25/04) was then inserted into the canal 2 mm short of working length, and the paste was spread for 1 s using the EndoActivator handpiece set at 10.000 cycles/min. The procedure was repeated at least twice until back fill was observed in the orifice.

Group 3: Prepared canals were filled with paste using the Metapex® syringe and indirect ultrasonic activation. The Metapex® syringe was placed in the canal, and the paste was injected. During injection, an ultrasonic diamond tip (Suprasson® P-Max, Satelec Acteon Group, France) was placed in contact with the Metapex® syringe for 1 second. The procedure was repeated at least twice until back fill was observed in the orifice.

Group 4: Prepared canals were filled with Metapex® paste using an endodontic irrigation needle (KerrHawe SA, Bioggio, Switzerland). The sealer was transferred into a local anesthetic syringe cartridge, and the paste was placed in the canal using a 30-gauge endodontic needle. The procedure was repeated at least twice until back fill was observed in the orifice.

Group 5: Prepared canals were filled with Metapex® paste using a lentulo spiral (Size 30) mounted in a low-speed handpiece (W&H Company, Bürmoos, Austria). The lentulo spiral was inserted

into the canal, rotated in a clockwise direction and withdrawn gently from the canal while still rotating. The procedure was repeated at least twice until the canal orifice appeared filled with paste.

For all groups, a rubber stop was placed around the filling instrument 1 mm short of the working length, and when the canal was assumed to be completely filled, a wet cotton pellet was used to lightly tamp the material into the canal.

Radiographic Evaluation

Digital radiographs of the root canals were taken in the buccolingual direction using a paralleling technique with both receptor and tooth aligned in the same direction. Photo stimulated phosphor radiographs were exposed with a dental X-ray unit (Evostyle NG, New life radiology, Torino, Italia) at 60 kVp, 6 mA for 0.25 seconds with a target-film distance of 15 mm. Digital images were recorded as TIFF files and evaluated on a 19-inch monitor set at a 32-bit resolution in a darkened room using the ImageJ software analysis program. Root canals were assessed by two blinded, calibrated observers. Length of fill was scored as follows: 1=Underfilled: less than or equal to half the root-canal length filled; 2=Sub-optimal filling: more than half the root-canal length filled but filling less than optimal; 3=Optimal filling: canal filled to the radiographic apex or up to 1.5 mm short of the apex; 4=Overfilling: filling material extended beyond the root apex (Figure 1a-d). Quality of filling was evaluated based on the presence, localization, and total amount (%) of voids. The number of voids in each third of the root canal (coronal, middle, apical) was also calculated.

Statistical Analysis

Statistical analysis was performed using Kruskal-Wallis and Bonferroni-corrected Mann-Whitney U tests, with the level of significance set at $p < 0.05$.

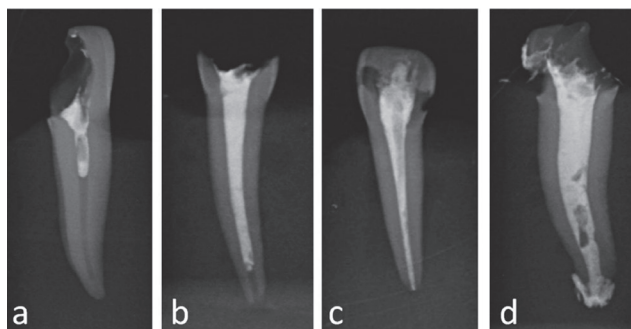


Figure 1 (a-d). Scores for root filling in all groups

Results

Figure 2 shows the frequencies of each root filling score by group. The groups were rank in order according to acceptable scores (score 2 and 3) as group 3 > group1 > group5 > group 2 > group 4. For acceptable filling scores no statistically significant differences were observed between the test methods accept group 4 ($p<0.05$).

Voids were detected in all groups. The sum of voids (%) was highest in group 4 (55.75%), followed by group 3 (16.6%), group 2 (13.3%), group 5 (11.9%) and group 1 (6.94%). The difference between group 4 and the other groups was statistically significant ($p<0.05$); however, the differences among the remaining groups were not statistically significant ($p>0.05$).

Figure 3 shows the distribution of voids in each third of the root canal (coronal, middle, apical). It was observed that the voids were localized generally the coronal and the middle thirds of the canals for all tested methods.

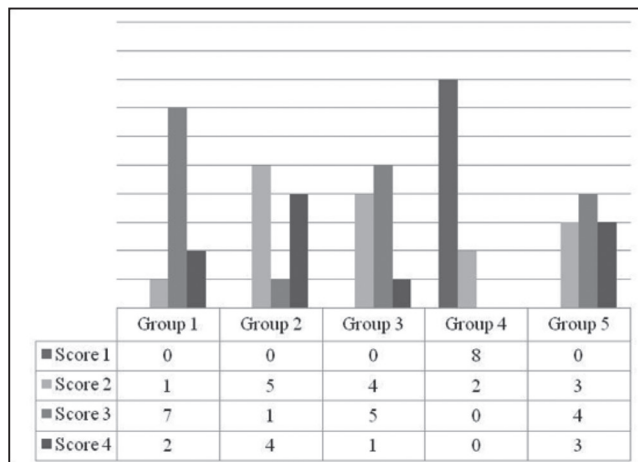


Figure 2. Frequency distribution of each score in all experimental groups

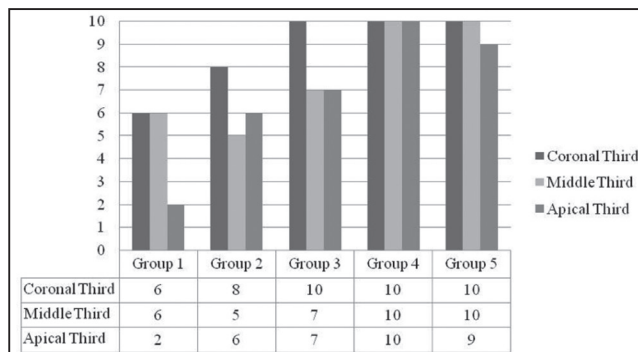


Figure 3. Frequency distribution of voids in all experimental groups

Discussion

Conventional primary root-canal filling essentially involves placing filling material into the pulp chamber using a plastic instrument or lentulo and packing it into the canal with a root canal plugger or lentulo, followed by a cotton pellet (18). Despite the apparent simplicity of the technique, it remains difficult to master. Air entrapment can cause underfilling, voids and failure to create a hermetic seal, resulting in ultimate failure. Conversely, uncontrolled, excessive pressure can cause overfilling (19). Different root canal sealer systems have been introduced to overcome these disadvantages. While these systems all use their own syringes to obturate root canals with light pressure (20), according to the literature, they share a common defect: overfilling.

Despite numerous studies evaluating and comparing success rates of different techniques used to fill primary-teeth root canals (4,17,21), none of the techniques described consistently provide optimal results. Therefore, the present study examined several new endodontic technologies, including EndoActivator® and a new endodontic needle, in terms of performance in primary teeth root canal obturation.

Root filling quality can be assessed by a variety of techniques, including radioisotopes, dyepenetration, fluidfiltration, bacterialleakage, microscopicanalysis, radiographic examination and clearing techniques (22-24). This study evaluated filled root canals using photo stimulated phosphor radiographs, which have been shown to perform better than conventional radiographic techniques in detecting small voids compared (24).

Determination of working length is one of the most important steps in primary teeth pulpectomy treatment due to continuing resorption. Because the apical foramen may not correspond to the anatomic root apex, but may be coronal to it, as the course of resorption progresses, it is advisable to maintain a working length 2-3 mm short of the radiographic working length in order to prevent overextension through the apical foramen, especially in teeth exhibiting signs of apical root resorption. In the present study, the length of the filling was assumed as acceptable when the score 2 and score 3 was observed.

Various endodontic irrigation needles have been developed to improve the effectiveness of root canal irrigation, and it was hypothesized that the characteristic side openings would enable these needles to perform better in filling the full diameter of the root canal. However, the study findings showed the specimens filled using an endodontic irrigation needle (group 4) were the least adequately filled in terms of both filling length and percentage of voids. This may be due to the small gauge of the needle, which is incompatible with the relatively stiff Metapex® paste. Needle displacement during injection could also have affected the results.

Recently, ultrasound technology has regained its popularity as a tool in dentistry. One study used indirect ultrasound to improve the compaction of glass ionomer cement, and another study using direct ultrasound to agitate root canal during irrigation also found it helped in the compaction of root-end filling material (25,26). In the present study, ultrasonic and sonic support groups (groups 2 and 3) showed similar acceptable scores to the Metapex® syringe alone for the length and the quality of primary teeth root canal fillings.

The lentulo spiral has been and continues to be the instrument most commonly used as a root-canal paste carrier (14). However, lentulo instruments suffer from difficulties in terms of fitting the rubber stop, instrument fracture, and a tendency towards extrusion beyond the apex (4,27). The extrusion of the filling material and the high percentage of voids observed with the lentulo spiral is in line with the findings of previous studies (14,17).

The survival of root canal treatment is affected by voids (28), the presence of which encourage the possibility of microorganism and toxin retention that may be associated with post-treatment disease (29). In clinical practice, the number, location and size of voids depends upon the material and technique used to fill the root canal as well as the skill of the operator (30). Voids located in the apical and middle third of the root have been shown to greatly affect the survival time of root canal treatment of permanent teeth; however, void location is less important in primary teeth due to their large apexes (31). In the present study, all groups, including the control group, showed similar results in terms of amounts and locations of voids.

Power Analysis

For 5 study groups to be evaluated at the study capitals, the number of patients required to take each group with 80% power was calculated as 10. In the calculations; Joe Rebellato et al. (32), 1997 "Lower arch perimeter preservation using the lingual arch" named study was taken as reference.

[t-tests - means: Difference between two independent means (two groups)]

Analysis:

A priori: Compute required sample size

Input: Tail(s)=One

Effect size $d=0.9262547$

α err prob=0.05

Power (1- β err prob)=0.90

Allocation ratio $N2/N1=1$

Output: Noncentrality parameter $\delta=3.0014083$

Critical $t=1.6838510$

Sample size groups=7

Total sample size=35

Actual power=0.9040840]

Conclusion

Within the limitations of the present study apart from the endodontic irrigation needle group, all of the tested methods could be used for obturation of primary teeth but not perfect and so new technologies and techniques are needed to improve primary root canal fillings.

Ethics

Ethics Committee Approval: The study was approved by the Ondokuz Mayıs University Human Research and Ethics Committee (approval no: 2014/682).

Informed Consent: Consent form was filled out by all participants.

Peer-review: Externally and internally peer-reviewed.

Authorship Contributions

Surgical and Medical Practices: E.K., B.G., S.Ö., Concept: E.Ş.T., E.K., S.Ö., Design: E.Ş.T., E.K., Data Collection or Processing: S.Ö., E.K., Analysis or Interpretation: E.K., S.Ö., Literature Search: E.Ş.T., E.K., S.Ö., Writing: E.Ş.T., S.Ö.

Conflict of Interest: No conflict of interest was declared by the authors.

Financial Disclosure: The authors declared that this study received no financial support.

References

1. Thomas AM, Chandra S, Chandra S, Pandey RK. Elimination of infection in pulpectomized deciduous teeth: a short-term study using iodoform paste. *J Endod* 1994; 20: 233-5.
2. Pinkham JR, Casamassimo PS, Mctigue DJ, Fields HW, Nowak AJ. *Pediatric Dentistry: Infancy Through Adolescence*. 4th ed. Philadelphia; Pa: WB Saunders Co; 2005; pp. 375-90.
3. Cohen S, Hargreaves K. *Pediatric Endodontics: Endodontic treatment for the primary and young permanent dentition. Pathways of pulp*. 8th edition; 2002; pp. 893-5.
4. Bawazir OA, Salama FS. Clinical evaluation of root canal obturation methods in primary teeth. *Pediatr Dent* 2006; 28: 39-47.
5. Ozalp N, Saroğlu I, Sönmez H. Evaluation of various root canal filling materials in primary molar pulpectomies: an in vivo study. *Am J Dent* 2005; 18: 347-50.
6. Nurko C, Garcia-Godoy F. Evaluation of a calcium hydroxide/iodoform paste (Vitapex) in root canal therapy for primary teeth. *J Clin Pediatr Dent* 1999; 23: 289-94.
7. Sridhar N, Tandon S. Continued root-end growth and apexification using a calcium hydroxide and iodoform paste (Metapex®): three case reports. *J Contemp Dent Pract* 2010; 11: 63-70.
8. Kahn FH, Rosenberg PA, Schertzer L, Korthals G, Nguyen PN. An in-vitro evaluation of sealer placement methods. *Int Endod J* 1997; 30: 181-6.
9. Guelmann M, McEachern M, Turner C. Pulpectomies in primary incisors using three delivery systems: an in vitro study. *Clin Pediatr Dent* 2004; 28: 323-6.
10. Dandashi MB, Nazif MM, Zullo T, Elliott MA, Schneider LG, Czonstkowsky M. An in vitro comparison of three endodontic techniques for primary incisors. *Pediatr Dent* 1993; 15: 254-6.
11. Bagis B, Turkaslan S, Vallittu PK, Lassila LV. Effect of high frequency ultrasonic agitation on the bond strength of self-etching adhesives. *J Adhes Dent* 2009; 11: 369-74.
12. Shahid S, Billington RW, Hill RG, Pearson GJ. The effect of ultrasound on the setting reaction of zinc polycarboxylate cements. *J Mater Sci Mater Med* 2010; 21: 2901-5.
13. Plotino G, Pameijer CH, Grande NM, Somma F. Ultrasonics in endodontics: a review of the literature. *J Endod* 2007; 33: 81-95.
14. Grover R, Mehra M, Pandit IK, Srivastava N, Gugnani N, Gupta M. Clinical efficacy of various root canal obturating methods in primary teeth: a comparative study. *Eur J Paediatr Dent* 2013; 14: 104-8.
15. Schneider SW. A comparison of canal preparations in straight and curved root canals. *Oral Surg Oral Med Oral Pathol* 1971; 32: 271-5.
16. Shantiaee Y, Maziar F, Dianat O, Mahjour F. Comparing microleakage in root canals obturated with nanosilver coated gutta-percha to standard gutta-percha by two different methods. *Iran Endod J* 2011; 6: 140-5.
17. Memarpour M, Shahidi S, Meshki R. Comparison of different obturation techniques for primary molars by digital radiography. *Pediatr Dent* 2013; 35: 236-40.
18. Payne RG, Kenny DJ, Johnston DH, Judd PL. Two-year outcome study of zinc oxide-eugenol root canal treatment for vital primary teeth. *J Can Dent Assoc* 1993; 59: 528-30, 533-6.
19. Subba Reddy VV, Shakunthala B. Comparative assessment of three obturating techniques in primary molars: An in-vivo study. *Endodontology* 1997; 9: 13-6.
20. Gupta S, Das G. Clinical and radiographic evaluation of zinc oxide eugenol and metapex in root canal treatment of primary teeth. *J Indian Soc Pedod Prev Dent* 2011; 29: 222-8.
21. Bhandari SK, Anita, Prajapati U. Root canal obturation of primary teeth: disposable injection technique. *J Indian Soc Pedod Prev Dent* 2012; 30: 13-8.
22. Hammad M, Qualtrough A, Silikas N. Evaluation of root canal obturation: a three-dimensional in vitro study. *J Endod* 2009; 35: 541-4.
23. Ozawa T, Taha N, Messer HH. A comparison of techniques for obturating oval-shaped root canals. *Dent Mater J* 2009; 28: 290-4.
24. Huybrechts B, Bud M, Bergmans L, Lambrechts P, Jacobs R. Void detection in root fillings using intraoral analogue, intraoral digital and cone beam CT images. *Int Endod J* 2009; 42: 675-85.
25. Bernabé PF, Gomes-Filho JE, Bernabé DG, Nery MJ, Otoboni-Filho JA, Dezan E Jr, et al. Sealing ability of MTA used as a root end filling material: effect of the sonic and ultrasonic condensation. *Braz Dent J* 2013; 24: 107-10.
26. Gorseta K, Glavina D, Skrinjaric I. Influence of ultrasonic excitation and heat application on the microleakage of glass ionomer cements. *Aust Dent J* 2012; 57: 453-7.
27. Kahn FH, Rosenberg PA, Schertzer L, Korthals G, Nguyen PN. An in-vitro evaluation of sealer placement methods. *Int Endod J* 1997; 30: 181-6.
28. Aghdasi MM, Asnaashari M, Aliari A, Fahimipour F, Soheilifar S. Conventional versus digital radiographs in detecting artificial voids in root canal filling material. *Iran Endod J* 2011; 6: 99-102.
29. Nguyen NT. Obturation of the root canal system. In: Cohen S, Burns RC, eds. *Pathways of the Pulp*, 6th edn. St Louis, USA: Mosby, 1994; pp. 219-71.
30. Kositbowornchai S, Hanwachirapong D, Somsopon R, Pirmsinthavee S, Sooksuntisakoonchai N. Ex vivo comparison of digital images with conventional radiographs for detection of simulated voids in root canal filling material. *Int Endod J* 2006; 39: 287-92.
31. Cheung GS. Survival of first-time nonsurgical root canal treatment performed in a dental teaching hospital. *Oral Surg Oral Med Oral Pathol Oral Radiol Endod* 2002; 93: 596-604.
32. Rebellato J, Lindauer SJ, Rubenstein LK, Isaacson RJ, Davidovitch M, Vroom K. Lower arch perimeter preservation using the lingual arch. *Am J Orthod Dentofacial Orthop*. 1997; 112: 449-56.