

# Biostimulatory Effects of Diode Laser and Ozone on Wound Healing in Rats

## *Ratlarda Yara İyileşmesinde Ozon ve Diod Lazerin Biyostimülatör Etkisi*

✉ Hilal Alan<sup>1</sup>, ✉ Çiğdem Güler<sup>2</sup>, ✉ Ümit Yolcu<sup>1</sup>, ✉ Mahmut Koparal<sup>3</sup>, ✉ Ebru Çakır<sup>4</sup>, ✉ Pınar Demir<sup>5</sup>

<sup>1</sup>İnönü University Faculty of Dentistry, Department of Oral and Maxillofacial Surgery, Malatya, Turkey

<sup>2</sup>Ordu University Faculty of Dentistry, Department of Pediatric Dentistry, Ordu, Turkey

<sup>3</sup>Adıyaman University Faculty of Dentistry, Department of Oral and Maxillofacial Surgery, Adıyaman, Turkey

<sup>4</sup>University of Health Sciences, İzmir Tepecik Training and Research Hospital, Clinic of Pathology, İzmir, Turkey

<sup>5</sup>İnönü University Faculty of Dentistry, Department of Pediatric Dentistry, Malatya, Turkey



### Keywords

Ozone, diode laser, wound healing, rat, therapy, soft tissue

### Anahtar Kelimeler

Ozon, diod lazer, yara iyileşmesi, rat, yumuşak doku tedavisi

Received/Geliş Tarihi : 13.06.2017

Accepted/Kabul Tarihi : 02.11.2017

doi:10.4274/meandros.97269

### Address for Correspondence/Yazışma Adresi:

Çiğdem Güler, PhD, DDS,  
Ordu University Faculty of Dentistry,  
Department of Pediatric Dentistry, Ordu,  
Turkey  
Phone : +90 452 212 1286  
E-mail : cigdem\_zehir@yahoo.com  
ORCID ID: orcid.org/0000-0002-2581-9050

©Meandros Medical and Dental Journal, Published by Galenos Publishing House.  
This is article distributed under the terms of the Creative Commons Attribution NonCommercial 4.0 International Licence (CC BY-NC 4.0).

### Abstract

**Objective:** Diode laser and ozone can be used to healing of skin wounds. The aim of this study is to evaluate the biostimulatory effects of diode laser and ozone on the healing of sutured skin wounds in rats.

**Materials and Methods:** In this study, 21 adult males Wistar albino rats were used. Three 1-cm-longs, full-thickness incisions were applied to the back of each animal and closed with sutures. Diode laser treatment, irrigation with 0.9% saline solution and ozone therapy was applied to the wounds through 7 days. Animals were euthanized on the 3<sup>rd</sup>, 7<sup>th</sup>, and 14<sup>th</sup> days after treatment, and all wounds were surgically removed for histopathological evaluation.

**Results:** According to histological results, a statistically significant difference was found among the three treatment methods in acute inflammatory reactions on 3<sup>rd</sup> day ( $p<0.05$ ). Ozone treatment reduced the intensity of acute inflammatory reactions by the 3<sup>rd</sup> day ( $p<0.05$ ). In addition, a statistically significant difference was found between the follow-up periods in all treatment groups for fibrosis ( $p<0.01$ ).

**Conclusion:** It was found that ozone treatment was more effective when compared to the other treatments for reducing the intensity of acute inflammatory reactions on the healing of sutured skin wounds.

### Öz

**Amaç:** Diod lazer ve ozon deri yaralarının iyileşmesinde kullanılan yöntemlerdendir. Bu çalışmanın amacı sütüre edilmiş deri yarasında diod lazer ve ozonun biyostimülatör etkisinin değerlendirilmesidir.

**Gereç ve Yöntemler:** Bu çalışmada; 21 erkek Wistar albino rat kullanılmıştır. Hayvanların sırtına üç adet 1 cm uzunluğunda tam kalınlıkta insizyon yapıldı ve sütüre edildi. Yaralara 7 gün diod lazer tedavisi, %0,9 salin solüsyonla irrigasyon ve ozon tedavisi uygulandı. Hayvanlar tedaviden sonra 3., 7. ve 14. günlerde sakrifiye edildi ve histopatolojik değerlendirme için yara bölgesi cerrahi olarak çıkarıldı.

**Bulgular:** Histolojik sonuçlara göre, 3. günde akut enflamatuvar reaksiyon açısından üç tedavi yöntemi arasında istatistiksel olarak anlamlı farklılık vardır ( $p<0,05$ ). Ozon tedavisi akut enflamasyon yoğunluğunu 3. günde düşürmüştür ( $p<0,05$ ). Ayrıca, takip periyoitlerinde bütün tedavi gruplarında fibroziste istatistiksel olarak anlamlı fark bulunmuştur ( $p<0,01$ ).

**Sonuç:** Sütüre edilmiş deri yarasının iyileşmesinde akut enflamatuvar reaksiyonun azalmasında diğer tedavilerle karşılaştırıldığında ozon tedavisinin daha etkili olduğu bulunmuştur.

## Introduction

Wound healing is one of the most challenging difficulties in today's medical issues especially in surgery field. Several methods have been recommended for acceleration of wound-healing over decades. Chemical materials, electro-stimulation of wound, low-level laser therapy (LLLT), negative pressure wound therapy and also ozone ( $O_3$ ) are among these methods (1).

The healing of soft tissue wounds is an extremely organized process (2). The healing process includes phases such as inflammatory cell immigration, granulation tissue synthesis, collagen and proteoglycan deposition, and scar maturation (3).

Different kinds of lasers can be used in dentistry for cavity preparation, soft-tissue surgery, caries prevention, caries diagnosis, and endodontic treatment. The laser therapy is one of the techniques used to accelerate the improvement of soft tissue functionality in the management of injured soft tissue. Lasers are recommended for the healing process of skin incisions due to the healing of the tissue by causing collagen synthesis and vessel dilatation, and by rising tissue oxygenation (4). Enwemeka et al. (5) reported that laser treatments positively impact all stages of the healing period. The wavelength and energy density of the laser are crucial factors in successful treatment (6). Several kinds of laser have been tried in order to improve the quality of healing of soft tissue wounds (7). Diode lasers have been used in dentistry for numerous indications, such as periodontics, endodontics, bleaching, or LLLT (8). The biostimulatory effects of LLLT on the healing process of tissues have attracted considerable attention. Various researches have studied the effect of LLLT on the normal and damaged wound healing process in clinical and experimental. The generality of researchers stated enhanced blood vessel endothelium enhanced, wound closure, enhanced tensile strength, increased fibroblasts, induction of collagen synthesis, and reduced inflammatory reaction (9). However, there has been little training on the effects of LLLT on the healing of sutured skin wounds (10).

$O_3$  is generally accepted as one of the best antifungal, bactericidal, and antiviral agents (11). Therefore, it is empirically used as a clinical therapeutic agent for chronic wounds (12).

It has been systematically shown that LLLT is able to modify the morphology of scar tissue in soft tissue wounds because of its positive effect on the proliferation and differentiation of fibroblasts, synthesis of collagen, and neoangiogenesis, and the positive impacts of  $O_3$  on wound healing could be supposed to be owing to reduced bacterial infection, amelioration of decreased cutaneous wound healing, or enlarged oxygen tension by  $O_3$  exposure in the wound area (13). However, a comparison of the effects of  $O_3$  and LLLT on the healing of sutured skin wounds has not been studied yet.

The aim of this study was to evaluate and compare the impact of diode laser and  $O_3$  on the healing of sutured skin wounds in rats. The null hypothesis was that there would be differences in the healing process of sutured skin wounds treated with diode laser or  $O_3$  in rats.

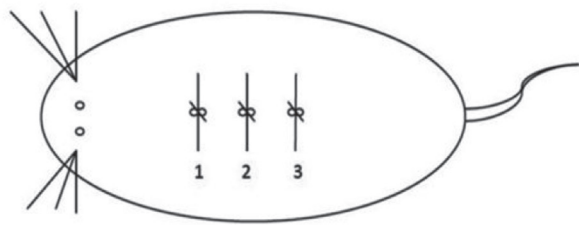
## Materials and Methods

İnönü University's Experimental Animal Ethics Committee (protocol no: 2013/A-14) approved to this study's experimental procedures.

Twenty-one adult males Wistar albino rats with an average weight of 270-300 g and age of 3-5 months were used in this study. All of the subjects were kept in a room with a cycle of twelve hours of light and twelve hours of dark. Temperature of the room was 21 °C and the rats were fed ad libitum. All trial processes followed the guidelines of the Animal Care and Use Committee of the İnönü University Faculty of Medicine's Experimental Animal Center.

The experiment was designed with 21 rats. Three 1-cm-long, full-thickness incisions were applied to the back of each animal. The three incisions on each rat were closed with sutures (Figure 1) (14).

LLLT with diode laser was then applied to the first wound every day after surgery through 7 day (laser group). The second wound was irrigated with 0.9% saline solution (control group).  $O_3$  therapy was



**Figure 1.** Three 1-cm-long, full-thickness incisions were applied to the back of each rat. For suturing, a single knot was made in the middle of the incision. 1: low-level laser therapy with diode laser (laser group), 2: 0.9% saline solution (control group), 3: ozone (ozone group)

applied to the third wound after surgery through 7 day ( $O_3$  group). Seven of the animals were sacrificed after 3 days, 7 were sacrificed after 7 days, and 7 were sacrificed after 14 days. Amoxicillin were injected to all rats intramuscularly (50 mg/kg) for 4 days every 24 hours, starting one day before the surgery and after the operation they were injected an intramuscular analgesic every 24 hours through 3 days. All operations were achieved paying attention to sterilization. Anesthesia was carried out with 2% xylazine (0.1 mL/100 g) and 10% ketamine (0.1 mL/100 g). After general anesthesia, the dorsal skin of the rats was shaved and the cutaneous surface was disinfected before the surgery. Three 1-cm-long incisions were made using a scalpel. After the treatment procedure, the wounds were sutured with absorbable 3-0 polyglactin 910 sutures (Vicryl; Ethicon, Somerville, NJ, USA).

The LLLT (CHEESE Dental Laser System, DEN4A) procedure was started following surgery on the first sutured wound of each rat through 7 days, for 90 seconds with continuous output with a potency of 0.3 W and wavelength of 810 nm. The laser array was placed directly over the animal at a vertical distance of 1 cm from the wound. The second sutured wound was not treated and served as a control, only irrigated with 0.9% saline solution.

The  $O_3$  application device was a portable  $O_3$  delivery system (OzoneDTA generator, APOZA, Taiwan).  $O_3$  was applied to the third sutured wound of each rat through 7 days according to the manufacturer's instructions. During  $O_3$  therapy, oxygen was converted on the surface of the sutured skin wound.  $O_3$  devices were used for 90 seconds with a 3 number flat probe and output power of 12 for sutured wound disinfection.

Seven animals were sacrificed with an overdose of general anesthesia on 3<sup>rd</sup> day, 7<sup>th</sup> day, or 14<sup>th</sup> day after surgery. Tissue specimens were fixed in 10% neutral-buffered formalin, and 3 samples including the incisions were obtained for histologic examination. The samples were embedded in paraffin blocks. Sections measuring 5  $\mu$ m were stained with hematoxylin and eosin for histopathologic evaluation. For each specimen, acute inflammation, chronic inflammation, granulation tissue, ulcer, fibrosis, crust, and hyperkeratosis were assessed. The severity of acute and chronic inflammation, fibrosis, and granulation tissue were scored with a grade of 0 to 3 as follows: 0, none; 1, mild; 2, moderate; and 3, severe. Crust, ulcer, and hyperkeratosis were assessed as present or absent.

### Statistical Analysis

Statistical analysis of the data was performed using SPSS version 22.0 (IBM SPSS, Turkey). The Kruskal-Wallis test was applied to compare between the groups for assessment of acute inflammation, chronic inflammation, fibrosis, and granulation tissue. The Bonferroni correction and the Mann-Whitney U test were applied for the determination of the group's differences. Fisher, Freeman-Halton, and chi-square tests were applied to compare between the groups for assessment of crust, ulcer and hyperkeratosis, a significance level of  $p < 0.05$  was chosen.

### Results

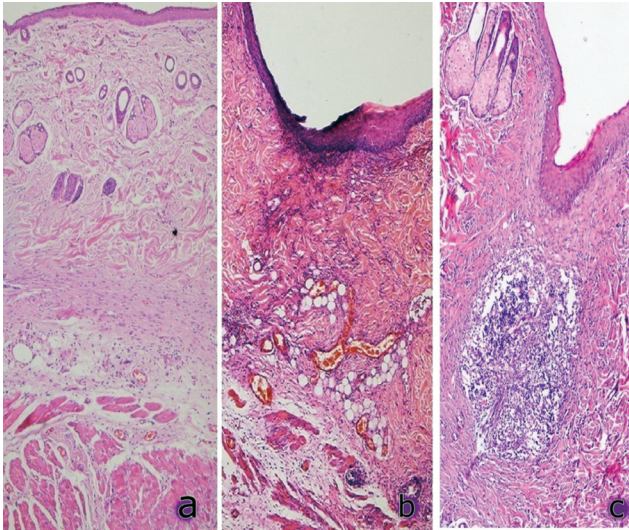
There was no statistically significant difference among the treatment groups for chronic inflammation, fibrosis, and granulation tissue. There was a statistically significant difference between the treatment groups on 3<sup>rd</sup> day for acute inflammation. In the  $O_3$  group, acute inflammation on 3<sup>rd</sup> day was lower than in the other treatment groups ( $p < 0.017$ ). Histological views of acute inflammatory reactions on 3<sup>rd</sup> day for the three treatment methods are shown in Figure 2.

Although there was no statistically significant difference among the treatment groups for fibrosis, there was a greater amount of fibrosis in the  $O_3$  group on 14<sup>th</sup> day and the differences between the follow-up periods in all treatment groups were statistically significant on 7<sup>th</sup> day and 14<sup>th</sup> day (Table 1).

Histological views of fibrosis on 7<sup>th</sup> day for the three treatment methods are shown in Figure 3.

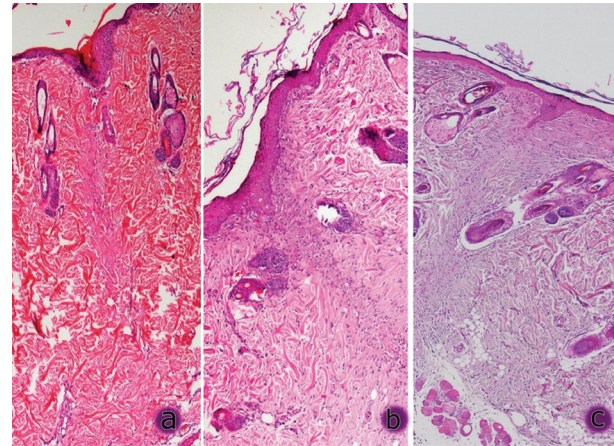


The lowest chronic inflammation rate was in the O<sub>3</sub> group on 7<sup>th</sup> day and in the laser group on 14<sup>th</sup> day, but there was no statistically significant difference.



**Figure 2.** Acute inflammation at 3<sup>rd</sup> day; a: ozone group, b: laser group, c: control group

Granulation tissue was lower in the O<sub>3</sub> group than in the laser group on 3<sup>rd</sup> and 7<sup>th</sup> day but was higher on 14<sup>th</sup> day. Crust formation and ulceration was higher in the O<sub>3</sub> group than in the other groups on 3<sup>rd</sup> and 7<sup>th</sup> days but this difference was not statistically significant (Table 2).



**Figure 3.** Fibrosis at 7<sup>th</sup> day; a: ozone group, b: laser group, c: control group

**Table 1. Distribution of acute inflammation, chronic inflammation, fibrosis and granulation tissue according to groups**

		Control	Ozone	Laser	p
		Mean ± SD (Median)	Mean ± SD (Median)	Mean ± SD (Median)	
Acute inflammation	Day 3	2.2±0.84 (2) <sup>a</sup>	1.0±0 (1) <sup>b</sup>	1.4±0.55 (1) <sup>ab</sup>	<b>0.034*</b>
	Day 7	2.2±1.1 (3)	1.0±0 (1)	1.0±0.71 (1)	<b>0.089</b>
	Day 14	<b>0.6±0.55 (1)</b>	<b>2.0±1.0 (2)</b>	1.0±1.0 (1)	<b>0.097</b>
	p	0.030*	0.031*	0.649	
Chronic inflammation	Day 3	1.8±0.45 (2)	1.6±0.55 (2)	1.6±0.55 (2)	<b>0.756</b>
	Day 7	2.2±0.84 (2)	1.4±0.55 (1)	1.6±0.55 (2)	<b>0.217</b>
	Day 14	1.8±0.45 (2)	2.0±0.71 (2)	1.2±0.84 (1)	0.226
	p	0.502	0.330	0.627	
Fibrosis	Day 3	0±0 (0)	0±0 (0)	0±0 (0)	<b>1.000</b>
	Day 7	<b>1.4±0.55 (1)</b>	<b>1.8±0.45 (2)</b>	<b>1.8±0.45 (2)</b>	0.326
	Day 14	2.0±1.0 (2)	2.4±0.55 (2)	2.2±0.84 (2)	0.792
	p	0.005**	0.003**	0.005**	
Granulation tissue	Day 3	0.8±0.45 (1)	1±0.71 (1)	1.6±0.55 (2)	<b>0.111</b>
	Day 7	1.2±0.45 (1)	1.4±0.55 (1)	1.8±0.84 (2)	<b>0.378</b>
	Day 14	0.8±0.45 (1)	1.8±0.45 (2)	1.6±1.14 (2)	<b>0.085</b>
	p	0.288	0.141	0.941	

\*p<0.05, \*\*p<0.01, SD: Standard deviation

<sup>a,b</sup>Different superscripts represent the difference between the groups at each line (Kruskal-Wallis test)

Bold characters in each column represent the differences between the measurement periods in the relevant working groups (Bonferroni correction and Mann-Whitney U test)

**Table 2. Distribution of hyperkeratosis, crust and ulcer according to groups**

n (%)		Control	Ozone	Laser	p
		n (%)	n (%)		
Hyperkeratosis	Day 3	4 (80%)	4 (80%)	2 (40%)	0.500
	Day 7	2 (40%)	3 (60%)	3 (60%)	1.000
	Day 14	0 (0%)	2 (40%)	2 (40%)	0.451
	p	0.036*	0.800	1.000	
Crust	Day 3	4 (80%)	5 (100%)	4 (80%)	1.000
	Day 7	0 (0%)	4 (80%)	2 (40%)	0.036*
	Day 14	1 (20%)	0 (0%)	0 (0%)	1.000
	p	0.020*	0.006**	0.036*	
Ulcer	Day 3	2 (40%)	3 (60%)	1 (20%)	0.800
	Day 7	0 (0%)	2 (40%)	1 (20%)	0.725
	Day 14	0 (0%)	0 (0%)	0 (0%)	-
	p	0.286	0.251	1.000	

\*p<0.05, \*\*p<0.01, Fisher, Freeman-Halton, and chi-square tests

## Discussion

In this study, the effects of diode laser and O<sub>3</sub> on wound healing in rats were histopathologically evaluated. O<sub>3</sub> treatment was the more-effective treatment when compared to LLLT for reducing the intensity of acute inflammatory reactions on 3<sup>rd</sup> day. However, the effects of diode laser and O<sub>3</sub> on skin wound healing were found to be similar over 14 days.

Wound healing is a natural reaction to tissue damage. Specific cells move into the wound area for this extremely organized healing process, to provide the main signaling actions that are compulsory for a new blood supply and the arrival of connective tissue cells (15). Wound healing involves inflammation, tissue formation, and tissue remodeling phases and begins with acute inflammation during which increased vascular permeability and vasodilatation occurs (14,16). Although its long-term continuity is regarded as one of the most significant reasons for delays in the healing process, this inflammation is certainly obligatory to provide wound healing (10). Throughout the inflammatory phase, macrophages, platelets, lymphocytes, and neutrophils migrate to the wound area. The acute-phase reactants decrease and the macrophages and fibroblasts proliferate during the proliferative phase. Lastly, throughout the remodeling phase, fibroblasts support and restructure the deposited collagen and the extracellular matrix (17).

Mester et al. (18) introduced LLLT for therapeutic application. Subsequently, numerous studies have shown that LLLT is helpful in regulating various biological events, for example analgesic, anti-inflammatory, and trophic regenerative effects (15). However, some investigators have reported that LLLT has not shown positive effects on wound healing and that it could even have antagonistic effects on this process (19,20). The positive effects of appropriate treatment protocols for LLLT on wound healing may be explained by its ability to stimulate certain biological reactions responsible for activating several phases of soft-tissue healing, such as induction of cytokines and expression of growth factors. In contrast, when LLLT has been used with inappropriate treatment protocols, the healing process may result in negative responses because of an inappropriate interaction between laser light and tissue components (15).

At this time, there is no universal agreement regarding how LLLT affects wound healing. The energy emitted by LLLT has shown healing, anti-inflammatory, and analgesic properties, and it has been extensively used in the process of wound healing because its wavelength and the low densities of energy can penetrate tissues (21).

Clinically, LLLT has been used to stimulate the healing of different varieties of wounds, such as open skin wounds, soft-tissue injuries, tendinitis, acne, and psoriasis (14). LLLT affects the inflammatory reaction

in the early days after injury, with enhancement of the amount of mast cells and polymorphonuclear neutrophils, enlargement of blood vessels, and vasodilatation; in this way, the inflammatory process accelerates and the healing of the wound occurs more quickly (16). The influence of LLLT depends on numerous factors, including spot size, wavelength, repetition rate, total treatment time, and power (22). The optimal parameters for LLLT are still not defined. In the literature, daily exposure of LLLT is recommended, which is predicted to provide more noticeable effects than single or weekly treatments (23). Therefore, we applied LLLT daily.

There have been conflicting results regarding the appropriate energy density of LLLT. Although Kana et al. (24) reported that 4 J/cm<sup>2</sup> is the optimum energy density of LLLT, Meirelles et al. (25) reported that LLLT with 20 J/cm<sup>2</sup> energy density improved collagen maturation on the 21<sup>st</sup> day. It has been suggested that LLLT stimulates proliferation with low doses such as 2 J/cm<sup>2</sup>, while high doses of LLLT such as 16 J/cm<sup>2</sup> are suppressive (23). Mendez et al. (26) showed that the gallium-aluminium-arsenide laser ( $\lambda$  830 nm) at 50 J/cm<sup>2</sup> stimulated intense collagen maturation in soft-tissue wounds in rats. However, Gonçalves et al. (27) recommended that the highest energy density (90 J/cm<sup>2</sup>) demonstrated positive effects on the healing process. These contradictory results are likely due to limitations in the experimental models and variations in treatment factors, the absence of control groups, and lack of comparison to heterogeneous clinical wounds, and limited or no blinding of researchers (28).

Although it has previously been suggested that LLLT has possible systemic effects, in several earlier studies in which experimental and control conditions were applied on the same animal, it was observed that LLLT had a significantly positive effect. Therefore, it may be theorized that the main effect of LLLT on soft-tissue wound healing is local. Consequently, the question of systemic effects of LLLT needs more investigation (29).

The medical use of O<sub>3</sub> was initiated in the nineteenth century. O<sub>3</sub> has numerous beneficial effects in soft tissue healing owing to its nascent oxygen release feature, stimulate antioxidant enzymes and have bactericidal capabilities (30). There are numerous known effects of O<sub>3</sub> on the body, for example analgesic, immunostimulating, detoxicating, anti-hypoxic, antimicrobial, biosynthetic, and bioenergetic

effects (31). It has recently been shown that although O<sub>3</sub> does not infiltrate the cells, it responds instantly through polyunsaturated fatty acids to form reactive oxygen species such as hydrogen peroxide, which, via the activation of redox transcription factors such as NF-kappaB, can induce the synthesis of growth factors and accelerate the cell cycle (32). Studies have revealed that O<sub>3</sub> treatments increase the secretion of transforming growth factor- $\beta$ 1, platelet-derived growth factor, and cytokines, such as interleukin-8 (33). Koca et al. (34) showed that oxidative stress and inflammatory cytokines were reduced after both O<sub>3</sub> and hyperbaric oxygen therapies.

Kim et al. (33) proved that O<sub>3</sub> might improve acute cutaneous wound healing. Although they emphasized that topical treatment with O<sub>3</sub> could impact granulation tissue development in the wound healing process instead of affecting the early development of blood clots and improvement of inflammatory cells while the inflammation phase, these results were inconsistent with ours.

Zhang et al. (35) reported that the oxygen-O<sub>3</sub> treatment significantly stimulated the early effective rate of wound healing at day 20 in diabetic foot-ulcer patients. Valacchi et al. (32) demonstrated that a specific level of ozonated sesame oil can accelerate the first stage of wound healing in SKH1 mice. These findings are consistent with our results.

## Conclusion

According to our study, it seems that LLLT and O<sub>3</sub> therapy accelerate wound healing in some phases of the healing process. However, based on the present results, acute inflammatory reactions were statistically reduced in O<sub>3</sub>-treated wound tissues when compared to the LLLT group on 3<sup>rd</sup> day post-incision.

## Ethics

**Ethics Committee Approval:** The experimental protocol was approved by the İnönü University's Experimental Animal Ethics Committee (protocol no: 2013/A-14).

**Informed Consent:** This study was a animal study.

**Peer-review:** Externally peer-reviewed.

## Authorship Contributions

Surgical and Medical Practices: H.A., Ç.G., P.D., Concept: H.A., Ç.G., Ü.Y., M.K., Design: H.A., Ç.G., Ü.Y.,



M.K., Data Collection or Processing: H.A., Ç.G., P.D. Analysis or Interpretation: E.Ç. Literature Search: P.D., M.K., Writing: H.A., C.G., Ü.Y., M.K.

**Financial Disclosure:** Purchasing of chemicals and animals.

**Conflict of Interest:** The authors declare that they have no conflict of interest.

## References

- Hodjati H, Rakei S, Johari HG, Geramizedeh B, Sabet B, Zeraatian S. Low-level laser therapy: an experimental design for wound management: a case-controlled study in rabbit model. *J Cutan Aesthet Surg* 2014; 7: 14-7.
- Meirelles GC, Santos JN, Chagas PO, Moura AP, Pinheiro AL. A comparative study of the effects of laser photobiomodulation on the healing of third-degree burns: a histological study in rats. *Photomed Laser Surg* 2008; 26: 159-66.
- Yu H, Yuan L, Xu M, Zhang Z, Duan H. Sphingosine kinase 1 improves cutaneous wound healing in diabetic rats. *Injury* 2014; 45: 1054-8.
- Ihsan FR. Low-level laser therapy accelerates collateral circulation and enhances microcirculation. *Photomed Laser Surg* 2005; 23: 289-94.
- Enwemeka CS, Parker JC, Dowdy DS, Harkness EE, Sanford LE, Woodruff LD. The efficacy of low-power lasers in tissue repair and pain control: a meta-analysis study. *Photomed Laser Surg* 2004; 22: 323-9.
- Zhang F, Lei MP, Oswald TM, Pang Y, Blain B, Cai ZW, et al. The effect of vascular endothelial growth factor on the healing of ischaemic skin wounds. *Br J Plast Surg* 2003; 56: 334-41.
- Bass LS, Treat MR. Laser tissue welding: a comprehensive review of current and future clinical applications. *Lasers Surg Med* 1995; 17: 315-49.
- Moritz A, Schoop U, Goharkhay K, Schauer P, Doertbudak O, Wernisch J, et al. Treatment of periodontal pockets with a diode laser. *Lasers Surg Med* 1998; 22: 302-11.
- Longo L, Evangelista S, Tinacci G, Sesti AG. Effect of diodes-laser silver arsenide-aluminium (Ga-Al-As) 904 nm on healing of experimental wounds. *Lasers Surg Med* 1987; 7: 444-7.
- Melo VA, Anjos DC, Albuquerque Júnior R, Melo DB, Carvalho FU. Effect of low level laser on sutured wound healing in rats. *Acta Cir Bras* 2011; 26: 129-34.
- Valacchi G, Fortino V, Bocci V. The dual action of ozone on the skin. *Br J Dermatol* 2005; 153: 1096-100.
- Martínez-Sánchez G, Al-Dalain SM, Menéndez S, Re L, Giuliani A, Candelario-Jalil E, et al. Therapeutic efficacy of ozone in patients with diabetic foot. *Eur J Pharmacol* 2005; 523: 151-61.
- Bocci V, Borrelli E, Zanardi I, Travagli V. The usefulness of ozone treatment in spinal pain. *Drug Des Devel Ther* 2015; 9: 2677-85.
- Capon A, Souil E, Gauthier B, Sumian C, Bachelet M, Buys B, et al. Laser assisted skin closure (LASC) by using a 815-nm diode-laser system accelerates and improves wound healing. *Lasers Surg Med* 2001; 28: 168-75.
- Gonzaga Ribeiro MA, Cavalcanti de Albuquerque RL, Santos Barreto AL, Moreno de Oliveira VG, Santos TB, Freitas Dantas CD. Morphological analysis of second-intention wound healing in rats submitted to 16 J/cm<sup>2</sup> 660-nm laser irradiation. *Indian J Dent Res* 2009; 20: 390.
- Oliveira Sampaio SC, de C Monteiro JS, Cangussú MC, Pires Santos GM, dos Santos MA, dos Santos JN, et al. Effect of laser and LED phototherapies on the healing of cutaneous wound on healthy and iron-deficient Wistar rats and their impact on fibroblastic activity during wound healing. *Lasers Med Sci* 2013; 28: 799-806.
- Posten W, Wrone DA, Dover JS, Arndt KA, Silapunt S, Alam M. Low-level laser therapy for wound healing: mechanism and efficacy. *Dermatol Surg* 2005; 31: 334-40.
- Mester E, Spiry T, Szende B, Tota JG. Effect of laser rays on wound healing. *Am J Surg* 1971; 122: 532-5.
- Allendorf JD, Bessler M, Huang J, Kayton ML, Laird D, Nowygrod R, et al. Helium-neon laser irradiation at fluences of 1, 2, and 4 J/cm<sup>2</sup> failed to accelerate wound healing as assessed by both wound contracture rate and tensile strength. *Lasers Surg Med* 1997; 20: 340-5.
- Núñez SC, Nogueira GE, Ribeiro MS, Garcez AS, Lage-Marques JL. He-Ne laser effects on blood microcirculation during wound healing: a method of in vivo study through laser Doppler flowmetry. *Lasers Surg Med* 2004; 35: 363-8.
- Lins RD, Dantas EM, Lucena KC, Catão MH, Granville-Garcia AF, Carvalho Neto LG. Biostimulation effects of low-power laser in the repair process. *An Bras Dermatol* 2010; 85: 849-55.
- Park JJ, Kang KL. Effect of 980-nm GaAlAs diode laser irradiation on healing of extraction sockets in streptozotocin-induced diabetic rats: a pilot study. *Lasers Med Sci* 2012; 27: 223-30.
- Walsh LJ. The current status of low level laser therapy in dentistry. Part 1. Soft tissue applications. *Aust Dent J* 1997; 42: 247-54.
- Kana JS, Hutschenreiter G, Haina D, Waidelich W. Effect of low-power density laser radiation on healing of open skin wounds in rats. *Arch Surg* 1981; 116: 293-6.
- Meirelles GC, Santos JN, Chagas PO, Moura AP, Pinheiro AL. A comparative study of the effects of laser photobiomodulation on the healing of third-degree burns: a histological study in rats. *Photomed Laser Surg* 2008; 26: 159-66.
- Mendez TM, Pinheiro AL, Pacheco MT, Nascimento PM, Ramalho LM. Dose and wavelength of laser light have influence on the repair of cutaneous wounds. *J Clin Laser Med Surg* 2004; 22: 19-25.
- Gonçalves RV, Novaes RD, Cupertino Mdo C, Moraes B, Leite JP, Peluzio Mdo C, et al. Time-dependent effects of low-level laser therapy on the morphology and oxidative response in the skin wound healing in rats. *Lasers Med Sci* 2013; 28: 383-90.
- Hodjati H, Rakei S, Johari HG, Geramizedeh B, Sabet B, Zeraatian S. Low-level laser therapy: an experimental design for wound management: a case-controlled study in rabbit model. *J Cutan Aesthet Surg* 2014; 7: 14-7.
- Gál P, Mokry M, Vidinsky B, Kilik R, Depta F, Harakalová M, et al. Effect of equal daily doses achieved by different power densities

- of low-level laser therapy at 635 nm on open skin wound healing in normal and corticosteroid-treated rats. *Lasers Med Sci* 2009; 24: 539-47.
30. Zhang J, Guan M, Xie C, Luo X, Zhang Q, Xue Y. Increased growth factors play a role in wound healing promoted by noninvasive oxygen-ozone therapy in diabetic patients with foot ulcers. *Oxid Med Cell Longev* 2014; 273475.
  31. Gupta G, Mansi B. Ozone therapy in periodontics. *J Med Life* 2012; 5: 59-67.
  32. Valacchi G, Lim Y, Belmonte G, Miracco C, Zanardi I, Bocci V, et al. Ozonated sesame oil enhances cutaneous wound healing in SKH1 mice. *Wound Repair Regen* 2011; 19: 107-15.
  33. Kim HS, Noh SU, Han YW, Kim KM, Kang H, Kim HO, et al. Therapeutic effects of topical application of ozone on acute cutaneous wound healing. *J Korean Med Sci* 2009; 24: 368-74.
  34. Koca K, Yurttas Y, Bilgic S, Cayci T, Topal T, Durusu M, et al. Effect of preconditioned hyperbaric oxygen and ozone on ischemia-reperfusion induced tourniquet in skeletal bone of rats. *J Surg Res* 2010; 164: e83-9.
  35. Zhang J, Guan M, Xie C, Luo X, Zhang Q, Xue Y. Increased growth factors play a role in wound healing promoted by noninvasive oxygen-ozone therapy in diabetic patients with foot ulcers. *Oxid Med Cell Longev* 2014; 273475.