

CIRCUMCAVAL URETER : A CASE REPORT

Orhan Göğüş*

Y. Ziya Müftüoğlu*

Yaşar Bedük**

Şahabettin Meto***

CASE REPORT

B.K., a 40-year-old woman was hospitalized with the complaints of back pain and swellings on her legs. Past history indicated a period of colicky pains 10 years ago and progressive edema in recent years treated by antidiuretics. Besides, she described gastritis, cholecystopathy, discal hernia and anginal distress. One month ago right hydronephrosis was recognised on IVP and ultrasound incidentally during an ordinary check-up.

Physical examination revealed a healthy, obese woman in no apparent distress. The blood pressure was 115/70 mm Hg and pulse 84/min. The only remarkable signs were; enlargement of the thyroid gland and right costovertebral angle tenderness. She had no marked edema.

Urine sediment was negative in respect to red and white blood cells. Urine culture was also negative. Hematocrit was 42 percent. Blood urea nitrogen was 14 mg. % and electrolytes were within normal limits. Chest films and electrocardiography showed no pathology. An IVP demonstrated a normal collecting system on the left and a delayed excretion with pyelocaliectasis and ureterectasis of the upper third of the ureter (Figure 1). This was supported by ultrasonography and retrograde pyelography.

The right ureter was explored through a flank incision and was found to cross under the vena cava approximately 7 cm. distal to the ureteropelvic junction. The proximal segment of the ureter was dissected free of the vena cava and transected at the point just beneath the

* Professor in the Urology Department of Ankara University Medical Faculty

** Specialist in the same Department

*** Resident in the same Department

uretero-pelvic junction. Then it was relocated anteriorly by an end-to-end anastomosis with interrupted 4-0 polygalactic acid sutures. A double-j stent was inserted into the ureter. Convalescence was uneventful. Early postoperative films revealed some improvement in right hydronephrosis (Figure 2).

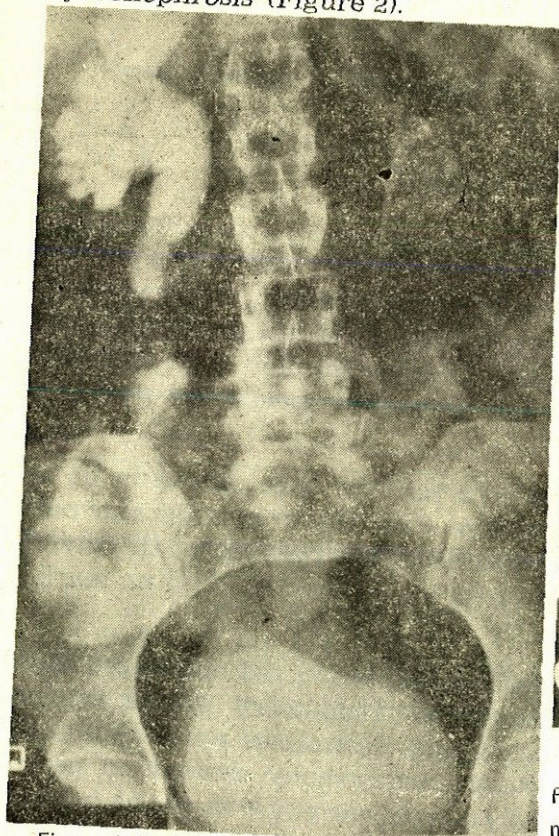


Figure 1. Radiological sign of the circumcaval ureter. Note the j-type appearance of the upper ureter.

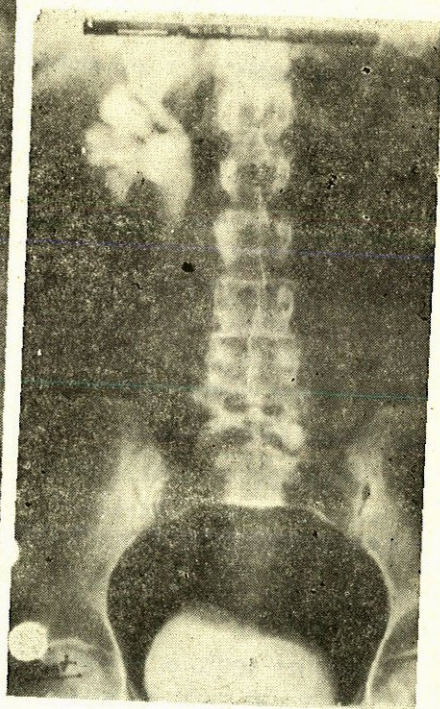

Figure 2. Early control IVP taken two months after the operation. Note mild improvement of right hydronephrosis.

DISCUSSION

A circumcaval ureter is a rare congenital anomaly, in which ureter passes behind and is compressed by the inferior vena cava (1). This anomaly is known to the urologists also as «retrocaval ureter». But the term of circumcaval ureter is preferred, because rarely a ureter lies behind the vena cava all along its course but it encircles it

usually at the level of L₃-L₄ (1,3). This is a matter of vascular maldevelopment rather than ureteral (2,3). The incidence of this anomaly is about 1 in 1500 cadavers and it's four times more common in males than in females. Circumcaval ureter is considered to be a right sided anomaly but a left-sided example was reported by Brooks in a case of situs inversus (2,4).

Symptoms are related to ureteral obstruction, resulting hydronephrosis and infection. Pain can resemble renal colic but usually is intermittent, dull and aching. Hematuria is present frequently in varying degrees. Many cases of this anomaly are found incidentally on radiological examinations. (1,4) In the excretory urography the dilated ureter is seen to descend from the pelvis and than to curve upwards and medially forming a reversed J appearance. In dubious cases retrograde pyelogram may confirm the diagnosis. Inferior venacavagram in conjunction with a retrograde pyelogram is helpfull in cases in which diagnosis can not be established from IVP and retrograde pyelogram. (1,2,4)

A corrective surgery should be the treatment of choice unless advances hydronephrosis, pyelonephritis or calculus disease exists in which nephrectomy could be mandatory. Surgical correction involves ureteral division, with relocation and uretero-ureteral or uretero-pelvic renastomosis. Meanwhile, damaged and avascular segments must be excised, kinks must be straightened whenever this is possible without damaging the blood supply of the distal ureter. Uretero-ureteric anastomosis must be long oblique without any abrupt transition from the dilated to the narrow segment. The junction should be splinted preferably with a double-J stents. (2,3,4).

ÖZET

«Sirkum kaval üreter» ender görülen konjenital vasküler bir anomalidir. Sağ tarafta görülür, ancak sol taraflı bir vak'a rapor edilmiştir. Genellikle İVP de tesadüfen bulunur. Semptomlar hidronefroz ve buna bağlı gelişen enfeksiyon ve taş hastalığına aittir. Cerrahi tedavi, üreterin leze segment üstünden ve geniş bir kısmından kesilip öne alınması ve orada reanastomoz yapılmasından ibarettir. Bu raporda, bir sirkumkaval üreterli hasta takdim edilip; klinik ve radyolojik kriterleri ile cerrahi tedavisi tartışılmıştır.

ABSTRACT

Circumcaval ureter is a congenital vascular anomaly which is seen on the right side except one case of situs inversus reported in the Literature. It's usually recognised incidentally on an IVP. Symptoms are related to hydronephrosis and resulting disorders such as infection or stone disease. Surgical correction consists of division of the affected ureter in its dilated portion and reanostomosing it anteriorly. Herein, we present a case of circumcaval ureter with its clinical and radiological manifestations and surgical management.

REFERENCES

1. Carrion, H. Gatewood, J., Politano, V., Morillo, G. and Lynne, C. : Retrocaval ureter : Report of 8 cases and the surgical management. *J. Urol.*, 121 : 514, 1979.
2. Kenawi, M.M. and Williams, I. : Circumcaval ureter : A report of four cases in children with a review of the literature and a classification. *Br. J. Urol.*, 48 : 183, 1976.
3. Perlmutter, A.D., Retik, A.B., Bauer, S.B. : Anomalies of the upper urinary tract. In : Campbell's Urology, Vol. 2, fifth edition. Cann, C. (ed) W.B. Saunders Company, 1986.
4. Ralph, E., Brooks, J.R. : Left retrocaval ureter associated with situs inversus, *J. Urol.* 88 : 484, 1962.