

Jacopo Berengario da Carpi's Contributions to Neuroanatomy*

Jacopo Berengario da Carpi'nin Nöroanatomiyeye Katkıları

İlhan Bahşiⁱ, Saliha Seda Adanırⁱⁱ, Mustafa Orhanⁱⁱⁱ, Piraye Kervancıoğlu^{iv}

ⁱMD, PhD. Gaziantep University, Faculty of Medicine, Department of Anatomy

<https://orcid.org/0000-0001-8078-7074>

ⁱⁱGraduate Student of Anatomy, Gaziantep University, Faculty of Medicine

<https://orcid.org/0000-0002-9098-5194>

ⁱⁱⁱProf. Dr. Gaziantep University, Faculty of Medicine, Department of Anatomy

<https://orcid.org/0000-0003-4403-5718>

^{iv}Prof. Dr. Gaziantep University, Faculty of Medicine, Department of Anatomy

<https://orcid.org/0000-0003-3231-3637>

ABSTRACT

Jacopo Berengario da Carpi was an Italian physician. He wrote many books on anatomy and surgery.

In this study, Jacopo Berengario da Carpi's books and his contributions to neuroanatomy was researched.

Berengario described vermiform appendix, arytenoid cartilage, thymus, seminal vesicle, sphenoid sinus, pineal gland, choroid plexus, tympanic membrane, auditory ossicles and he explained in detail the cardiac valves, pancreas and kidneys. Berengario clearly identified to the differences in the dimension of the chest and pelvis between males and females. Additionally, he described the vertebral column, spinal nerves, recurrent laryngeal nerve and ventricles of the brain. He depicted many anatomical structures with an artistic point of view in his drawings. It is also seen that, he mentioned on knowledge of previous physicians and made comments on this knowledge in his books.

Jacopo Berengario da Carpi should be appreciated because of his valuable scientific contributions.

Keyword: History of medicine, Jacopo Berengario da Carpi, Neuroanatomy

ÖZ

Jacopo Berengario da Carpi İtalyan bir doktordu. Berengario, anatomi ve cerrahi alanda birçok kitap yazmıştır.

Bu çalışmada Jacopo Berengario da Carpi'nin yazmış olduğu eserler ve nöroanatomiyeye yaptığı katkıları incelendi.

Berengario, appendix vermiformis, cartilago arytenoidea, thymus, vesicula seminalis, sinus sphenoidalis, glandula pinealis, plexus choroideus, membranae tympani ve ossicula auditoria'yı tasvir etmiş, kardiyak kapakları, pankreas ve dalağı ise detaylı bir şekilde açıklamıştır. Berengario, erkeklerin ve kadınların göğüs ve pelvis boyutlarındaki farklılıkların belirgin tariflerini yapmıştır. Bunlara ek olarak, columna vertebralis, nervi spinales, nervus laryngeus recurrens ve beyin ventriküllerini tasvir etmiştir. Berengario çizimlerinde anatomik yapıları sanatsal bir bakış açısıyla göstermiştir. Ayrıca, Berengario'nun kendinden önceki hekimlerinin bilgilerinden bahsettiği ve bu bilgileri kitaplarında yorumladığı görülmektedir.

Jacopo Berengario da Carpi bilime yaptığı değerli katkıları nedeniyle takdir edilmelidir.

Anahtar Kelimeler: Jacopo Berengario da Carpi, Nöroanatomiyeye, Tıp tarihi

* *Lokman Hekim Dergisi*, 2018; 8 (3): 205-211

DOI: 10.31020/mutftd.446274

Geliş Tarihi – Received: 15 Aralık 2017; Kabul Tarihi - Accepted: 27 Mart 2018

İletişim - Correspondence Author: İlhan Bahşi <dr.ilhanbahsi@gmail.com>

His Life

Jacopo Berengario da Carpi is an Italian physician (Fig. 1).^{1,2} There are diverse knowledge about his date of birth and death in the literature. There is some information in the literature that the date of birth is 1460³ or 1470^{4,5} and the date of death is 1530^{3,5} or 1550.⁴ There have been discussions about the real name for a long time.⁶ The name Jacobus de Barigatiis, the son of the surgeon named Faustinus from Carpi, is clearly indicated in his testament shown by Policarpo Guaitoli.⁶ Di Ieva et al.³ stated that his real name was probably Jacopo Barigazzi. His name is also known as Jacobus Berengarius Carpensis, Jacopo Barigazzi, Giacomo Berengario da Carpi or just Carpus.¹




Fig. 1 The portrait of Jacopo Berengario da Carpi²

Because Berengario's father was a surgeon, he followed footsteps of his father.^{3,4} One of the most important steps in his life was his graduation in philosophy and medicine at the University of Bologna in 1489. Berengario was educated by anatomist Gabriele Zerbi (1445–1505). While Berengario was about 40 years old, he became an instructor in anatomy, and professor of medicine in 1505.³ Berengario, the most famous of the successors of Mondino de Luzzi (1270-1326), studied hundreds of cadaver and worked in Bologna for about 25 years (1502-1527) as an instructor at several universities.⁷ Choulant et al.⁸ described him as a founder of a new epoch, they stated that he was tireless observer and fixed many mistakes. Berengario had lived in Ferrara during the last twenty years of his life.⁴ Eustachio and Falloppia defined him as restorator of anatomy. Berengario was influenced by some Italian dynasties (Medici Family, Pio Family, Gonzago Family, d'Este Family). Besides he was protected by Julius II, Leo X and Clement VII. He had a good relationship with intellectuals at that time.⁶ Berengario was asked for treat some of the famous names of the times, including members of the Pope's family. As a physician, he established a reputation by treating the syphilis disease through mercury.³

His Books

Berengario wrote many books on anatomy and surgery.⁹⁻¹⁴ The first of these was *Anatomia Mundini noturer impieffa ac per carpum castigata* which was about the anatomical knowledge of Mondino de Luzzi published in 1514 (Fig. 2).⁹ This book was represented the characteristic reaction of 16th century against Galenic and Arabic medical tradition.^{3,9}

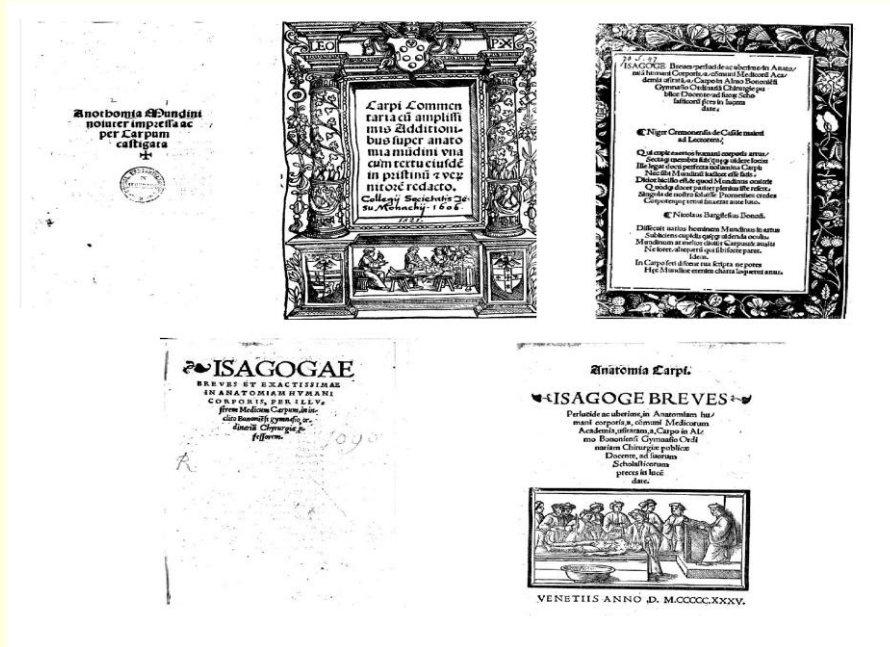


Fig. 2 Title page of *Anatomia Mundini noturer impieffa ac per carpum castigata*⁹, *Carpi commentaria cum amplissimis additionibus super Anatomia Mundini*¹¹, *Isagoge Breves per lucide ac uberime, in anatomiam humani corporis*¹², *Isagogae Breves et exactissimae in anatomiam humani corporis* and the illustrations in this book¹³ and *Anatomia Carpi Isagoge breves per lucide ac uberime, in anatomiam humani corporis* and the illustrations in this book¹⁴

The famous book *Tractatus de fractura calve sive cranei carpo editus* published in 1518 is a surgical book on which the fracture of skull are mentioned and this book is considered on the first "modern" textbook of neurosurgery.^{10, 15, 16} There is a head figure which has three cells on the cover of the book and this book includes many images of instruments (Fig. 3).¹⁰ In addition, when Berengario explained these instruments, he referred to Galen (130-210) and Avicenna (980-1037), and also informed about the instruments that they used.¹⁰

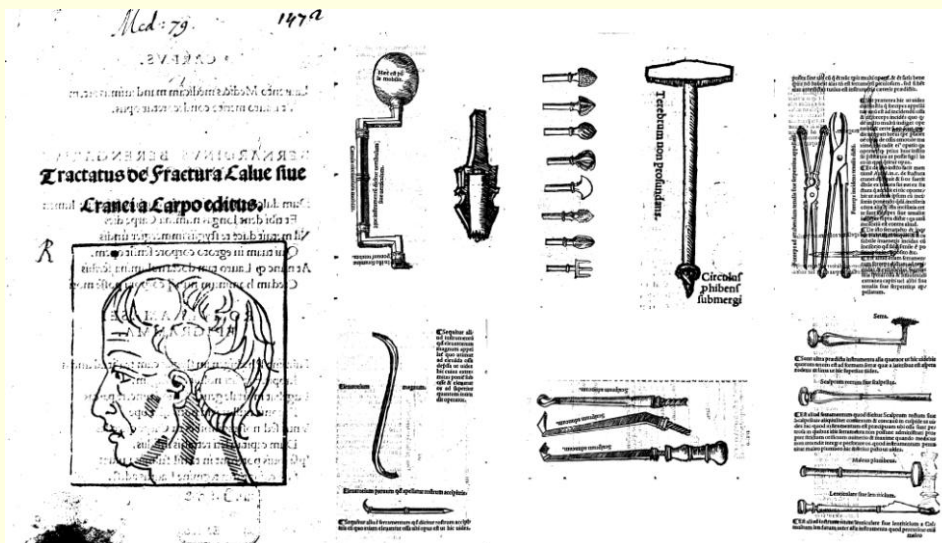


Fig. 3 Title page of *Tractatus de fractura calve sive cranei carpo editus* and the illustrations in this book¹⁰

Carpi commentaria cum amplissimis additionibus super Anatomia Mundini published in 1521, was written by Berengario, is considered as the first illustrated anatomy book.^{11, 17, 18} This book has many illustrations (Fig. 2).¹¹

Berengario presented many excellent anatomical illustrations about cadaveric dissections in *Isagoge Breves perlucide ac uberime, in anatomiam humani corporis* published in 1522 (Fig. 2).¹² Tascioglu and Tascioglu¹⁹ state that the illustrations in this book are more developed than Leonardo da Vinci's (1452-1519) drawings. The second edition of this book published in 1523.

Isagogae Breves et exactissimae in anatomiam humani corporis, published in 1530, has many images such as recurrent laryngeal nerve, vertebral column and ventricular system of the brain (Fig. 2).¹³

Anatomia Carpi Isagoge breves perlucide ac uberime, in anatomiam humani corporis, published in 1535, made him one of the most important anatomists before Andreas Vesalius (1514-1564).^{1, 5, 14} There are many important illustrations in this book (Fig. 2).¹⁴

Berengario referred to his previous books, and used some illustrations were included in these books. In these drawings, portraying human as posing alive models and the anatomical visuals as well as the artistic display of the environmental structures are characteristic of the anatomical drawings of this **period**. The drawings of Andreas Vesalius better than Berengario give rise to thought that Andreas Vesalius was influenced by Berengario.

Berengario de Carpi stated that he was the first actual entrepreneur who showed the structure of the human body in drawings and made them into books.⁴ However, Tascioglu and Tascioglu¹⁹ stated that anatomical visuals have been produced since Hellenistic Alexandria about 300 BC.

Berengario described vermiform appendix, arytenoid cartilage, thymus, seminal vesicle, sphenoid sinus, pineal gland, choroid plexus, tympanic membrane, auditory ossicles and he explained in detail the cardiac valves, pancreas and kidneys. Additionally, Berengario clearly identified to the differences in the dimension of the chest and pelvis between males and females.³ It is also seen that, he mentioned on knowledge of previous physicians and made comments on this knowledge in his books.

Contributions to Neuroanatomy

Vertebral Column and Spinal nerves

Berengario showed vertebral column and spinal nerves in *Carpi commentaria cum amplissimis additionibus super Anatomia Mundini* (Fig. 4a)¹¹ *Isagoge Breves perlucide ac uberime, in anatomiam humani corporis* (Fig. 4b)¹², *Isagogae Breves et exactissimae in anatomiam humani corporis* (Fig. 4c and 4d)¹³ and *Anatomia Carpi Isagoge breves perlucide ac uberime, in anatomiam humani corporis* (Fig. 4e).¹⁴ The spinal nerves were shown of being one-sided in these drawings.

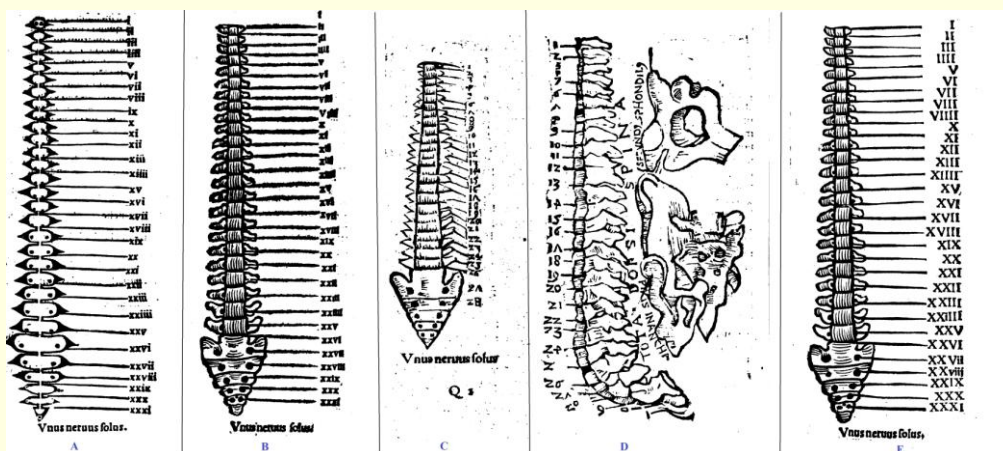


Fig. 4 Display of vertebral column and spinal nerves in four different books of Berengario. Date of publication of books A)1521, B)1522, C and D)1530, E)1535¹¹⁻¹⁴

Twenty-four vertebrae, sacrum, coccyx and thirty-one spinal nerves are properly depicted in the Fig. 4a. The first cervical spinal nerve exists from the upper of first cervical vertebra and the other spinal nerves leave from the hole between the upper and lower vertebrae. However, one more spinal nerve is displayed incorrectly that it exists from level of third sacral vertebra, therefore the thirty-first spinal nerve (coccygeal spinal nerve) which should have left from coccyx, shown to be incorrectly formed between sacrum and coccyx. Berengario did not draw sacral and coccygeal vertebrae as a single bone, but as separate vertebrae in Fig. 4a.

Number of vertebrae and spinal nerves are stated correctly in the Fig. 4b. First cervical spinal nerve originates from upper of first cervical vertebra and the other spinal nerves leave from the hole between the upper and lower vertebrae correctly. However, one more spinal nerve is wrongly in the level of fifth lumbar vertebrae. Thus thirty-first spinal nerve (coccygeal spinal nerve) which should have left from coccyx, has been shown to come out incorrectly between sacrum and coccyx. Unlike in Fig. 4a, sacrum is shown as a single bone. Berengario drew vertebrae, sacrum and coccyx more realistically in comparison with Fig. 4a.

In the Fig. 4c, number of vertebrae are correct but number of spinal nerves which were shown twenty-eight are mistake. It is shown that two spinal nerves left among fifth lumbar vertebrae and sacrum. Sacral and coccygeal spinal nerves are not depicted. Sacrum and coccyx are shown correctly but these were drawn as a single bone.

The numbers of spinal nerves are correctly drawn as thirty-one in Fig. 4d, however first cervical spinal nerve is shown that come out incorrectly below first cervical vertebra. Because one more vertebra is drawn, thirty-first spinal nerve (coccygeal spinal nerve) properly leaves from coccyx. Sacrum and coccyx are not clearly depicted as separate bones. Also axis and bony pelvis are drawn separately and sacrum is shown as a single bone in Fig. 4d. Di Leva et al.³ stated that the vertebral column was shown by Guido da Vigevano (1280-1349) three centuries ago, but dens of the epistropheus (odontoid process) was firstly illustrated in the books of Berengario (Fig. 4d).

The drawing in Fig. 4e is similar to Fig. 4b, with the mistakes and truths. Fig. 4b and Fig. 4e appear to be more clear than the other pictures. When the books are evaluated as per the date of publishing, it take attention that the pictures in the Fig. 4c and Fig. 4d are more difficult to understand than the pictures in the previous books (Fig. 4a and Fig. 4b).

Recurrent Laryngeal Nerve

Berengario depicted recurrent laryngeal nerve and its intercourse with heart in the heart picture in the book named *Isagogae Breves et exactissimae in anatomiam humani corporis* (Fig. 5).¹³ Aortic arch and ascending aorta are shown incorrectly as two different arteries exiting from heart. Zeiger et al.²⁰ stated that this nerve in the figure is left recurrent laryngeal nerve (Fig. 5). However, according to us in this figure, aortic arch is the right side of the heart and it continues downward as descending aorta. Associated with aortic arch and recurrent laryngeal nerve are pointed out but the recurrent laryngeal nerve passes below aortic arch which reside in the right side wrongly, and it separates to the branch on the front. However, the vagus nerve is not state in the figure. Also the left auricula is stated in this drawing, aortic arch and recurrent laryngeal nerve are depicted on the opposite side.

Berengario stated that if a surgeon is unaware of anatomy of this region “half-impaired” or “fully-impaired” voice may result.²⁰ It is quite meaningful to describe that the unilateral and bilateral recurrent laryngeal nerve damage which may occur as a result of surgical procedure without paying attention to the anatomy of this region, 500 years ago. This situation is an extremely striking example of the place and importance of anatomy in the clinic.

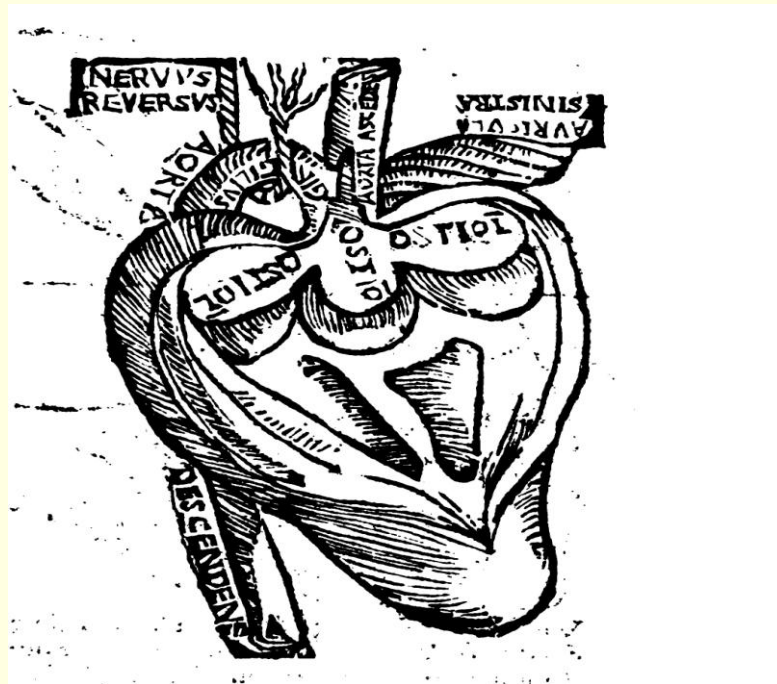


Fig. 5 Display of recurrent laryngeal nerve in *Isagogae Breves et exactissimae in anatomiam humani corporis*¹³

The Ventricles of the Brain

Berengario showed brain ventricles in *Isagoge Breves per lucide ac uberime, in anatomiam humani corporis* (Fig. 6)^{3, 21} published as second edition in 1523 and *Isagogae Breves et exactissimae in anatomiam humani corporis* published in 1530 (Fig. 6).¹³ Both drawings are similar.

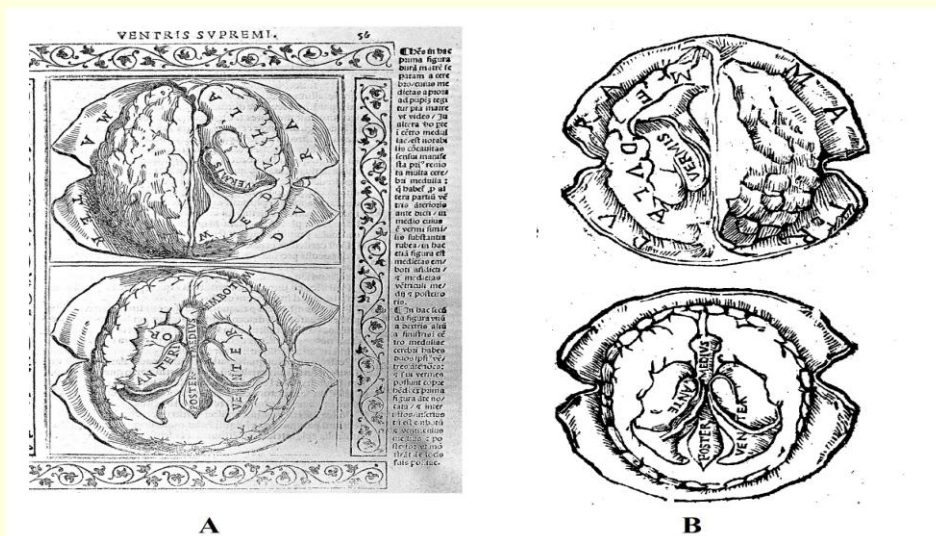


Fig. 6 Display of the ventricular system in the second edition of *Isagoge Breves per lucide ac uberime, in anatomiam humani corporis* published in 1523 (A) and *Isagogae Breves et exactissimae in anatomiam humani corporis* (B)¹³

The brain is depicted from superior and inferior aspect in the Fig. 6. In the figures shown from superior aspect of the brain, the dura mater has midsagittal section and is pulled up on both sides. Gyri clearly appear in the left hemisphere. The right hemisphere has a horizontal section and thus the right lateral ventricle was shown in this side. The posterior horn of the lateral ventricle is clearly depicted in these illustrates but the other parts of lateral ventricle is not manifest. Choroid plexus is named as *vermis* in the pictures by Berengario.²² The part called *Medulla*, which is in the anterior, posterior and lateral sides of the ventricles, probably describes the white matter inner part of the brain.

Dura mater has coronal section in the brain where is shown from the inferior aspect in the pictures (Fig. 6).

The inferior part of the brain is depicted without brainstem. Both hemispheres have horizontal section from the same level. The lateral ventricle was named *anterior venter* and the posterior horn of the lateral ventricle is clearly shown but is not named. The other parts of the lateral ventricle are not shown plainly. It is thought that the structure called *Embotum*, which is in the anterior side of the midline, is infundibulum and the third ventricle is just behind this structure.²² There is incompleteness in these figures but it is seen that the localization, shape and surroundings of the ventricles were drawn close to true, when the circumstances of the period were considered.

Pineal Gland

Berengario described pineal gland as *pineapple, glandulous flesh* and *caro glandulosa* (Latin: *glandulous flesh*), however he didn't show in *Isagoge Breves perlucide ac uberime, in anatomiam humani corporis*.^{12,22}

CONCLUSIONS

Jacopo Berengario da Carpi depicted many anatomical structures with an artistic point of view in his drawings. Berengario should be appreciated because of his valuable scientific contributions.

Conflict of interest

The authors declare that there is no conflict of interest regarding the publication of this paper.

REFERENCES

1. Jacopo Berengario da Carpi. https://en.wikipedia.org/wiki/Jacopo_Berengario_da_Carpi. Accessed 10 Oct 2017
2. Jacopo Berengario da Carpi's portrait. <http://himetop.wikidot.com/jacopo-berengario-da-carpi-s-portrait>. Accessed 10 Oct 2017
3. Di Ieva A, et al. Berengario da Carpi: a pioneer in neurotraumatology. *J Neurosurg* 2011;114(5):1461-70.
4. Pilcher LS. Jacobus Berengarius Carpi and his Commentaries on Mundinus. *Med Library Hist J* 1903;1(1):1-8
5. Singer R. Studies in Pre-Vesalian Anatomy: Biography, Translations, Documents by LR Lind. *Perspect Biol Med* 1976;19(2):296-8.
6. De Santo NG, et al. Berengario da Carpi. *Am J Nephrol* 1999;19(2):199-212.
7. Cushing H. Ercole Lelli and his écorché. *Yale J Biol Med* 1937;9(3):199.b-1
8. Choulant L, Garrison FH, Streeter EC. History and bibliography of anatomic illustration in its relation to anatomic science and the graphic arts. The University of Chicago Press, Chicago; 1920.
9. JB da Carpi. *Anatomia Mundini noturer impieffa ac per carpum caftigata*; 1514.
10. JB da Carpi. *Tractatus de fractura calve sive cranei carpo editus*. Hieronymum de Benedictus, Bologna; 1518.
11. JB da Carpi. *Carpi commentaria cum amplissimis additionibus super Anatomia Mundini*; 1521.
12. JB da Carpi. *Isagoge Breves perlucide ac uberime, in anatomiam humani corporis*. Benedictum Hectors, Bologna; 1522.
13. JB da Carpi. *Isagogae Breves et exactissimae in anatomiam humani corporis*. Strasburg, France; 1530.
14. JB da Carpi. *Anatomia Carpi Isagoge breves perlucide ac uberime, in anatomiam humani corporis*. Venetiis anno; 1535.
15. Goodrich JT. A millennium review of skull base surgery. *Childs Nerv Syst* 2000;16(10):669-85.
16. Lind LR, da Carpi B. Berengario da Carpi on fracture of the skull or cranium. *Trans Am Philos Soc* 1990;80(4):i-164.
17. Sellars N. *Anatomy of Optics and Light*. Culture Machine 2010;11:53-66
18. Deming D. *Science and Technology in World History, Volume 3: The Black Death, the Renaissance, the Reformation and the Scientific Revolution*. Jefferson, North Carolina: McFarland; 2012.
19. Tascioglu AO, Tascioglu AB. Ventricular anatomy: illustrations and concepts from antiquity to Renaissance. *Neuroanatomy* 2005;4:57-63
20. Zeiger MA, Shen WT, Felger EA. 'The Supreme Triumph of the Surgeon's Art': A Narrative History of Endocrine Surgery: University of California Medical Humanities Press, San Francisco; 2012.
21. File: Brain, Berengarius, 1523 Wellcome L0000996.jpg. https://commons.wikimedia.org/wiki/File:Brain,_Berengarius,_1523_Wellcome_L0000996.jpg. Accessed 10 Oct 2017
22. Swanson LW. *Neuroanatomical Terminology*. Oxford University press, New York; 2015.