

# Eosinophilic Granulomatosis With Polyangiitis (Churg Strauss Syndrome): Case Report

Polianjitisle Seyreden Eozinofilik Granulomatozis (Churg Strauss Sendromu): Olgu Sunumu

Hakan Tanrıverdi<sup>1</sup>, Fırat Uygur<sup>1</sup>, Bülent Altınsoy<sup>1</sup>, Fatma Erboy<sup>1</sup> Ömer Yazgan<sup>2</sup>, Figen Atalay<sup>1</sup>

1. Bülent Ecevit University, Faculty of Medicine, Department of Pulmonary Medicine, Zonguldak, Turkey

2. Bülent Ecevit University, Faculty of Medicine, Radiology Department, Zonguldak, Turkey

**Corresponding Author:** Hakan Tanrıverdi

Bülent Ecevit University, Faculty of Medicine, Department of Pulmonary Medicine

Bülent Ecevit Üniversitesi sağlık kampüsü, 67100 Esenköy, Kozlu, Zonguldak Turkey

hakante2000@yahoo.com Mobile: +905052352493 Fax: 903722610264

**Geliş tarihi / Received:** 28.06.2015

**Kabul tarihi / Accepted:** 04.11.2015

## Abstract

Eosinophilic granulomatosis with polyangiitis (EGPA) is a systemic necrotizing vasculitis characterized by tissue and blood eosinophilia. Several drugs including leukotriene receptor antagonists (LTRAs) are suspected to trigger EGPA development. Here, we present a case of EGPA unrelated to LTRAs.

**Key words:** Eosinophilia, Leukotriene Receptor Antagonists, Eosinophilic Granulomatous, Vasculitis

## Özet

Polianjitisle birlikte seyreden eozinofilik granülomatozis (Churg Strauss sendromu), nadir, sıklıkla solunum sistemini tutan ve özellikle küçük ve orta çaplı damarları etkileyen, astım ve doku eozinofilisi ile karakterize, sistemik nekrotizan bir vaskülitir. Lökotrien antagonistlerini de içeren pek çok ilacın bu hastalığın gelişiminde rolü olduğundan şüphelenilmektedir. Biz de klinik ve radyolojik bulgularla tanı alan ve lökotrien reseptör antagonistleri ile ilişkili olmadığını düşündüğümüz bir olguyu sunmak istedik.

**Anahtar kelimeler:** Eozinofili, lökotrien reseptör antagonisti, eozinofilik granülomatöz, Vaskülit

## Introduction

Eosinophilic granulomatosis with polyangiitis (EGPA), formerly termed Churg Strauss syndrome, is a rare, systemic necrotizing vasculitis of small and medium-sized vessels associated with asthma and eosinophilia (1,2). Extrapulmonary manifestations may arise and can be life-threatening (2). The etiology of EGPA is poorly understood and the disease often goes unrecognized by clinicians (1). It was reported

recently that several patients developed EGPA after taking the leukotriene receptor antagonists (LTRAs) zafirlukast and montelukast for asthma, but the role of LTRAs in the development of EGPA is unclear (3). Here we present a case of EGPA diagnosed by radiological findings that was not triggered by LTRAs.

## Case report

A 23-year-old man presented with a cough and sneezing to an ear, nose and throat specialist and was

diagnosed with allergic rhinitis and sinusitis. The patient was prescribed antihistamines, nasal steroids, and antibiotics, but the symptoms did not subside. Paranasal sinus computed tomography revealed a thickening of the mucosa of the right maxillary and ethmoid sinuses and an increased density in the soft tissue between the left maxillary and ethmoid sinuses (Figure 1). The patient was referred to our clinic with shortness of breath and wheezing. A physical examination revealed bilateral rhonchi, and a pulmonary function test suggested obstructive airway disease. Although the chest radiography showed no abnormality, a blood workup revealed eosinophilia (12%). The patient was diagnosed with asthma and was prescribed an inhaled corticosteroid, a long-acting beta-agonist, and montelukast. Two months later, the patient was admitted to our emergency department with a peripheral oxygen saturation of 89%, heart rate of 110 bpm and bilateral rhonchi. His blood eosinophil count was  $300/\text{mm}^3$  (1.7%) and his chest radiography was normal. Thorax computed tomography revealed ground glass opacities in the upper lobes of his lungs (Figure 2). The patient was admitted to our clinic with a diagnosis of asthma, pneumonia and respiratory failure. Antibiotics, a bronchodilator and montelukast were administered. The sputum was negative for acid-resistant bacilli. The serum was negative for antinuclear antibody, anti-neutrophil cytoplasmic antibody (ANCA) and rheumatoid factor. The absolute eosinophil count rose to  $9100/\text{mm}^3$  (52%) and the serum total IgE level was 597 IU/ml. The serum was negative for Aspergillus-specific IgE and neither eosinophils in sputum nor parasites in faeces, were detected. Serum troponin I, electrocardiogram and echocardiography were normal and neither proteinuria nor hematuria was detected in urine. According to the criteria of the American College

of Rheumatology (4), the patient was diagnosed with EGPA (with 4 of 6 criteria including asthma, eosinophilia, paranasal sinus abnormality and pulmonary inflammation). Methylprednisolone 1 mg/kg/day was started, and after three months the symptoms and pulmonary infiltrations disappeared completely (Figure 3). The corticosteroid dose was decreased to 4 mg/day but the symptoms worsened, so the dose was raised to 8 mg/day. After one year, the corticosteroid treatment was stopped.

### **Discussion**

Churg Strauss syndrome was first described by J. Churg and L. Strauss in 1951 (3) and recently renamed eosinophilic granulomatosis with polyangiitis (EGPA) (1). EGPA is a rare systemic necrotizing vasculitis of small and medium-sized vessels commonly involving the respiratory system (1,2).

The prevalence of EGPA ranges from 2.4 to 13 cases per million but is higher in the asthmatic population (1,3). Most of the largest series have obtained positivity for ANCA testing around 40% (37.6%–47.6%) of patients with EGPA, although some authors raised it to 70%. When present, ANCA have a perinuclear pattern (pANCA), with specificity for neutrophil myeloperoxidase (MPO) in around 75% of cases (3). Renal, peripheral nerve involvement, and/or alveolar hemorrhage are common in ANCA-positive EGPA patients whereas cardiac, pulmonary, and/or systemic manifestations are common in ANCA-negative EGPA patients (2,3). Our patient was ANCA-negative and had pulmonary involvement, with no evidence of renal, neurologic or cardiac involvement.

The EGPA diagnostic criteria are: asthma; eosinophilia  $>10\%$ ; neuropathy; pulmonary infiltration; paranasal sinus abnormality; and extravascular eosinophilic infiltration in biopsy specimen (4). A presence of 4 of the 6 criteria has a sensitivity of 85% and a specificity of 99.7%. Our

patient exhibited 4 criteria (asthma, peripheral eosinophilia, pulmonary infiltration, and paranasal sinus abnormality), so EGPA was diagnosed without a biopsy.

In EGPA, cardiac involvement is the leading cause of mortality, so radiography, electrocardiography, and transthoracic echocardiography should be performed. In addition, N-terminal pro brain natriuretic peptide and troponin I levels should be determined (1). In our patient, troponin I levels, electrocardiography, and echocardiography were normal and there was no evidence of renal, neurologic or gastrointestinal involvement. Therefore, further tests were not performed.

EGPA patients usually have late-onset allergic asthma, particularly corticosteroid-dependent, and other allergic symptoms (3). However, some patients develop asthma after vasculitis has occurred. A complete pulmonary assessment, including a chest screening and a pulmonary function test (at least spirometry), should be performed at the time of diagnosis (1).

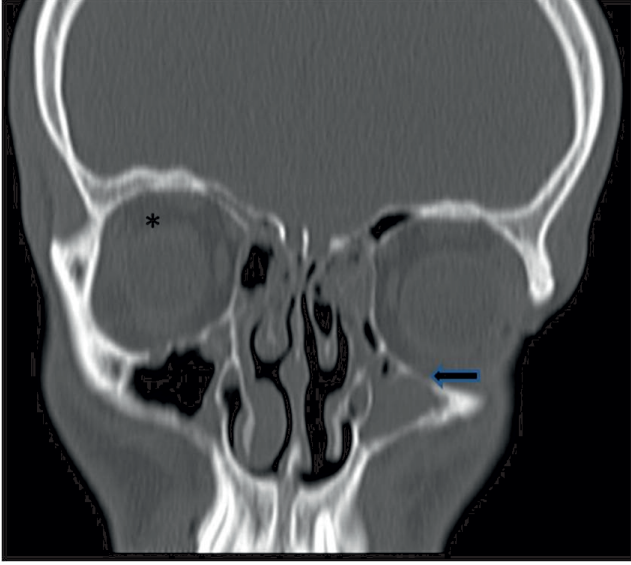
Several drugs including LTRAs, inhaled glucocorticoids, omalizumab, cocaine, and clarithromycin have been implicated in EGPA development (5). However, the relationship between LTRAs and EGPA development is unclear. It was reported that patients developed EGPA when LTRAs entered the treatment regimen for asthma. However, most of these patients had moderate-to-severe asthma and LTRAs were used to facilitate corticosteroid tapering (3). In a recent study (6) based on the US Food and Drug Administration's Adverse Effect Reporting System, between 1996 to 2003, 167 of 181 cases of EGPA were suspected of being triggered by LTRAs. At the time of initiation of LTRA therapy, 36% of the cases had pre-existing EGPA, had reduced or stopped corticosteroid therapy, or had possible prodromal EGPA. The authors of the

study concluded that, in a majority of the cases, LTRA therapy may have played a role in the pathogenesis of EGPA (6). In another study, the risk of EGPA development within 3 months after montelukast treatment started was found to be 4.5%. However, the risk of EGPA development in patients who used inhaled or oral corticosteroids were 3 and 4, respectively (7). In a study of 165 EGPA patients, 126 were using corticosteroids and the disease occurred during the dose tapering in 88% of these patients. In addition, 12 of the EGPA patients were using LTRAs but had never used corticosteroids. In light of these findings, the authors postulated that the vasculitis was induced by the tapering of the corticosteroids rather than the LTRA (8). Our patient presented with asthmatic symptoms, eosinophilia and sinus abnormalities before the montelukast was started. Moreover, montelukast was prescribed several times after the diagnosis of EGPA to control the asthmatic symptoms. Thus, we suggest that the patient was in a prodromal phase of EGPA and that the LTRA did not trigger the disease.

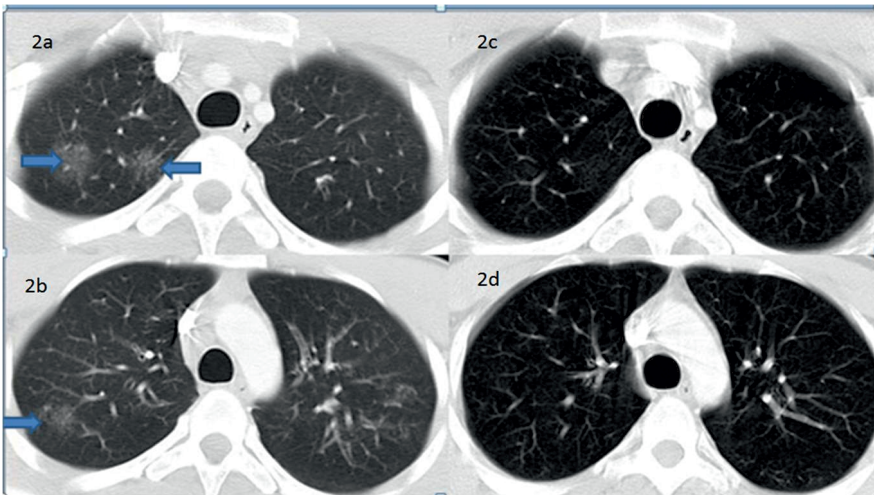
Glucocorticosteroids are the cornerstone of EGPA therapy. In the presence of life-threatening symptoms, methylprednisolone 7.5-15 mg/kg/day is recommended. Induction therapy with 1 mg/kg/day methylprednisolone for 2 or 3 weeks is recommended with dose tapering to a minimum effective dose. Despite the effective treatment, relapses are common and require restarting the therapy or increasing the dose (1). In the present case, the corticosteroid dose was tapered to 4 mg/day but, unfortunately, the symptoms worsened. The dose was increased to 8 mg/day and then stopped after one year.

### **Conclusion**

EGPA is a rare systemic necrotizing vasculitis which has a higher incidence in asthma patients. The factors that trigger the development of EGPA are unclear.



**Figure 1:** Paranasal sinus computed tomography shows thickening of the mucosa of the right maxillary (\*) and ethmoid sinuses and an increased density in the soft tissue between the left maxillary and ethmoid sinuses (arrow).



**Figure 2:** Thorax computed tomography shows bilateral ground glass opacities in the upper lobes of his lungs (2a and 2b, blue arrows), complete regression of lesion after three months of therapy (2c and 2d).

#### References

- Groh M, Pagnoux C, Baldini C, Bel E, Bottero P, Cottin V et al. Eosinophilic granulomatosis with polyangiitis (Churg–Strauss) (EGPA) Consensus Task Force recommendations for evaluation and management. *Eur J Intern Med.* 2015;26 (7):545-53. <http://dx.doi.org/10.1016/j.ejim.2015.04.022>
- Samson M, Puéchal X, Devilliers H, Ribi C, Cohen P, Stern M et al. Long-term outcomes of 118 patients with eosinophilic granulomatosis with polyangiitis (Churg–Strauss syndrome) enrolled in two prospective trials. *J Autoimmun* 2013;43:60-9.
- Ramentol-Sintas M, Martínez-Valle F, Solans-Laqué R. Churg–Strauss Syndrome: An evolving paradigm. *Autoimmun Rev* 2012;12(2):235–40.
- Masi AT, Hunder GG, Lie JT, Michel BA, Bloch DA, Arend WP, et al. The American College of Rheumatology 1990 criteria for the classification of Churg–Strauss syndrome (allergic granulomatosis and angiitis). *Arthritis Rheum.* 1990;33(8):1094-100.
- Yıldız F, Zorludemir S, Erken E. Montelukast ilişkili Churg Strauss sendromu: Üç olgu. *Cukurova Med J* 2014;39(2):347-52
- Bibby S, Healy B, Steele R, Kumareswaran K, Nelson H, Beasley R. Association between leukotriene receptor antagonist therapy and Churg–Strauss syndrome: an analysis of the FDA AERS database. *Thorax* 2010;65(2):132–8
- Hauser T, Mahr A, Metzler C, Coste J, Sommerstein R, Gross WL, et al. The leukotriene receptor antagonist montelukast and the risk of Churg–Strauss Syndrome: a case-crossover study. *Thorax* 2008;63(8):677–82.
- Abril A, Calamia KT, Cohen MD. The Churg Strauss syndrome (Allergic granulomatous angiitis): Review and update. *Semin Arthritis Rheum* 2003;33:106-14.