

## Chemical Injury In The Oral Cavity And Oesophageal Tract Caused By Air Conditioner Cleaning Solution

Klima Temizleme Solüsyonu İçimi Sonrası Oluşan Oral Kavite ve Özafagusdaki Kimyasal Yanık

Mahmut Alp Karahan<sup>1</sup>, Evren Büyükfırat<sup>1</sup>, Ahmet Küçük<sup>1</sup>, Şaban Yalçın<sup>1</sup>

<sup>1</sup>Department of Anesthesiology and Reanimation, Harran University Medical Faculty, Sanliurfa, Turkey )

**Corresponding author:** Yrd.Doç.Dr.Mahmut Alp KARAHAN

Harran Üniversitesi Tıp Fakültesi Anesteziyoloji ve Reanimasyon A.B.D.

Meteoroloji Cad. No:111 Şanlıurfa

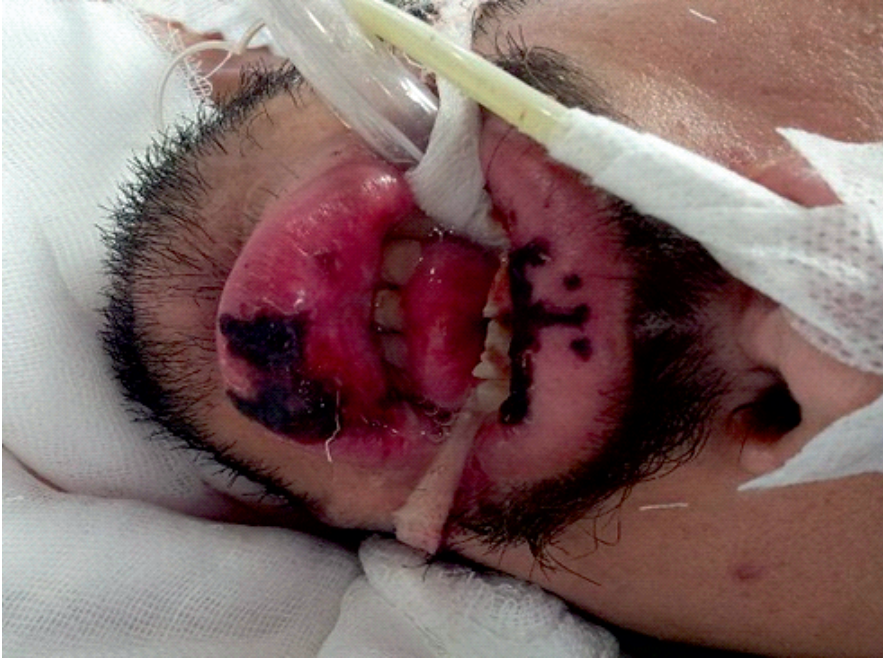E-mail : mahmutalp\_k@yahoo.com +90 4143183436

This case was represented as e-poster at 20<sup>th</sup> Intensive Care Symposium 8-9 May 2015 in İstanbul.

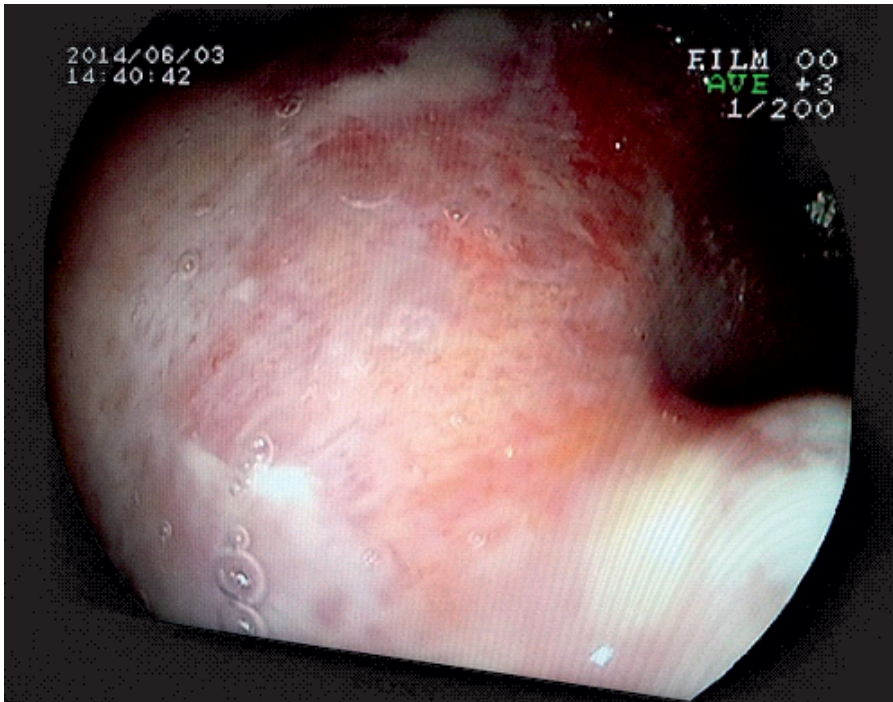
**Geliş tarihi / Received:** 10.10.2015 **Kabul tarihi / Accepted:** 16.10.2015

*Dear Editor;*

More than 25,000 chemicals are commonly used in the industry, agriculture, house cleaners and others, and many of them have been identified as having the potential to cause burns. This makes chemical burns an important potential risk in the household (1). The severity of tissue damage depends on the destructive properties of the ingested substance, duration and the extent of its contact with the tissue. Tissue damage can include the oral mucosa, nasal orifice, gastrointestinal tract and respiratory tract. We present a case of chemical injury in the oral cavity and oesophageal tract resulting from the drinking serpantin cleaner for air conditioning. A 24-year-old man who has mental retardation, had presented to the emergency department via ambulance approximately 30 minutes after drinking serpantin cleaner for air conditioning at his home. Ulcerations all throughout the mouth were noted at the time of the first examination (Figure 1). The patient was lethargic and was not able to respond to sound. The physical examination findings were hypersalivation and dyspnea. Patient was intubated. He admitted to intensive care unit for monitoring and treatment. Endoscopy was planned on 24. hours the hospital day. Endoscopic evaluation in the ICU revealed edema and erythema of the superficial mucosa on superior oesophageal area and in the gastric fundus (Figure 2). General supportive treatment was given. The patient was extubated on the fifth hospital day. Peripheral parenteral nutrition was supplied for seven days. Serpantin cleaner for air conditioning include bases material. Alkalis are particularly destructive on tissues because of their lytic action. Liquefaction loosens tissue planes and allows deeper penetration of the agent so that alkali burns tend to be more severe than acid burns (2). In conclusion, a chemical burn should be carefully managed and may require a team of experts.



**Figure 1)** Ulcerations all throughout the mouth



**Figure 2)** Endoscopic evaluation in the ICU.

**References**

1. Palao R, Monge I, Ruiz M, Barret JP. Chemical burns: pathophysiology and treatment. *Burns*. 2010 ;36(3):295-304.

2. Rallan M, Malhotra G, Rallan NS, Mayall S. Management of chemical burn in oral cavity. *BMJ Case Rep*. 2013 ;22:2013.