

### VOGT-KOYANAGI-HARADA SENDROMU: NADİR BİR PATOLOJİ

#### VOGT-KOYANAGI-HARADA SYNDROME: A RARE PATHOLOGY

Fatma Dilek GÖKHARMAN, MD<sup>1</sup>; Sonay AYDIN MD<sup>1</sup>; Ömer KAZCI MD<sup>1</sup>; Pinar Nercis KOŞAR, MD<sup>1</sup>

<sup>1</sup>Ankara Training and Research Hospital, Department of Radiology, Ankara, Turkey

Geliş tarihi: 05/04/2017

Kabul tarihi: 19/07/2017

*Yazarlar herhangi bir finansal destek kullanmamış olup yazarlar arasında çıkar çatışması yoktur.*

#### ABSTRACT

*Vogt-Koyanagi-Harada syndrome (VKHS) is a multisystemic granulomatous autoimmune disease affecting body parts with high melanocyte content. As far as we know there are fewer than 250 cases described in English literature. In this case report a 47 year old female patient with the complaints of loss of vision, photophobia, ocular pain, hearing disturbances and dizziness will be presented with MRI findings. On orbital MR imaging, there was abnormal thickening and enhancement of the retina/choroid with retinal detachment on left eye. The sclera was spared. Early recognition of VKHS and intense suppression of inflammation in the disease are very important in terms of increasing the visual capacity of the patient. High dose corticosteroid therapy is found to be very effective in treatment.*

#### ÖZ

*Vogt-Koyanagi-Harada sendromu (VKHS) multisistemik, granülatöz, otoimmün bir hastalık olup melaninden zengin dokuları etkilemektedir (ör: göz, santral sinir sistemi, iç kulak, deri vs.). Bildiğimiz kadarıyla VKHS oldukça nadir bir patoloji olup literatürde yaklaşık 250 civarında vaka bildirilmiştir. Bu olgu sunumunda görme kaybı, fotofobi, göz hareketleri ile ağrı, işitme bozukluğu, baş dönmesi şikayetleri ile başvuran, aynı zamanda vitiligo ve alopesi areatası da bulunan 47 yaşında kadın hastanın orbita MRG bulguları sunulacaktır. Hastanın tetkikinde, sol gözünde, posteriora, retina dekolmanının eşlik ettiği retinal kalınlık ve kontrastlanma artışı tespit edilmiş, klinik veriler ve şikayetler de göz önüne alınarak hastaya VKHS tanısı konmuştur. VKHS nin etyopatogenezi tam bir netlik kazanmamıştır; ancak otoimmün süreçler öncelikli olarak düşünülmektedir. Daha sık kadınlarda rastlanan bu patoloji genellikle 20-50 yaş arasında başlamaktadır. Bilateral oküler tutulum oldukça tipik olmakla birlikte bizizm vakamızdaki gibi tek taraflı tutulumlara da rastlanmaktadır. Eşlik eden beyaz cevher lezyonlarının tespitinde kranial MRG önem taşımaktadır. Tanıda görüntüleme bulguları ile klinik verilerin bir arada değerlendirilmesi oldukça önemlidir, yalnızca tek göz tutulumu ya da kranial tutulumla seyreden vakalar nadir de olsa görülebilmektedir. Tanıda bir diğer önemli basamakta bu nadir antijenin temel özelliklerinin bilinmesi ve akılda bulundurulmasıdır. Erken tanı görme keskinliğinin korunmasında oldukça önemlidir. Tedavide yüksek doz steroid uygulaması etkin bir metot olarak belirtilmektedir.*

**Yazışma adresi/Correspondence Address:** Dr. Sonay AYDIN, Ankara Training and Research Hospital, Department of Radiology, Ankara, Turkey

**Tel:** 0312 5953686 **e-mail:** sonaydin89@hotmail.com

## INTRODUCTION

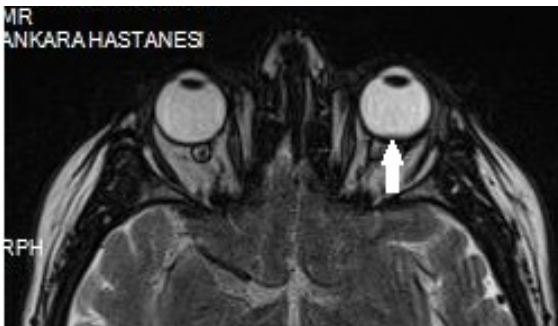
Vogt-Koyanagi-Harada syndrome (VKHS) is a multisystemic granulomatous autoimmune disease affecting body parts with high melanocyte content such as the eye, central nervous system, inner ear, and skin. It is characterized by granulomatous panuveitis with exudative retinal detachment. The disease is mostly seen in Far East and Latin American countries. Patients are generally between 20 to 50 years old at presentation. It affects the female population more. As far as we know there are fewer than 250 cases described in English literature (1, 2). We aimed to present a rare case of VKHS with its magnetic resonance imaging findings.

## CASE REPORT

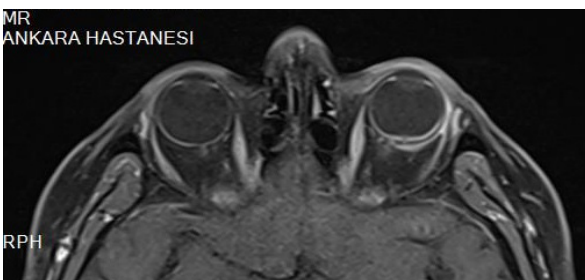
47-year-old female patient applied with the complaints of loss of vision, photophobia, ocular pain, hearing disturbances and dizziness. The ophthalmologic examination revealed left posterior uveitis and disc edema. She has also frontal alopecia areata and vitiligo, too. Cranial and temporal MRI examinations can show no abnormal findings.

On orbital MR imaging, there was abnormal thickening and enhancement of the retina/choroid with retinal detachment on left eye. The sclera was spared (Figure 1).

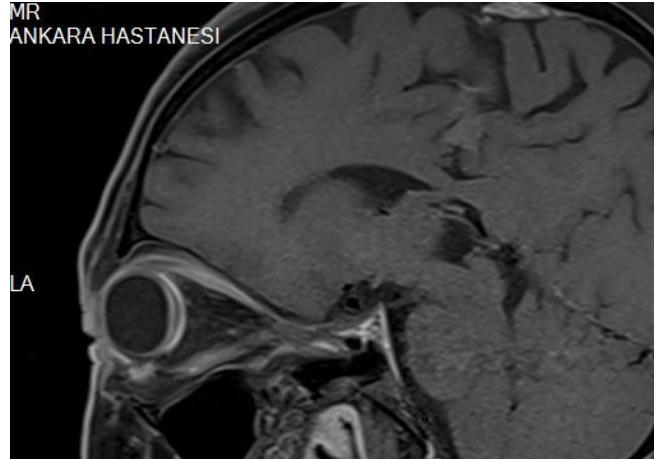
**Figure 1a:** On axial T2WI, an obscure hypointensity was seen at the posterior part of the left eye (arrow)



**Figure 1b:** On axial postcontrast, T1WI, abnormal thickening and enhancement is present with concurrent retinal detachment.



**Figure 1c:** On sagittal postcontrast, T1WI, abnormal thickening and enhancement is present with concurrent retinal detachment.



The patient was diagnosed as VKH syndrome, according to clinical and imaging findings by considering the American Uveitis Society criteria (2). She was treated with Topical corticosteroids (e.g., dexamethasone 0.1 % or prednisolone acetate 1 % eyedrops) in combination with mydriatics/cycloplegics (e.g., tropicamide 1.0 % eyedrops), and systemically oral prednisone, 1.5 mg/kg per day. His symptoms decrease gradually under steroid therapy.

## DISCUSSION

The prevalence of VKHS can vary according to different societies (approximately 7 % in Japan, 1-4 % in the United States and 3 % in Brazil) (2). The etiopathogenesis of VKH disease is not fully understood. The autoimmune response developed in the disease is thought to be induced by skin trauma or infectious agents in susceptible individuals. It is assumed that there is a T cell mediated autoimmune reaction to a common membrane antigen in the tissues originating from melanocytes and / or neural crest in the disease. This autoimmune response results in the destruction of the epidermis, the cochlea, the meninges and the melanocytes in the mouth (3).

The disease is clinically composed of three periods. The first one, so called the prodromal phase, usually begins with symptoms similar to viral infection. This phase is followed by an eye phase of bilateral uveitis developed

1-2 weeks later. In this period, about half of the cases have auditory problems. The eye also develops iridocyclitis, vitritis and papillitis. During the last phase of the disease recovery, skin problems such as poliozis, vitiligo and alopecia can develop (4).

The most common condition in the disease that can cause the most destruction is eye involvement. Eye involvement typically occurs bilaterally. However, rare cases with unilateral involvement, such as our case, have been reported in the literature. The panuveitis usually appears in the granulomatous type. In addition to intense vitreous reaction in the posterior segment, optic disc edema, yellow-white lesions around the fundus, retinal edema in the posterior pole, and exudative retinal detachment can occur (5, 6).

In the differential diagnosis of the disease, sympathetic ophthalmia should be ruled out. It can mimic VKHS with meningial, auditory, eye and skin manifestations. However, the sympathetic ophthalmia usually has a story of penetrating eye trauma or bilateral panuveitis that develops after intraocular surgery. With early diagnosis and appropriate treatment approach, the prognosis of VKH disease is generally good (2).

## CONCLUSION

In conclusion, early recognition of VKHS and intense suppression of inflammation in the disease are very important in terms of increasing the visual capacity of

the patient. Although systemic findings have not been identified, early stage VKHS should be considered in suspected cases. High dose corticosteroid therapy is found to be very effective in treatment.

## REFERENCES

- 1) Lohman BD, Gustafson CA, McKinney AM, Sarikaya B, Silbert SC. MR imaging of Vogt-Koyanagi-Harada syndrome with leptomeningeal enhancement. *AJNR Am J Neuroradiol.* 2011; 32: 169-71.
- 2) Lavezzo MM, Sakata VM, Morita C, Rodriguez EE, Abdallah SF, da Silva FT, et al. Vogt-Koyanagi-Harada disease: review of a rare autoimmune disease targeting antigens of melanocytes. *Orphanet J Rare Dis.* 2016; 11: 29.
- 3) Sheriff F, Narayanan NS, Huttner AJ, Baehring JM. Vogt-Koyanagi-Harada syndrome: A novel case and brief review of focal neurologic presentations. *Neurol Neuroimmunol Neuroinflamm.* 2014; 1: 49.
- 4) Rao NA, Gupta A, Dustin L, Chee SP, Okada AA, Khairallah M, et al. Frequency of distinguishing clinical features in Vogt-Koyanagi-Harada disease. *Ophthalmology.* 2010; 117: 591-9
- 5) Agrawal RV, Murthy S, Sangwan V, Biswas J. Current approach in diagnosis and management of anterior uveitis. *Indian J Ophthalmol.* 2010; 58: 11-9.
- 6) Tugal-Tutkun I, Ozyazgan Y, Akova YA, Sullu Y, Akyol N, Soylu M, et al. The spectrum of Vogt-Koyanagi-Harada disease in Turkey: VKH in Turkey. *Int Ophthalmol.* 2007; 27: 117-23.