

A Comparative Analysis of the Effects of Melatonin and Nimodipine on Vasospasm

Ezgi Akar^{1*}, Kaan Ersegun Batçık², Cengiz Acar², Özlem Ton³, Hüseyin Canaz², Serhat Baydın², Osman Akdemir², İbrahim Alataş²

¹Haydarpaşa Numune Training and Research Hospital, Neurosurgery Department, Istanbul, Turkey
²Haseki Training and Research Hospital, Neurosurgery Department, Istanbul, Turkey
³Şişli Hamidiye Etfal Training and Research Hospital, Pathology Department, Istanbul, Turkey

*Corresponding Author: Ezgi Akar
 Address: Haydarpaşa Numune Training and Research Hospital, Neurosurgery Department, Üsküdar, Istanbul, Turkey.
 E mail: ezgiaycicek@gmail.com

ABSTRACT

Objective: In this study, we aimed to compare the efficacy of nimodipine and melatonin in a rat femoral artery vasospasm model.

Material and Methods: The rats were divided into five groups as follows: Group I (n=8): control group, Group II (n=8): vasospasm group, Group III (n=8): vasospasm + melatonin group, Group IV (n=8): vasospasm + nimodipine group, Group V (n=8 rats): vasospasm + melatonin + nimodipine group. At the end of the 7th day, the femoral arteries were excised and histopathologically examined under light microscope.

Results: Vascular wall of vasospasm group was relatively thicker when compared with the control group. There was a statistically significant difference between the wall thickness of Group II and Group III, IV and V. The maximum reduction of wall thickness was observed in Group V. There was no statistically significant difference in lumen diameter between Group I and Group IV. The lumen diameter was found to be increased in Group III, IV and V when compared with Group II.

Conclusion: The development of experimental peripheral vasospasm has been reduced by the melatonin and nimodipine and their effect was increased when they were used concomitantly.

Keywords: Melatonin, Nimodipine, Cerebral vasospasm, Rat femoral artery, Subarachnoid hemorrhage

INTRODUCTION

Cerebral vasospasm (CV) is the main cause of morbidity and mortality after subarachnoid hemorrhage (SAH). The etiology is multifactorial and remains obscure [1]. Despite experimental and clinical researches, the spasmogenic agents responsible for the development of vasospasm and the mechanisms of action are still poorly understood [2-4]. Although nimodipine has a limited efficacy in the treatment of CV after SAH, it is being used in routine practice. In several studies, melatonin was reported to be effective against free radicals, which were thought to play a role in the etiopathogenesis of SAH [5-8]. There is no study investigating and comparing the therapeutic effects of these substances on the treatment of CV.

The aim of this study is to investigate the effect of melatonin and nimodipine in CV in the early period after SAH. Furthermore, we

aimed to determine which is more effective and whether the combination of these substances improved the efficiency or not.

MATERIALS AND METHODS

The surgical experimental part of this study was performed in Istanbul University, Institute of Experimental Medicine after approved by the ethics committee. Forty male Sprague-Dawley albino rats weighing 220-280 g were used in the study. The "Rat Femoral Artery Vasospasm Model" described by Okada et al. was preferred as vasospasm model [9]. The femoral artery vasospasm model was used because the mortality was high in cv models applied in the brain. Okada found similar histopathological findings femoral artery and in the brain vasospasm model. 40 rats were separated randomly into 5 groups each including 8 rats: control, vasospasm, vasospasm+melatonin, vasospasm+nimodipine, vasospasm+nimodipine+melatonin groups.

Received: 09.01.2018,
 Accepted: 07.08.2018
 DOI: 10.5799/jcei.458757

All rats were anaesthetized by an injection of ketamine (100 mg/kg, intraperitoneal) and allowed spontaneous breathing.

- Group I (n=8 rats) control group; A 10 mm segment of femoral artery exposed by using a microsurgical technique in the inguinal region and a silastic sheath was wrapped around femoral artery.

- Group II (n=8 rats) vasospasm group; After the same surgical procedure, 0.1 ml of fresh blood derived from ventral tail artery was applied directly to the femoral artery.

- Group III (n=8 rats) vasospasm+ melatonin; vasospasm was induced and melatonin at daily doses of 20 mg/kg was applied for 7 days.

- Group IV (n=8 rats) vasospasm+ nimodipine; vasospasm was induced and nimodipine at daily doses of 0.1 mg/kg was applied for 7 days.

- Group V (n=8 rats): vasospasm was induced and melatonin and nimodipine at daily doses of 20 mg/kg and 0.1 mg/kg concomitantly were applied for 7 days.

At the end of 7 days all rats were anaesthetized and sacrificed. The former incisions were opened, and femoral artery samples dissected. All artery samples fixed in 10% formalin solution for 24 hours and following paraffin embedding, tissue sections of 3 µm thickness were obtained. The tissue samples were stained with hematoxylin-eosin (H&E) for histomorphometric analysis and Elastic Van Gieson (EVG) for evaluated internal elastic lamina. The samples from the femoral arteries were measured in 3 different points [10,11]. Lumen diameter and wall thickness of femoral arteries were measured using micrometers.

Statistical Analysis

The data were statistically analyzed using the Kruskal-Wallis and the Mann-Whitney U-tests. The value of $p < 0.05$ was considered as statistically significant. ‘One-way ANOVA test’ was used for the intergroup comparisons of parameters with normal distribution and ‘Tukey HSD test’ was used to determine the group causing the difference in the study. ‘Mann Whitney U test’ was used for the intergroup comparisons of parameters without normal

distribution and ‘Kruskal Wallis Test’ was used for comparisons of means among more than two groups. The results were evaluated in 95% confidence interval and at a significance level of $p < 0.05$.

RESULTS

Histopathological Findings

All femoral artery samples were examined using the light microscope. The vessels in the group I (control group) had a thin and smooth endothelium, a thin and unfolded internal elastic lamina and smooth muscle cells located concentrically (Figure 1A). There was marked luminal narrowing and an increase in the vessel wall thickness in the group II (vasospasm group). Non-intact endothelium, folding of the internal elastic lamina and vacuolization in muscle layer were determined (Figure 1B). Histopathological findings in each of three groups administered medication were found to be similar. Thin and smooth endothelium, concentrically arrayed smooth muscle cells were observed (Figure 1C, D, E).

Morphometric Analysis

According to the result of analysis, it was concluded that there was a significant difference between the mean vessel wall thicknesses (Table 1). It was seen that the mean vessel wall thickness of the melatonin and nimodipine group was minimum (a decrease by % 50 with respect to group of SAH) and the mean vessel wall thickness of SAH group was maximum. Each of nimodipine and melatonin reduced the wall thickness alone, but melatonin was found to be more effective (a decrease by % 44 with respect to group of SAH) (Figure 2).

When we investigated the mean vessel lumen area, vessel lumen area of vasospasm group was reduced significantly compared to the control group. According to the result of analysis, it was seen that the group administered melatonin had the maximum mean vessel lumen area (Table 2). Vessel lumen area was increased in all of the groups administered treatment compared to vasospasm group, but no statistically significant difference was determined between them (Figure 3).

Table 1. Statistical analysis of the mean vessel wall thickness values of the five groups

	Nimodipine		Melatonin		Melatonin + Nimodipine		SAH		Control	
	Mean	±SD	Mean	±SD	Mean	±SD	Mean	±SD	Mean	±SD
Wall Thickness (mm)	0.0646	0.0101	0.055	0.01	0.051	0.012	0.102	0.063	0.098	0.01

SD: Standard deviation

Table 2. Statistical analysis of the mean vessel lumen area of the five groups

	Nimodipine		Melatonin		Melatonin + Nimodipine		SAH		Control	
	Mean	±SD	Mean	±SD	Mean	±SD	Mean	±SD	Mean	±SD
Lumen Area (mm²)	0.261	0.116	0.347	0.094	0.3	0.092	0.099	0.028	0.309	0.068

SD: Standard deviation

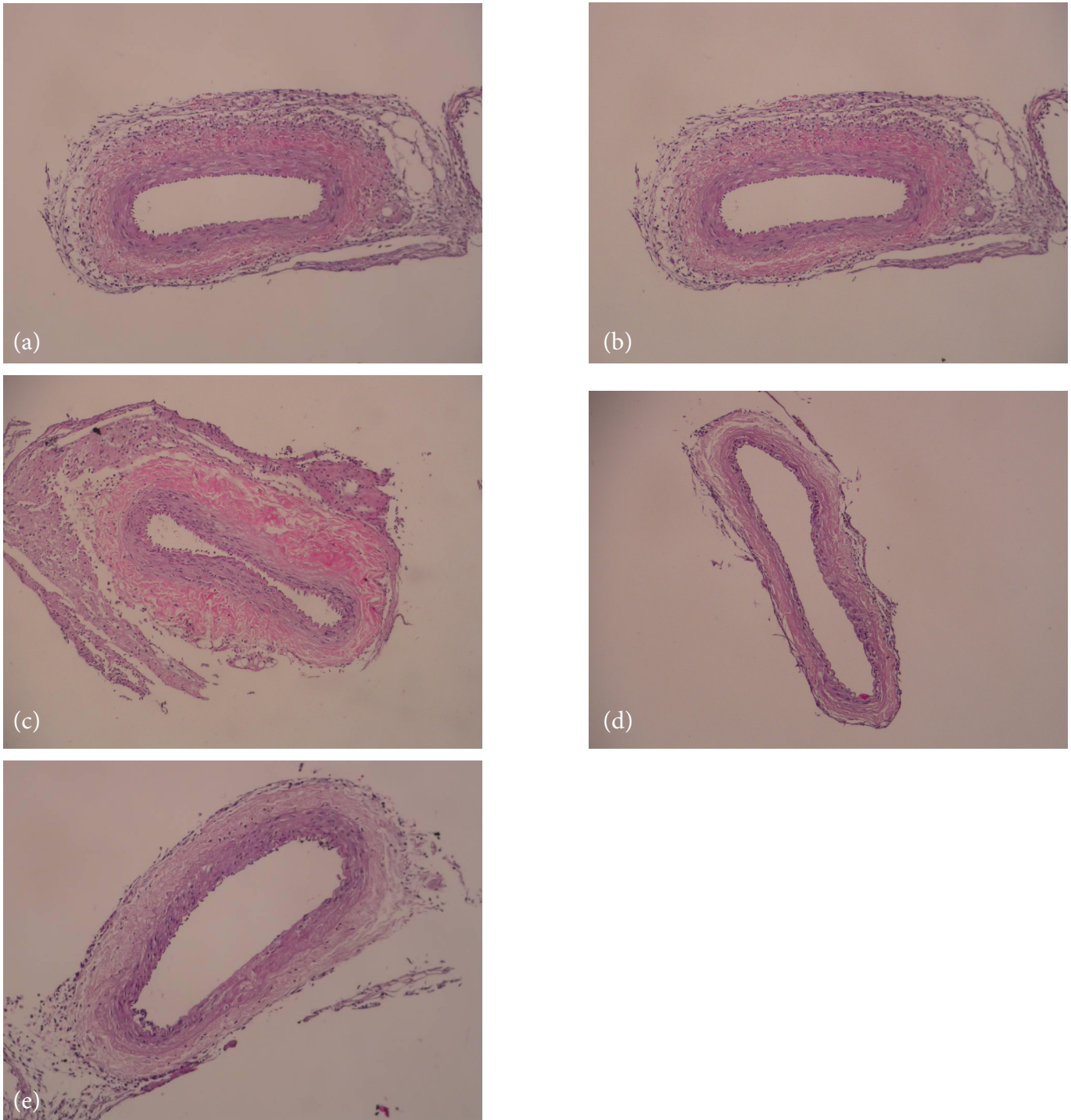


Figure 1. (a) Light microscopic view of the control group (Group I; H&E, x200). (b) Light microscopic view of the vasospasm group (Group II; H&E, x200). (c) Light microscopic view of the group administered melatonin at a dose of 20 mg/kg (Group III, H&E, x200). (d) Light microscopic view of the group administered nimodipine at a dose of 0,1 mg/kg (Group IV, H&E, x200). (e) Light microscopic view of the group administered melatonin at a dose of 20 mg/kg and nimodipine at a dose of 0.1 mg/kg (Group V, H&E, x200).

Effects of Melatonin and Nimodipine on Vasospasm

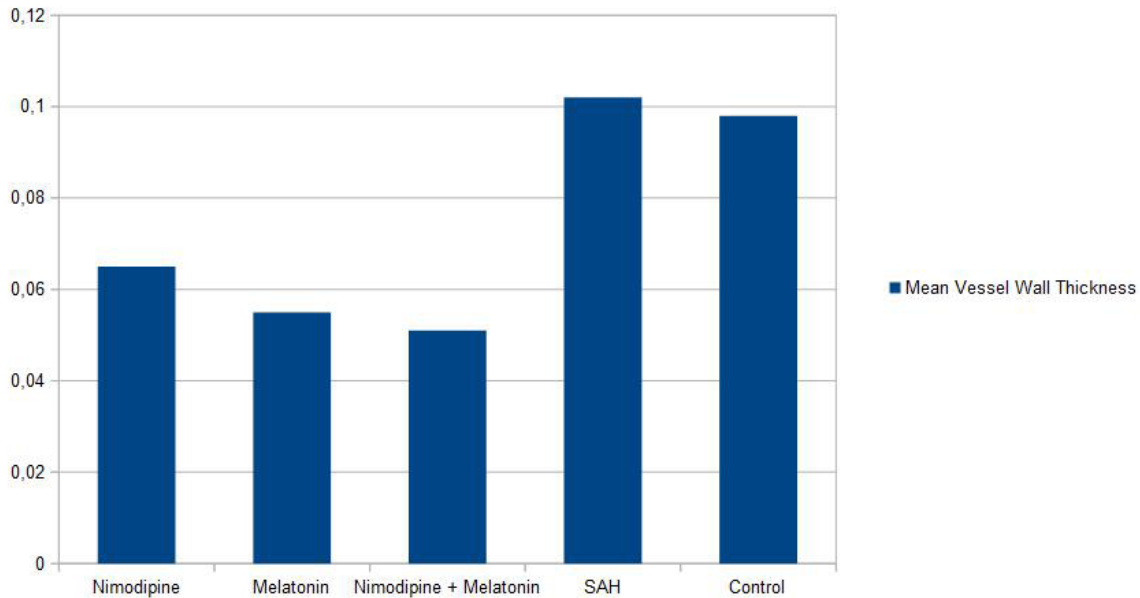


Figure 2. Comparison of mean vessel wall thickness of the five groups (mm)

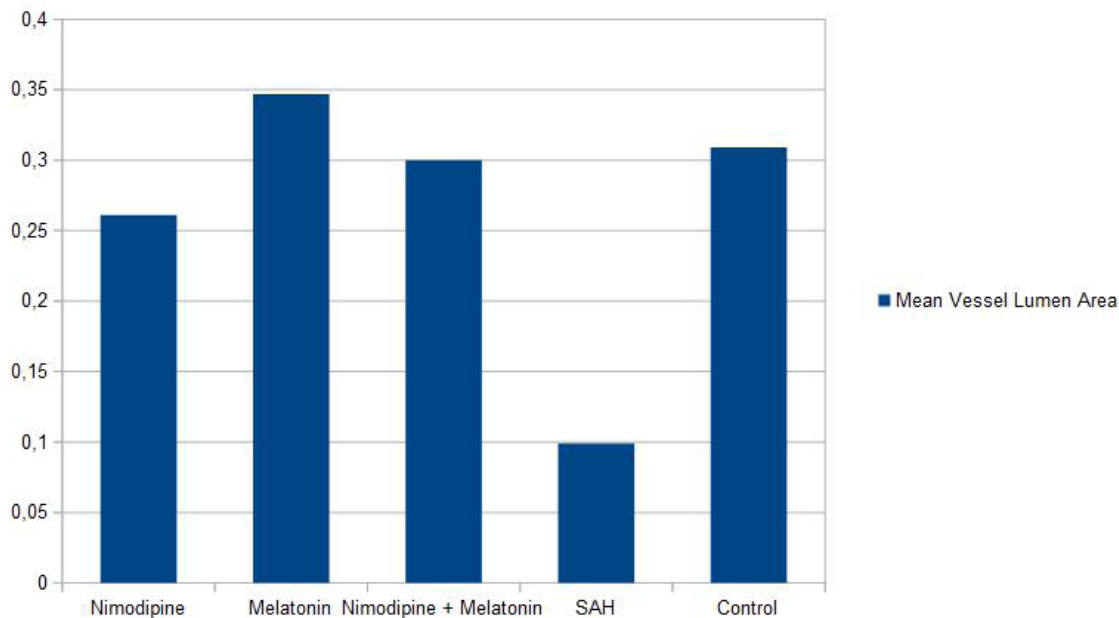


Figure 3. Comparison of mean vessel lumen area of the five groups (mm)

DISCUSSION

CV begin on the 3rd and 4th days and reaching peak level in the 1st week after SAH and which is severe cause of ischemic neurological deficits [12-15]. Pathophysiology of cerebral vasospasm is complex and multifactorial¹⁶. Although the specific mechanism of vasospasm has not been determined, neurogenic, metabolic and myogenic theories have been proposed [9,16].

The presence of blood and blood products in cerebrospinal fluid is an etiological factor. There is a correlation between the

development CV and increased superoxide anion levels in cerebrospinal fluid after SAH [17]. Normally, free radicals or their peroxidation products is neutralized by intrinsic antioxidants such as superoxide dismutase (SOD), catalase, glutathione peroxidase and peroxidase [18,19]. Microscopic findings seen in the vessel under the influence of oxidative stress are characterized by increase in vessel wall thickness, luminal narrowing, thickening of internal elastic lamina, deterioration of endothelial cell structure

and continuity, vacuoles in smooth muscles, migration of proliferated myointimal cell to the intima, perivascular axonal loss [20,21]. Endothelin antagonists, nitric oxide, glutamate antagonists, leukocyte inhibitors, protein kinase inhibitors and many other agents were used for treatment of experimental vasospasm [2,22,23]. In this study, we investigated nimodipine currently used for VS treatment and melatonin with known antioxidant efficiency concomitantly and comparing their efficiencies.

Nimodipine has been used in cv treatment after SAH for many years. There is some evidence that voltage-gated calcium channels are involved in vasospasm pathogenesis [4,24]. Although it was shown that use of calcium canal blocker after SAH reduced the incidence of cerebral infarction at a rate of 34%, no change was seen in the frequency of CV in the angiographies of the patients using prophylactic nimodipine or symptoms [25,26]. It is considered that nimodipine, decreases the risk of the secondary ischemia after SAH, it has a preventive role but there is no evidence that nimodipine decreases the mortality [27-30].

Melatonin is secreted by the pineal gland and helps to regulate biological rhythms and has many neuroendocrine functions and it is used to treat sleep disorders. In addition to these functions, melatonin is a very powerful antioxidant [5,8,31-35]. Antioxidant effect of melatonin occurs via several mechanisms. These mechanisms are; by scavenging free radicals, by preventing inactivation of endogenous antioxidant enzymes like catalase (CAT) or by stimulating the activity of the endogenous antioxidant enzymes like SOD [7,19,26,31,36]. Also metabolites of melatonin (N1-acetyl-N2-formyl-5-methoxykynuramine and N1-acetyl-5-methoxykynuramine) have powerful antioxidant effects like melatonin [31,37,38]. There are many studies indicating that melatonin has neuroprotective effects, decreases experimental VS and has therapeutic effects in traumatic central nervous system injury [1,6,12,30,31,39-42].

According to our results, melatonin may reduce vasospasm development and CV related complications. In this study, histopathological and morphometric analysis of rat femoral arteries in experimentally induced vasospasm model supported that melatonin and nimodipine combination therapy may be useful in treating post hemorrhagic vasospasm. When we compared the therapeutic effects of nimodipine and melatonin, the therapeutic effect of melatonin was found to be significantly higher and melatonin and nimodipine were administered concomitantly, their therapeutic effects were increased.

Declaration of interest: The authors report no conflicts of interest.

Financial Disclosure: No financial support was received.

REFERENCES

- Karaoglan A, Akdemir O, Barut S, et al. The effects of resveratrol on vasospasm after experimental subarachnoidal hemorrhage in rats. *Surgical Neurology* 2008;70:337-43.
- Kemaloglu S, Ozkan U, Yilmaz F, et al. Preventive effects of intracisternal alphatocopherol on cerebral vasospasm in experimental subarachnoid haemorrhage. *Yonsei Med J* 2003;44:955-60.
- Loch Macdonald RL. Management of cerebral vasospasm. *Neurosurg Rev* 2006;29:179-93.
- Megyesi JF, Vollrath B, Cook DA, Findlay JM. In vivo animal models of cerebral vasospasm: a review. *Neurosurgery* 2000;46:448-60.
- Allegra M, Reiter RJ, Tan DX, Gentile C, Tesoriere L, Livrea MA. The chemistry of melatonin's interaction with reactive species. *J Pineal Res* 2003;34:1-10.
- Reiter RJ, Tan DK, Manchester LC. Antioxidative capacity of melatonin. In: Cadenas E, Packer L (eds) *Handbook of antioxidants*. Marcel Dekker, New York, pp 2002;565-613.
- Reiter Rj, Tan DX, Manchester LC, Qi W. Biochemical reactivity of melatonin with reactive oxygen and nitrogen species: a review of the evidence. *Cell Biochem Biophys* 2001;34:237-56.
- Tan DX, Reiter RJ, Manchester LC, et al. Chemical and physical properties and potential mechanisms: melatonin as a broadspectrum antioxidant and free radical scavenger. *Curr Top Med Chem* 2002;2:181-97.
- Okada T, Harada T, Bark DH, Mayberg MR. A rat femoral artery model for vasospasm. *Neurosurgery* 1990;27:349-56.
- Kanamaru K, Weir BK, Findlay JM, Grace M, Macdonald RL. A dosage study of the effect of the 21-aminosteroid U74006F on chronic cerebral vasospasm in a primate model. *Neurosurgery* 1990;27:29-38.
- McNeish AJ, Altayo FJ, Garland CJ. Evidence both L-type and non L-type voltage-dependent calcium channels contribute to cerebral artery vasospasm following loss of NO in the rat. *Vascular Pharmacology* 2010;53:151-59.
- Christopher G, Harrod MS, Bernard R. Prediction of cerebral vasospasm in patients presenting with aneurysmal subarachnoid hemorrhage: a review. *Neurosurgery* 2005;56:633-52.
- Kassell NF, Shaffrey M, Shaffrey C. Cerebral vasospasm following aneurysmal subarachnoid hemorrhage. In Apuzzo M, editor. *Brain Surgery* p. 1993;847-56.
- Liu S, Tang J, Ostrowski RP, et al. Oxidative stress after subarachnoid hemorrhage in gp91phox knockout mice. *Can J Neurol Sci* 2007;34:356-61.
- Silva SO, Rodriques MR, Carvalho SH, Catalani LH, Campa A, Ximenes VF. Oxidation of melatonin and its catabolites, N1-acetyl-N2-formyl-5-methoxykynuramine and N1-acetyl-5-methoxykynuramine, by activated leukocytes. *J Pineal Res* 2004;37:171-5.
- Samantaray S, Das A, Thakore NP, et al. Therapeutic potential of melatonin in traumatic central nervous system injury. *J Pineal Res* 2009;47:134-42.
- McGirt MJ, Parra A, Sheng H, et al. Attenuation of cerebral vasospasm after subarachnoid hemorrhage in mice overexpressing extracellular superoxide dismutase. *Stroke* 2002;33:2317-23.
- Esposito E and Cuzzocrea S. Anti-inflammatory activity of melatonin in central nervous system. *Current Neuropharmacology* 2010;8:228-42.
- Reiter RJ. Pineal melatonin cell biology of its synthesis and of its interactions. *Endocr Rev* 1991;12:151-80.
- Kaptanoglu E, Palaoglu S, Demirpence E, Akbiyik F, Solaroglu I, Kilinc A. Different responsiveness of central nervous system tissues to oxidative conditions and to the antioxidant effect of melatonin. *J. Pineal Res* 2003;34:32-5.
- Macdonald RL, Weir BK. Cerebral vasospasm and free radicals. *Free Radic Biol Med* 1994;16:633-43.
- Guney O, Erdi F, Esen H, Kiyici A, Kocaogullar Y. N-acetylcysteine prevents vasospasm after subarachnoid hemorrhage. *World Neurosurgery* 2009;73:42-9.

23. Naredi S, Lambert G, Eden E. Increased sympathetic nervous activity in patients with nontraumatic subarachnoid hemorrhage. *Stroke* 2000;31:901-6.
24. Mayberg MR, Okada T, Bark DH. The role of hemoglobin in arterial narrowing after subarachnoid hemorrhage. *J Neurosurg* 1990;72:634-40.
25. Radogna F, Nuccitelli S, Mengoni F, Ghibelli L. Neuroprotection by melatonin on astrocytoma cell death. *Ann NY Acad Sci* 2003;1171:509-13.
26. Triggle DJ. Calcium channel antagonists: clinical uses- past, present and future. *Biochem Pharmacol* 2007;74:1-9.
27. Antolin I, Rodriguez C, Sainz RM, et al. Neurohormone melatonin prevents cell damage: effect on gene expression for antioxidant enzymes. *FASEB J* 1999;10:882-90.
28. Genova ML, Pich MM, Biondi A, et al. Mitochondrial production of oxygen radical species and the role of Coenzyme Q as an antioxidant. *Exp Biol Med (Maywood)* 2003;228:506-13.
29. Rothoerl RD, Ringel F. Molecular mechanisms of cerebral vasospasm following aneurysmal SAH. *Neurol Res* 2007;29:636-42.
30. Skene DJ, Lockley SW, Arendt J. Use of melatonin in the treatment of phase shift and sleep disorders. *Adv Exp Med Biol* 1999;467:79-84.
31. Aladag MA, Turkoz Y, Sahna E, Parlakpınar H, Gul M. The attenuation of vasospasm by using a sod mimetic after experimental subarachnoidal haemorrhage in rats. *Acta Neurochir (Wien)* 2003;145:673-7.
32. Aladag MA, Turkoz Y, Parlakpınar H, Ozen H, Egri M, Unal SC. Melatonin ameliorates cerebral vasospasm after experimental subarachnoidal haemorrhage correcting imbalance on nitric oxide levels in rats. *Neurochem Res* 2009;34:1935-44.
33. Reiter RJ, Carneiro RC, Oh C-S. Melatonin in relation to cellular antioxidative defense mechanisms. *Horm Metab Res* 1997;29:363-72.
34. Reiter RJ, Tan D-X, Manchester LC, Tamura H. Melatonin defeats neurally-derived free radicals and reduces the associated neuromorphological and neurobehavioral damage. *J Physiol and Pharmacol* 2007;58:5-22.
35. Siesjö BK. Calcium and ischemic brain damage. *Eur Neurol* 1986;25:44-56.
36. Acuna-Castroviejo D, Martin M, Macias M, et al. Melatonin, mitochondria, and cellular bioenergetics. *J Pineal Res* 2001;30:65-70.
37. Perez-Reyes E. Molecular physiology of low-voltage-activated t-type calcium channels. *Physiol Rev* 2003;83:117-61.
38. Tan DX, Manchester LC, Reiter RJ, Qi WB, Karbownik M, Calvo JR. Significance of melatonin in antioxidative defense: reactions and products. *Biol Signals Recept* 2000;9:137-59.
39. Eskiocak S, Tutunculer F, Basaran UN, Taskiran A, Cakir E. The effect of melatonin on protein oxidation and nitric oxide in the brain tissue of hypoxic neonatal rats. *Brain&Development* 2007;29:19-24.
40. Reiter RJ. Melatonin lowering the high price of free radicals. *News Physiol Sci* 2000;15:246-50.
41. Samantaray S, Sribnick EA, Das A, et al. Melatonin attenuates calpain upregulation, axonal damage and neuronal death in spinal cord injury in rats. *J Pineal Res* 2008;44:348-57.
42. Samel A. Melatonin and jet-lag. *Eur J Med Res* 1999;4:385-8.