

A Case of Increased F-18 FDG Uptake in Uterine Cavity due to Diagnostic Curettage

UTERUSTA DIAGNOSTİK KÜRETAJA SEKONDER ARTMIŞ F-18 FDG TUTULUMU OLGUSU

Erdem SÜRÜCÜ, Sadet AYHAN, Gamze ÇAPA KAYA, Hatice DURAK

Dokuz Eylül University Faculty of Medicine, Department of Nuclear Medicine

SUMMARY

Endometrial cancer is one of the most common malignant tumors of the women, and if it can be detected in the earlier stages, the curability and the prognosis of the endometrial cancers can be better. A 52 year-old female patient, as part of ongoing research project in our clinic on endometrial carcinoma, was referred to our clinic with a suspicion of endometrial carcinoma with increased serum CA-125 measurement. Increased F-18 FDG uptake in uterine cavity that was secondary to the diagnostic curettage was demonstrated on F 18 FDG PET images. This uptake might be secondary to benign inflammatory changes or hemorrhage arising from diagnostic curettage that patient underwent ten days ago. According to our knowledge, this is the first case demonstrating increased F-18 FDG uptake secondary to diagnostic curettage.

Key words: F-18 FDG, PET, uterine curettage, inflammation

ÖZET

Endometrium kanseri kadınlarda en çok görülen malign tümörlerden birisidir. Erken teşhis edildiğinde tam tedavi şansı yüksektir ve prognozu çok iyi seyirlidir. Bölümümüzde endometrium kanseri ile ilgili olarak devam eden bir proje kapsamında, serum CA-125 yüksekliği ile endometrium kanseri şüphesi olan 53 yaşında kadın hasta bölümümüze refere edildi. PET görüntülerinde uterusda artmış F-18 FDG tutulumu izlenmiştir. Bu bulgunun hastanın öyküsünde 10 gün önce geçirilmiş diagnostik küretaja bağlı benign inflamatuvar değişiklikler veya hemoraji ile ilgili olduğu düşünülmüştür. Bu olgu sunumunda diagnostik küretaja sekonder olduğu düşünülen F-18 FDG tutulumu muhtemelen literatürde ilk kez gösterilmektedir.

Anahtar sözcükler: F-18 FDG, PET, uterus küretajı, enflamasyon

Erdem SÜRÜCÜ
Dokuz Eylül University
School of Medicine
Department of Nuclear Medicine
35340 Inciralti, IZMIR
e-mail: surucuerdem@hotmail.com
phone: +90 506 9763359
fax: 90 232 4124269

Endometrial cancer is one of the most common malignant tumors of the women and if it can be detected in the earlier stages, the curability and the prognosis of the endometrial cancer can be better (1).

Tumor cells generally use glucose for aerobic glycolysis for being alive. Normally, after the transportation of glucose into the cells, they are phosphorylated by hexo-

kinase for the glycolytic metabolism pathway. After the phosphorylation, glucose keeps going along the glycolytic pathway. However, Fluorodeoxyglucose (FDG) cannot continue the glycolytic pathway and it is trapped intracellularly. Fluorine-18 fluorodeoxyglucose positron-emission tomography (F-18 FDG PET) is an imaging technique that shows glucose metabolism of tumor cells with

the help of trapped F-18 FDG in the tumor cells.

F-18 FDG avidity was shown in gynecologic malignancies including endometrial carcinoma. Recently, F-18 FDG PET-CT was started to use in staging, evaluation of therapy response and the recurrence of the disease. PET was found as a sensitive tool for the evaluation of suspected recurrence in patients with ovarian cancer, more accurate with increasing CA-125 levels during follow-up (2–8).

DESCRIPTION OF THE CASE

A 52 year-old female patient was referred to our clinic due to vaginal bleeding with a suspicion of endometrial carcinoma and increased serum CA-125 levels. Sixty minutes after injection of 351.5 MBq (9.5 mCi) F-18 FDG, images were obtained using PET/CT (Gemini-TOF-Philips). The emission scan was obtained for 1.5 minutes per bed

position. We obtained transmission scans with low dose CT using 50 mA and 150 kvp.

In figure 1, mildly increased F-18 FDG uptake (SUVmax: 3.5, SUVmean: 3.2) in uterine cavity was demonstrated on transaxial, sagittal and coronal PET/CT fusion images (A), and transaxial, sagittal and coronal PET images (B) (arrows). There were no any other pathologic PET findings. The patient had a history of diagnostic curettage ten days before PET/CT imaging and the pathology result of diagnostic curettage was reported as a benign cytology. Increased F-18 FDG uptake in the uterus resulting from intrauterine device and physiologic accumulation of F-18 FDG during menstruation have been reported previously. So, this increased F-18 FDG uptake in uterine cavity might be secondary to benign inflammatory changes or hemorrhage (9,10).

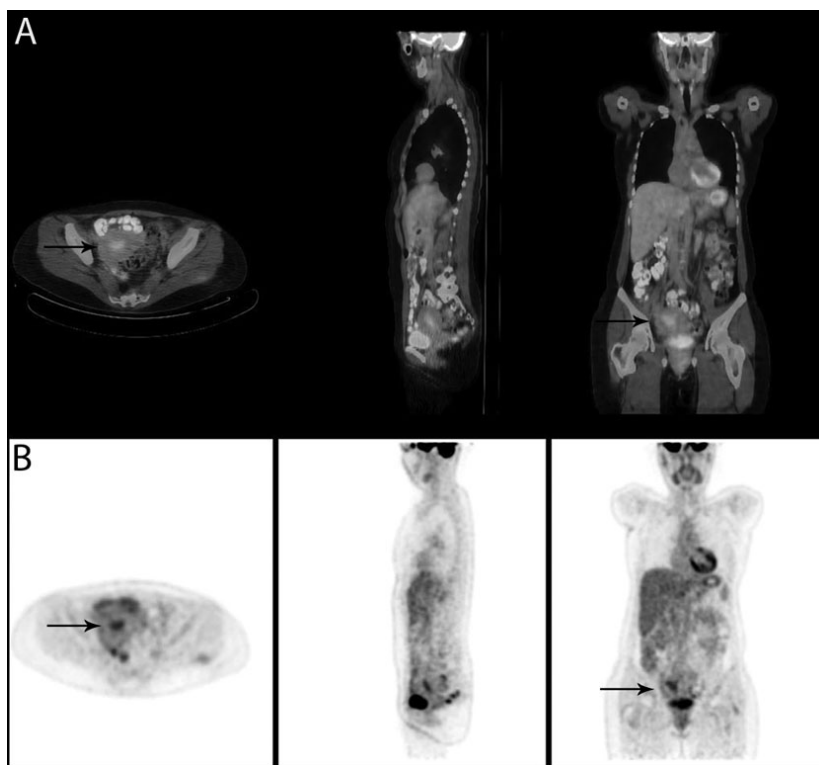


Figure. Transaxial, sagittal and coronal PET/CT fusion images (A), and transaxial, sagittal and coronal PET images (B) showing mildly increased F-18 FDG uptake in uterine cavity (SUVmax: 3.5, SUVmean: 3.2)(arrows). No any other pathological PET findings were present in the whole body scan.

DISCUSSION

Preoperative serum CA-125 may be a potential predictor for the extrauterine spread of clinically localized endometrial cancer (11-12). In our case, one of the reasons for the endometrial cancer suspicion and referral to our clinic was due to increased serum CA-125 level. However, the pathologic result of diagnostic curettage could not reveal the reason of increased serum CA-125 level. Because there is insufficient data in the literature, the role of FDG-PET in the diagnosis of endometrial cancer is not clear (13-16). Previous studies showed a mean SUV of 18.8 ± 9 in five patients with endometrial cancer and a range of 3.8-16.8 in nine patients with endometrial cancer (17,18).

According to our knowledge, this is the first case in the literature demonstrating increased F-18 FDG uptake secondary to diagnostic curettage. F-18 FDG uptake in various body systems has been extensively described in the literature related to surgery or inflammation (19-21). After the diagnostic curettage, uterine tissue has developed inflammatory response. As a result of this inflammation, blood flow increase and subsequently plasma and inflammatory cells (neutrophils, macrophages and lymphocytes) move into the injured tissues. The increased F-18 FDG uptake, which is due to increment of blood flow and glucose metabolism of the cells, is seen in these areas. Because diagnostic curettage has been frequently done among other surgical interventions in routine clinical practice, uptake in uterine cavity due to diagnostic curettage may have a clinical importance especially from clinician's points of view in patients having a suspicious endometrial carcinoma.

In conclusion, this finding may be reported as a kind of pitfall that it should be recognized during the evaluation of F-18 FDG PET/CT images, especially in a patient with a suspicious pelvic pathology. Therefore, the patients should be asked for any symptoms that can cause false positive F-18 FDG uptake like in this case.

REFERENCES

1. Irvin WP, Rice LW, Berkowitz RS. Advances in the management of endometrial adenocarcinoma. A review. *J Reprod Med* 2002; 47: 173-189.
2. Nakamoto Y, Eisbruch A, Ahtes ED, et al. Prognostic value of positron emission tomography using F-18-fluorodeoxyglucose in patients with cervical cancer undergoing radiotherapy. *Gynecol Oncol* 2002;84:289-295.
3. Rose PG, Adler LB, Rodriguez M, Faulhaber PF, Abdul-Karim FW, Miraldi F. Positron emission tomography for evaluating paraaortic lymph node metastases in locally advanced cervical cancer before surgical staging: a surgico-pathologic study. *J Clin Oncol* 1999;17:41-44.
4. Reinhardt MJ, Ehrhrt-Braun C, Vogelgesang D, et al. Metastatic lymph nodes in patients with cervical cancer: detection with MR imaging and FDG PET. *Radiology* 2001;218: 776-782.
5. Grisby PW, Siegel BA, Dehdashti F. Lymph node staging by positron emission tomography in patients with carcinoma of the cervix. *J Clin Oncol* 2001; 19: 2745-3749.
6. Miller TR, Grisby PW. Measurement of tumor volume by PET to evaluate prognosis in patients with advanced cervical cancer treated by radiation therapy. *Int J Oncol Biol Phys* 2002; 53: 353-359.
7. Zimny M, Siggelkow W, Schröder W, et al. 2-[Fluorine-18]-fluoro-2-deoxy-Dglucose positron emission tomography in the diagnosis of recurrent ovarian cancer. *Gynecol Oncol* 2001;83:310-315.
8. Liu Y. Benign ovarian and endometrial uptake on FDG PET-CT: patterns and pitfalls. *Ann Nucl Med* 2009; 23: 107-112.
9. Julian A, Payoux P, Rimaillho J, Paynot N, Esquerre J. Uterine Uptake of F-18 FDG on Positron Emission Tomography Induced by an Intrauterine Device: Unusual Pitfall. *Clin Nucl Med* 2007; 32:128-129.
10. Chander S, Meltzer CC, and McCook BM. Physiologic uterine uptake of FDG during menstruation demonstrated with serial combined positron emission tomography and computed tomography. *Clin Nucl Med* 2002; 27:22-24.
11. Duk JM, Aalders JG, Fleuren GJ, de Bruijn HW. CA 125 a useful marker in endometrial carcinoma. *Am J Obstet Gynecol* 1986; 155:1097-1102.
12. Dotters DJ. Preoperative CA 125 in endometrial cancer: is it useful? *Am J Obstet Gynecol* 2000; 182:1328-1334.
13. Torizuka T, Kanno T, Futatsubashi M, et al. Imaging of

- gynecologic tumors: comparison of 11C-choline PET with 18F-FDG PET. *J Nucl Med* 2003; 44:1051–1056.
14. Belhocine T, de Barse C, Hustinx R, et al. Usefulness of (18)F-FDG PET in the posttherapy surveillance of endometrial carcinoma. *Eur J Nucl Med Mol Imaging* 2002; 29: 1132–1139.
 15. Horowitz NS, Dehdashti F, Herzog TJ, et al. Prospective evaluation of FDG-PET for detecting pelvic and para-aortic lymph node metastasis in uterine corpus cancer. *Gynecol Oncol* 2004; 101:164–171.
 16. Chao A, Chang YC, Hsueh S, et al. F-18 fluorodeoxyglucose positron emission tomography in the management of endometrial cancer. *Eur J Nucl Med* 2006; 33: 36–44.
 17. Belhocine T, de Barse C, Hustinx R, et al. Usefulness of (18) F-FDG PET in the posttherapy surveillance of endometrial carcinoma. *Eur J Nucl Med Mol Imaging* 2002; 29:1132–1139.
 18. Saga T, Higashi T, Ishimori T, et al. Clinical value of FDG-PET in the follow up of postoperative patients with endometrial cancer. *Ann Nucl Med* 2003; 17:197-203.
 19. Imperiale A, Federici L, Lefebvre N, et al. F-18 FDG PET/CT as a valuable imaging tool for assessing treatment efficacy in inflammatory and infectious diseases. *Clin Nucl Med* 2010; 35: 86-90.
 20. Kao PF, Chou YH, Lai CW. Diffuse FDG uptake in acute prostatitis. *Clin Nucl Med* 2008; 33:308-310.
 21. Koff SG, Sterbis JR, Davison JM, Montilla-Soler JL. A unique presentation of appendicitis: F-18 FDG PET/CT. *Clin Nucl Med* 2006; 31:704-706.